UNIVERSITY OF
BRITISH COLUMBIA
OCT 31 1947
THE LIBRARY

The . . . BULLETIN of the . . . VANCOUVER MEDICAL ASSOCIATION

With Which Is Incorporated
Transactions of the

VICTORIA MEDICAL SOCIETY
the
VANCOUVER GENERAL HOSPITAL
and
ST. PAUL'S HOSPITAL

In This Issue:

Page

REFUGEE PHYSICIANS—By A. D. Kelly, M.D. 328

SYMPOSIUM—By A. J. Elliot, M.D.

Treatment of Ocular Injuries in General Practice 333

Opthalmic Indications of Systemic Disease 336

Ocular Finding in Important Neurological Conditions 340

The Differential Diagnosis and Treatment of an Acutely Red Eye 344

LUMBAR AND SACRAL INTERVERTEBRAL DISCS —By J. Gordon McPhee, M.D. 348

NEWS AND NOTES 356

VOL. XXIII. NO. 12 — SEPTEMBER, 1947

THIS PRESCRIPTION CAN NOW BE FILLED !

Theobarb

E.B.S.

Indicated in:

Cardiac dropsy, hypertensive heart disease, agina pectoris, cardiac pain, and following coronary thrombosis.

C.T. No. 691 THEOBARB CONTAINS:

Theobromine .....5 grs.
Neurobarb .....½ gr.
Sod. Bicarb.....5 grs.

Packaged in bottles of 100, 500 and 1,000

NOTE: At present Theobarb mild is not available.

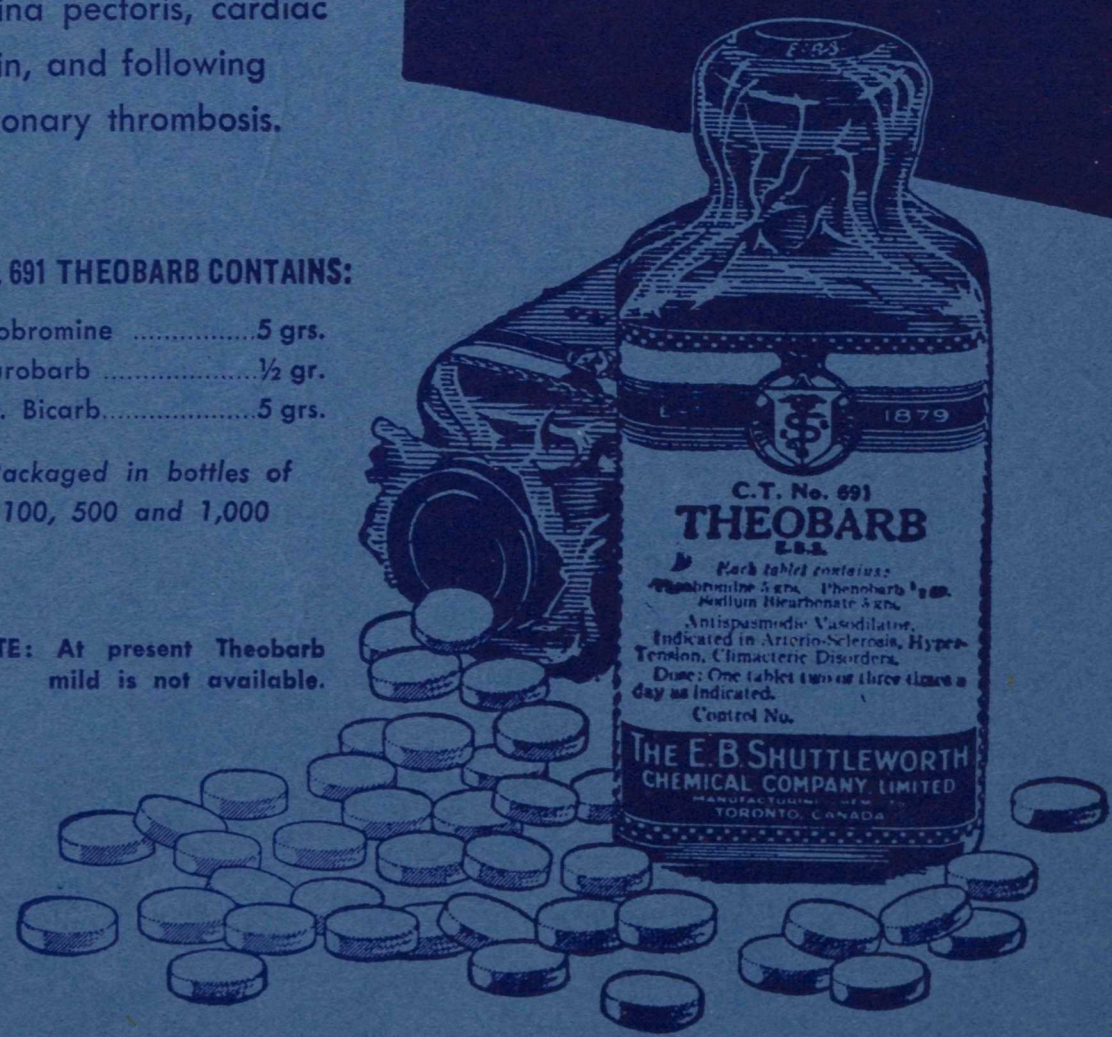

THE E.B. SHUTTLEWORTH CHEMICAL CO., LTD. TORONTO, CANADA

THE VANCOUVER MEDICAL ASSOCIATION

BULLETIN

Published Monthly under the Auspices of the Vancouver Medical Association in the interests of the Medical Profession.

Offices: 203 Medical-Dental Building, Georgia Street, Vancouver, B.C.

EDITORIAL BOARD:

DR. J. H. MACDERMOT

DR. G. A. DAVIDSON DR. D. E. H. CLEVELAND

All communications to be addressed to the Editor at the above address.

Vol. XXIII SEPTEMBER, 1947 No. 12

OFFICERS, 1947-48

DR. G. A. DAVIDSON, *President*

DR. GORDON C. JOHNSTON, *Vice-President*

DR. H. A. DESBRISAY, *Past President*

DR. GORDON BURKE, *Hon. Treasurer*

DR. W. J. DORRANCE, *Hon. Secretary*

Additional Members of Exceutive: DR. ROY HUGGARD, DR. HENRY SCOTT

TRUSTEES

DR. A. M. AGNEW DR. G. H. CLEMENT DR. A. C. FROST

Auditors: MESSRS. PLOMMER, WHITING & CO.

SECTIONS

Clinical Section

DR. REG. WILSON.....Chairman DR. E. B. TOWBRIDGE.....Secretary

Eye, Ear, Nose and Throat Section

DR. GORDON LARGE.....Chairman DR. G. H. FRANCIS.....Secretary

Paediatric Section

DR. J. H. B. GRANT.....Chairman DR. E. S. JAMES.....Secretary

Orthopaedic and Traumatic Surgery Section

DR. J. R. NADEN.....Chairman DR. CLARENCE RYAN.....Secretary

Neurology and Psychiatry

DR. J. C. THOMAS.....Chairman DR. A. E. DAVIDSON.....Secretary

STANDING COMMITTEES

Library:

DR. J. E. WALKER, Chairman; DR. W. J. DORRANCE, DR. D. E. H. CLEVELAND, DR. F. S HOBBS, DR. R .P. KINMAN, DR. S. E. C. TURVEY.

Publications:

DR. J. H. MACDERMOT—Chairman; DR. D. E. H. CLEVELAND, DR. H. A. DESBRISAY, DR. J. H. B. GRANT, DR. D. A. STEELE.

V. O. N. Advisory Board:

DR. ISABEL DAY, DR. H. H. CAPLE, DR. E. J. CURTIS.

Summer School:

DR. L. H. LEESON, Chairman; DR. E. A. CAMPBELL, DR. J. A. GANSHORN, DR. D. S. MUNRO, DR. D. A. STEELE, DR. L. G. WOOD.

Credentials:

DR. H. A. DESBRISAY, DR. H. H. PITTS, DR. FRANK TURNBULL.

Representative to B. C. Medical Association: DR. H. A. DESBRISAY.

Sickness and Benevolent Fund: THE PRESIDFNT—THE TRUSTEES.



The failure of standard hospital diets...

to supply adequate nutrition is becoming better recognized daily by both staff members and hospital personnel—

because . . . "infections and injuries (and the latter include major surgical operations) produce rapid wastage of protein tissues and of stores of vitamins and minerals."[1]

because . . . standard hospital diets do *not* provide adequate nutrition, particularly during the early stages of recovery from disease or injury.

because . . even a full diet meeting all nutritional standards cannot always be eaten.

"Recently . . . nutrition has been found so important in the recovery of patients with various 'surgical' diseases that the surgeon himself has been forced to pay more attention to the diets and dietary supplements, such as vitamins, that are given his patients."[1]

1. Editorial: J. A. M. A. 134:292 (May 17) 1947.

Basic Formula Squibb Vitamin Tablets

To help restore tissue levels promptly and to replace the "rapid wastage" of vitamins in the sick, Squibb Basic Formula Vitamin Tablets supply truly therapeutic doses of the four critical water-soluble vitamins.

Each tablet contains:

Thiamine HCl	10 mg.
Riboflavin	5 mg.
Niacinamide	150 mg.
Ascorbic Acid	150 mg.

Bottles of 30, 100 and 250.

SQUIBB Manufacturing Chemists To The Medical Profession Since 1858.

For Literature write

E. R. SQUIBB & SONS OF CANADA LIMITED

36-48 CALEDONIA ROAD • TORONTO

11-47A

VANCOUVER MEDICAL ASSOCIATION

Founded 1898; Incorporated 1906.

* * *

PROGRAMME FOR THE FIFTIETH ANNUAL SESSION

October 7 GENERAL MEETING—"The Treatment of Peptic Ulcer."
Dr. A. H. Gordon, Montreal.

October 21 CLINICAL MEETING—Vancouver General Hospital.

November 4 GENERAL MEETING—"Sympocium on Peripheral Vascular Disease."
Dr. Rocke Robertson and associates.

November 18 CLINICAL MEETING—St. Paul's Hospital.

December 2 GENERAL MEETING—"Symposium on Pre-frontal Leucotomy."
Dr. Frank Turnbull
Dr. Allan Davidson
Dr. R. Whitman.

December 16 CLINICAL MEETING—Shaughnessy Hospital.

Ergoapiol-(Smith)

Breaks the vicious circle of perverted menstrual function in cases of amenorrhea, tardy periods (non-physiological) and dysmenorrhea. Affords remarkable symptomatic relief by stimulating the innervation of the uterus and stabilizing the tone of its musculature. Controls the utero-ovarian circulation and thereby encourages a normal menstrual cycle.

MARTIN H. SMITH COMPANY
150 LAFAYETTE STREET, NEW YORK, N. Y.



Dosage: 1 to 2 capsules 3 or 4 times daily. Supplied in packages of 20.

Ethical protective mark MHS embossed on inside of each capsule, *visible only* when capsule is cut in half at seam.

Full formula and descriptive literature on request

Wyeth

CONESTRON

FOR MENOPAUSAL SERENITY

TABLETS

NATURAL CONJUGATED ESTROGENS

(equine)

ORAL THERAPY WITH CONESTRON provides safe, dependable control of menopausal symptoms and restores the patient's sense of well-being.

ORAL THERAPY WITH CONESTRON is relatively free from undesirable side effects.

ORAL THERAPY WITH CONESTRON is most desirable from the standpoint of convenience and time economy.

CONESTRON TABLETS

May be prescribed in any quantity. Available at all pharmacies in two strengths.

.625 mg. TABLETS

Wyeth

Registered Trade Mark

1.25 mg. TABLETS

JOHN WYETH & BROTHER (CANADA) LIMITED • WALKERVILLE, ONTARIO

VANCOUVER HEALTH DEPARTMENT

STATISTICS—JULY, 1947

Total Population—Estimated	339,350
Chinese Population—Estimated	5,980
Hindu Population—Estimated	118

	Number	Rate Per 1000 Population
Total deaths	329	11.4
Chinese deaths	9	17.7
eaths, residents only	286	9.9

BIRTH REGISTRATIONS:

Male	502	
Female	490	
	992	36.3

INFANT MORTALITY:	July, 1947	July, 1946
Deaths under 1 year of age	23	26
Death rate per 1000 live births	23.2	31.6
Stillbirths (not included above)	11	11

CASES OF COMMUNICABLE DISEASE REPORTED IN THE CITY

	June, 1947		July, 1947		August, 1947	
Scarlet Fever	7	0	1	0	2	0
Diphtheria	0	0	3	0	0	0
Diphtheria Carrier	0	0	4	0	0	0
Chicken Pox	64	0	27	0	8	0
Measles	29	0	9	0	2	0
Rubella	2	0	2	0	0	0
Mumps	80	0	18	0	5	0
Whooping Cough	70	0	13	0	0	0
Typhoid Fever	0	0	0	0	0	0
Typhoid Fever Carrier	0	0	0	0	0	0
Undulant Fever	1	0	0	0	0	0
Poliomyelitis	13	0	40	0	45	1
Tuberculosis	52	17	49	19	62	0
Erysipelas	0	0	0	0	2	0
Meningococcus (Meingitis)	1	0	0	0	0	0
Infectious Jaudice	0	0	0	0	1	0
Salmonellosis	18	0	3	0	3	0
Salmonellosis (Carrier)	1	0	0	0	0	0
Dysentery	0	0	0	0	2	0
Dysentery (Carriers)	0	0	0	0	0	0
Tetanus	0	0	0	0	0	0
Syphilis	78	1	74	3	95	0
Gonorrhœa	218	0	251	0	196	0
Cancer (Reportable)						
Resident	82	0	42	0	92	0
Non-Resident	28	0	10	0	30	0

CRYSTALLINE PENICILLIN G

It has been widely established that Penicilln *G* is a highly effective therapeutic agent. The crystalline form of Penicillin *G* prepared and supplied by the Connaught Medical Research Laboratories is highly purified. Because of this high degree of purity, pain on injection is seldom reported and local reactions are reduced to a minimum. Crystalline Penicillin *G* is heat-stable, and in the dried form can be safely stored at room temperature for at least three years.

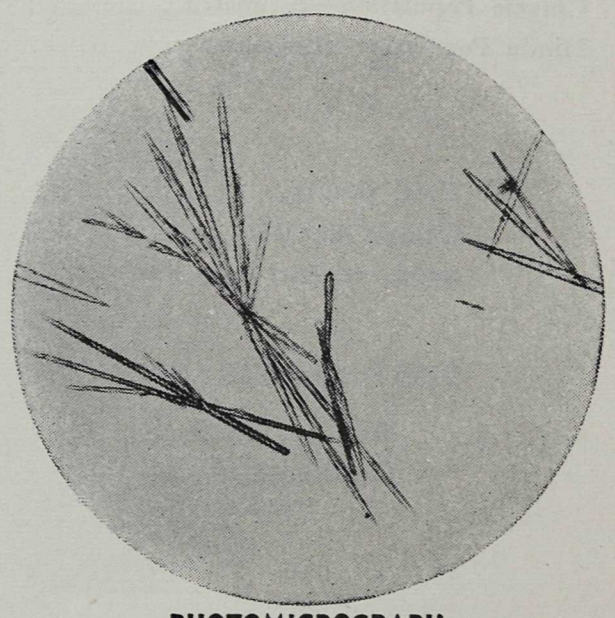

PHOTOMICROGRAPH
OF PENICILLIN CRYSTALS

HOW SUPPLIED

CRYSTALLINE PENICILLIN *G* IN VIALS

Highly purified Crystalline Potassium Penicillin *G* is supplied by the Laboratories in sealed rubber-stoppered vials of 100,000, 200,000, 300,000 and 500,000 International Units. No refrigeration is required.

CRYSTALLINE PENICILLIN *G* IN OIL AND WAX (ROMANSKY FORMULA)

A heat-stable and conveniently administered form of Crystalline Sodium Penicillin *G* in peanut oil and beeswax is available in 1-cc. cartridges for use with B-D* disposable plastic syringes, or as replacements with B-D* metal cartridge syringes. Each 1-cc. cartridge contains 300,000 International Units of Crystalline Sodium Penicillin *G*.

* T.M. Reg. Becton, Dickinson & Co.

CRYSTALLINE PENICILLIN *G* IN TABLETS FOR ORAL USE

Buffered tablets of Crystalline Sodium Penicillin *G* are distributed by the Laboratories in tubes of 12. Two strengths are supplied, 50,000 and 100,000 International Units per tablet. No refrigeration is required.

CONNAUGHT MEDICAL RESEARCH LABORATORIES
University of Toronto Toronto 4, Canada

DEPOT FOR BRITISH COLUMBIA

MACDONALD'S PRESCRIPTIONS LIMITED

MEDICAL-DENTAL BUILDING, VANCOUVER, B.C.

The Editor's Page

We are reproducing in this copy an article written by Dr. A. D. Kelly, assistant to Dr. T. C. Routley, General Secretary of the Canadian Medical Association, which we consider is well worth a careful reading by every medical man.

Dr. Kelly has dealt very objectively with his subject, "Refugee Physicians"—a difficult thing to do, since so often we are prone, in considering whether or not these men should be allowed to enter Canada, to be influenced by feelings of pity, or even by fallacious reasoning as regards the need of more physicians in Canada. It is not easy to clear one's thinking of these factors, and to avoid the short view—but it is very necessary—and Dr. Kelly's plain statements of fact help us greatly in taking a longer and more objective view of the subject.

Dr. Kelly has drawn attention also to the fact that there is a section of the population which would like to see a more unrestricted admission of doctors, from more or less interested motives. One is reminded in this regard of the very thinly-veiled threat of the Saskatchewan government, recently made, to the effect that if doctors are not as amenable to its projects of socialised medicine as the government feels they should be, it may be necessary to let down the bars, and import physicians from the distressed areas of Europe and elsewhere. In this connection, we would draw special attention to the point made by Dr. Kelly, that Canada has international obligations which would make her hesitate to allow the immigration of refugee physicians to Canada, when they are so badly needed to improve and maintain health conditions in their own countries. The health standards of Canada are not going to be maintained at their highest level, if health conditions in other parts of the world are allowed to deteriorate continually. As Dr. Routley pointed out in his address in Vancouver some months ago—and Dr. Kelly summarises this part of his address in review—these war-torn countries are desperately in need of medical men. The few they have do not begin to meet this need—and it would be almost desertion and treachery on the part of physicians, say in Czechoslovakia, to leave the country to which they owe a duty which must be discharged in their own country, nor can Canada countenance such action.

As regards the need for more physicians in Canada, Dr. Kelly's figures seem to show that we are fairly well supplied at present, under conditions of medical practice, and he argues that we shall be able to produce enough to maintain this level. There will be those who will not fully agree with this—there is a crying need in areas of Canada for more and better medical service; more general practitioners; more men trained in public-health. If, too, health insurance becomes an actuality, we shall need many more doctors. But this is to some extent a matter of redistribution, and it can be met, too, by the establishment of medical schools in some of our Universities, and the expansion of those that exist. Certainly, it cannot be met by robbing Peter to pay Paul—nor, as Dr. Kelly says, can we do it by importing inadequately trained men. A gap of seven or eight years in medical training, in hospital and university teaching, with the enormous loss of medical schools and medical centres of education, must infallibly have led to a serious deterioration of medical standards of knowledge and practice.

This is not to say that we must not allow the entrance to Canada, under properly supervised control, by our recognised standards of examination, of men from foreign lands; as Dr. Kelly says, "Medical immigration to Canada is a continuous process." This has always been allowed, and should be. His conclusion is pithy and deserves quotation. "It is my opinion that the needs of this country for doctors will best be served by depending on the product of our own medical schools, augmened by selective immigration of this type."

REFUGEE PHYSICIANS

By DR. A D. KELLY
Assistant Secretary of the Canadian Medical Association.

The question of the admission to Canada of refugee physicians has recently become a matter of some public interest. Various opinions on this matter have been attributed to the Canadian Medical Association, and it appears opportune to examine the problem and to state my own views based on the appraisal of the opinion of Canadian doctors.

In any discussion of this sort, it is important that we be clear in our terms, and I would define a refugee doctor as a physician qualified in his own country who through the dislocation of war or political or racial persecution cannot, or does not desire to return to his native land to practice medicine. There are undoubtedly among the Displaced Persons of Europe a number of physicians, mainly from the nations of Central and Eastern Europe, who qualify under this definition. You will note that I do not include in the classification of refugee physicians those doctors from the United Kingdom, the British Commonwealth, the United States or those democracies in Western Europe which opposed Nazi and Fascist aggression in the recent war.

Those Canadians who favour the unrestricted immigration of refugee physicians justify their stand on two main premises: a humanitarian duty, and a means of satisfying a need for more physicians which is said to exist in Canada. In most presentations of the subject which I have read or listened to, these motives are inseparably mixed. This is quite natural, as in most of our dealings either as individuals, as organizations, or as nations, our benevolent impulses are conditioned by a measure of self-interest.

It will scarcely be denied that the medical profession by tradition and by its everyday work is sufficiently humanitarian in its outlook to comprehend the plight of Displaced Persons generally, and of our professional colleagues among them in particular. Moreover, our viewpoint has of late years been enlarged to encompass world conditions as they exist and to seek to assist in their amelioration. The recent service of several thousand Canadian doctors in the Armed Forces has given them the opportunity to see at first hand the medical services of many nations and to compare them with similar activities in Canada. More recently, Canada and the Canadian Medical Association has taken a leading part in the formation of two complementary bodies, the World Health Organization and the World Medical Association, which have as their primary objectives "the attainment by all peoples of the highest possible level of health." My senior colleague, Dr. T. C. Routley, General Secretary of the Canadian Medical Association, has for over a year been actively engaged in the organization of these two great international health groups, and this work has given him a unique opportunity to learn much about the world's medical needs. He has been convinced that the shortage of doctors in large populous areas of the world is desperate, and that the need for additional medical practitioners is imperative.

Here are some facts reported by Dr. Routley after consultation with the medical leaders of the countries concerned. Czechoslovakia, which had 12,000 doctors in 1939, lost irretrievably 60% of them during the years of the German occupation; China, with a population of 400,000,000, has fewer than 12,000 doctors, only one-third of whom are adequately trained; Liberia, with a population of 2,600,000, has one doctor. Ethiopia, with a population of 12,000,000, found itself after the war without a single doctor or trained nurse in the country. We have recently learned that 16 physicians trained in European schools have settled in Ethiopia to practice their profession.

It is possible to point to many other countries where the need is only slightly less, but by comparison, the position in Canada is most favourable. As a nation, we have one qualified physician for every thousand of our population.

It must therefore be a very narrow humanitarian viewpoint which will suggest that refugee physicians should be brought to Canada when their services are so urgently required elsewhere.

The Parliament of Canada was the first legislative body in the world to ratify the Charter of the World Health Organization. In so doing, our country was pledged to support the instrument of the United Nations which is attempting to improve the health of all the peoples. The health conditions in Poland and China and Greece and Egypt are important to Canadians as never before, since an aircraft carrying people from many nations may arrive at Edmonton or Montreal or Vancouver within less than twenty-four hours from its departure. Human beings are the commonest carriers of human diseases, and elaborate precautions must be set up to prevent the introduction of maladies from other lands. It is therefore elementary public health practice to protect the Canadian people by raising the standards of health throughout the world.

It is incomprehensible to me that the Government of Canada will so disregard its international obligations that refugee physicians will be admitted to Canada, when all indications point to the wisdom of settling them in the needy areas of the globe.

The other half of the question is Canada's need of doctors. I have stated that Canada is one of the favoured nations in this respect, and I propose to present some figures which bear upon this assertion.

Just over a year ago, there was published by the Department of National Health and Welfare a most interesting booklet entitled, "Survey of Physicians in Canada, July, 1946." The information concerning the present supply of physicians and their location was an up-to-date continuation of the registry established and maintained by the Canadian Medical Procurement and Assignment Board, and predictions of future supply and demand were obtained mainly from the Report of the National Health Survey, another war-time activity of the C.M.P.A.B. As of July 1, 1946, there were reported to be 11,901 active civilian physicians in Canada, serving a population estimated by the Dominion Bureau of Statistics in 1945 to be 12,102,000, giving a ratio of 1 physician to each 1,017 residents in Canada. At the time, there were 1,417 medical officers serving in the Armed Forces and, assuming that they have now resumed their civilian status, it is possible to amend these figures to fit present conditions in the Autumn of 1947 as follows:

Active civilian physicians, July, 1946	11,901	
Demobilized medical officers	1,417	
1947 graduates in medicine	531	
		13,849
From which must be deducted:		
Estimated number of M.O. with armed forces	130	
Deaths and retirements 1946-47 (estimated)	300	
		430
For an estimated total of civilian physicians at present		13,419 active

Presuming the population to have increased to 12,300,000, the estimated present physician-population ratio is 1 : 916.

Is this ratio adequate to insure a high standard of medical care to the people of Canada? It is not possible to give a categorical answer to the question, as no one to my knowledge has been bold enough to state the ideal or optimum ratio of physicians to population, and to support his assertion with adequate reasons. Just as it is impossible to specify the appropriate number of journalists or farmers or cabinet ministers, because the answer must be qualified by a multitude of circumstances and conditions, so we must not indulge in generalizations in respect to the adequacy or inadequacy of our medical personnel.

However, if we recognize the limitations of the physician-population ratio as a measuring stick for the adequacy of medical care, it is possible to gain some information on the position which Canada occupies in relation to other countries by comparing the respective ratios.

Figures quoted in the House of Commons in 1943 show the following countries with more favourable ratio: U.S.A. 1 - 796; Sweden 1 - 723; Union of South Africa 1 - 728. New Zealand and the United Kingdom with ratios of 1 - 923 and 1 - 937 are practically on even terms with Canada, while the remainder of the major powers of the western world show ratios which vary from 1,087 in the case of the Argentine to 1 - 1621 in the cost of U.S.S.R. (in Europe), and 1 - 1651 in the case of Eire. The only other member of the British Commonwealth of Nations which can be closely compared with Canada on the basis of large area and small population is Australia, where the physician-population ratio is 1 - 1,139, a much less favourable figure than Canada's 1 - 916.

It appears therefore that Canada as a whole is more adequately supplied with physicians than most countries and, speaking broadly, requires no major additions to meet its present needs.

However, the practice of medicine is not undertaken as a national effort but as a very personal relationship between an individual doctor and his patient. This implies a reasonable distribution of physicians in relation to the people in need of their services. An examination of the distribution of physicians by provinces, shows considerable disparity to exist. It is not possible as yet to indicate by provinces the effect of further demobilization or the annual output of Canadian medical schools, so the following figures are taken from the Survey of Physicians in Canada, July, 1946:

Province	Physicians	Population Per Physician
Prince Edward Island	74	1,243
Nova Scotia	492	1,262
New Brunswick	293	1,597
Quebec	3,334	1,068
Ontario	4,752	843
Manitoba	706	1,042
Saskatchewan	562	1,504
Alberta	676	1,222
British Columbia	1,012	938

Before any reasonable judgment of the adequacy or inadequacy of the supply and distribution of physicians in any specified area can be made, an intimate knowledge of local conditions is required. The needs of any area depend not only on population but on many attributes such as economic status, attitude toward medical care, density of population, topography, climatology, accessibility of transportation, the availability of facilities such as hospitals, and the location of special facilities for medical care.

It is quite evident from a more detailed study of the distribution of physicians in Canada that urban communities are more adequately supplied with physicians than are rural areas. The urbanization of the medical profession is not an isolated phenomenon, but runs parallel with the growth of cities and the shift in population which has been evident in Canada for over forty years. It must be remembered also that not all of the physicians in urban centres are engaged in the direct medical care of the persons within their respective communities. In the larger cities, many of the physicians are employed in medical schools and hospitals as teachers or post-graduate students, in research, industrial medicine, medical administration and other capacities not directly connected with practice. Furthermore, there are in urban areas a considerable number of specialists and consultants who serve a much wider area than the municipality in which they live. It was shown in the National Health Survey (1943) that "concentration of physicians in urban areas is in large measure more apparent than real insofar as community medical care by general practitioners is concerned."

Notwithstanding these observations, there are areas in Canada where sparse population, difficult communication and transportation and other factors, combine to make them unattractive to physicians, and where medical services are scanty or lacking. We recognize that this situation must be corrected and organized medicine is making every

effort through placement services to encourage the location of doctors where no medical service now exists.

Poor economic conditions in these medically marginal areas are by no means the only deterring factors to the settlement of physicians. Equally important are the lack of thise hospital, diagnostic and consultative services upon which the modern practice of medicine is built, as well as the absence of the amenities in the field of education and culture which the doctor desires for his family.

I would like to make it clear that the importation of refugee physicians will not correct this lack of medical manpower in certain rural communities. A limited experience in Canada, and a much more extensive experience in the United States, has shown that foreign graduates very rarely proceed to the areas of greatest need, but almost invariably settle in the large metropolitan centres. It is wishful thinking to assume that the adoption of a policy of wholesale immigration would do anything but accentuate the disparity which has been noted.

The future supply of physicians in Canada will in large measure depend on the output of Canadian medical schools. Nine Canadian Universities now teach the full medical course, and two additional schools will within the next few years be graduating students in Medicine. In all of these schools registration in medicine is the highest ever, and a very large proportion of the undergraduates are veterans of World War II.

For the period 1920-1939, the average annual number of graduates was 519;

For the period 1940-1945 (the war years), the average output was 630;

For the period 1946-1952 it is estimated that the graduates will number 627 annually.

In the next five years, 1947-51, it is anticipated that 3,277 new graduates in medicine will be produced. Past experience has shown that ten per cent of these will leave Canada to follow a career elsewhere, and an additional five per cent will be foreign-born students who return to the country of their origin. These factors will reduce the available doctors by 491. During the five-year period, death and retirement of physicians now active will account for a loss of 1,150 doctors. Deducting these latter two figures from the estimated output of the schools, we should have 1,586 more doctors in Canada in 1951 than we have today.

The Dominion Bureau of Statistics estimates that the population of Canada may be from 12,722,000 to 12,943,000 in 1951. Adding present medical manpower to the anticipated net gain, and taking the higher population forecast, the physician-population ratio in 1951 should be of the order of 1 - 868, the most favourable figure in Canada's history.

Future trends in the provision of medical services include the growth of prepayment plans on either a voluntary or a compulsory basis, and the wide extension of these plans would undoubtedly increase the demands for the services of physicians. To offset this possible future requirement, we have two additional medical schools now preparing to teach the full course and a third University which is seriously considering the establishment of a Faculty of Medicine.

In this discussion, I have attempted to present a medical viewpoint on the question of the advisability and the necessity of permitting unrestricted immigration of refugee physicians to Canada. The other important consideration, which would become operative only if these foreign medical graduates were actually in Canada, relates to their ability to meet the exacting tests of professional knowledge and skill which have been set up to protect the Canadian people from practitioners of inferior qualifications. The possession of a degree in medicine is not the final criterion for fitness to practice, and in every province in Canada there is established by an Act of the Legislature a licensing body usually called a College of Physicians and Surgeons whose duty it is to demand of applicants for registration proof of preliminary education, evidence of undergraduate training in medicine, equivalent to the course taught in Canadian schools, and usually evidence of having passed the examinations of the Medical Council of Canada. Additional requirements include evidence of good character and ethical behaviour, and in certain provinces the applicant for registration must either be a British subject or a Canadian

citizen. It is not in the public interest that any relaxation of the high standards of medical licensure should be permitted either in the case of foreign-trained physicians or for the graduates of our own schools.

Medical immigration to Canada is a continuous process. I answer every week at least four letters of enquiry from doctors in the United Kingdom desiring information on the possibilities of practice in Canada. They are given the facts on medical conditions in this country as we know them, as well as full information on licensing requirements. We do not paint a picture of urgent need or unparalleled opportunity, but they are told that there is always room for a well-qualified man who is prepared to enter rural practice. Many of these enquirers are already in Canada refreshing their knowledge by a hospital internship and learning the unfamiliar features of our administration of health and medical services, and qualifying themselves for the examinations of the Medical Council of Canada. It is my opinion that the needs of this country for doctors will best be served by depending on the product of our own medical schools, augmented by selective immigration of this type.

LIBRARY NOTES

HOURS:

Monday, Wednesday, Friday: 9.00 a.m. to 9.30 p.m.
Tuesday and Friday: 9.00 a.m. to 5.00 p.m.
Saturday: 9.00 a.m. to 1.00 p.m.

MESSENGER SERVICE:

The free messenger service for book loans to members in Vancouver whose offices are outside the Medical-Dental Building is now in operation.

The attention of members is directed to the following important points:

(1) Requests for loans to be delivered on the same day must be made by 10.30 *a.m.* of that day.

(2) All books being returned by messenger *must have some type of covering*—either the envelopes in which they were delivered, or some other protective wrapping.

RECENT ACCESSIONS TO LIBRARY:

Surgical Clinic of North America, Symposum on Gynæcology, Mayo Clinic Number, August, 1947.

Diseases of Children, Vol. I, 4th ed. 1947, edited by Dr. Donald Paterson and Alan Moncrieff.

Diseases of the Breast, 1943, by Charles F. Geschickter. (Gift of Dr. G. E. Seldon.)

ANNOUNCEMENT

ANNUAL DINNER — VANCOUVER MEDICAL ASSOCIATION

The Annual Dinner of the Vancouver Medical Association will be held in the Banquet Room of the Hotel Vancouver on the evening of Tuesday, November 18th, 1947, at 6.30 o'clock.

Further particulars will be published in the next issue of the BULLETIN.

OPIUM AND NARCOTIC DRUG ACT

Effective November 7th next, Amidone, which is also known as Methadon, and by various other trade names, is being added to the Schedule of the Opium and Narcotic Drug Act, and will be administered in precisely the same manner as morphine, heroin or any other narcotic drug. Amidone is a synthetic chemical, which has not an opium base, but it definitely possesses addiction-forming and addiction-sustaining liabilities. You may be interested to know that at the present time, this drug comes under narcotic control in the United States.

TREATMENT OF OCULAR INJURIES IN GENERAL PRACTICE*

By A. J. ELLIOT, M.D.
Toronto

From the Department of Ophthalmology, University of Toronto, and the Toronto General Hospital.

Although many serious injuries of the eye require hospitalization and the surgical care of an ophthalmic specialist, there are a large number of ocular injuries which the general practitioner may well care for and to which he can render the appropriate treatment. It is my purpose to discuss the treatment of ocular injuries in general practice.

Foreign Bodies—Small sharp objects often become firmly fixed upon the conjunctiva or cornea; very frequently the small foreign body becomes lodged underneath the upper lid and may be retained for a long time, producing much irritation and some discharge; it may be overlooked unless the lid is everted. The upper lid may be everted by placing a small probe or a thin pencil horizontally along the skin at the level of the upper border of the tarsus. With the patient looking down towards his feet the lid is everted by seizing the lashes and drawing the lid away from the globe. The foreign body is usually easily located and removed with a small spud or cotton tooth pick. If there is considerable irritation present, warm, wet compresses are advised t.i.d. followed by the instillation of a soothing antiseptic eye ointment, such as Boracic Acid 10%, into the fornix.

Particles of steel and emery frequently become imbedded in the cornea, penetrating into the epithelium or corneal stroma. A record of the visual acuity in both eyes should be obtained before the foreign body is removed and at the termination of the treatment. The cornea should be anaesthetized with a suitable local anaesthetic, e.g. Pontocaine 1% drops or Butyn 2% drops and the cornea thoroughly examined under strong artificial illumination. It is sometimes not easy to discover a foreign body upon the cornea. A small lens is very useful in focussing the beam of light on to the cornea. Having located the foreign body, it should be removed with a sterilized spud. Frequently a brownish rust-ring remains at the site of the imbedded foreign body and it is often difficult to remove this in its entirety at the first visit; in these cases it is better to remove the rust-ring the following day when it has become loosened and in some cases removal of the rust-ring should be carried out piece-meal over a 2 or 3 day period. If the cornea or conjunctiva does not appear to be infected an antiseptic ointment, e.g. Metaphen or Boracic Acid should be instilled into the lower fornix and a snug-fitting patch applied to the eye. The patient should always be examined the following day and the cornea stained with aqueous fluorescein 1% to determine whether the epithelium has completely regenerated. Atropine should not be used routinely, as it is generally unnecessary, and also produces prolonged blurring of vision, sometimes for days after the cornea is completely healed. However, if the eye is irritable and remains painful, atropine may well be instilled with resulting amelioration of pain and marked improvement in the patient's symptoms. The eye should be patched continually until the cornea is completely healed. Cocaine drops are not recommended as a local anaesthetic as the corneal epithelium rapidly becomes desquamated with its use. The continued use of cocaine as a local anaesthetic without a dressing predisposes the eye to infection—the one complication which is feared in corneal foreign bodies.

---

*Read before the Vancouver Medical Association Summer School, Vancouver, British Columbia, June 2 - June 6, 1947.

The immediate removal of multiple foreign bodies in the cornea is sometimes unwise, as the manipulation necessary for their removal may do more harm than good. A protective dressing and removal of the more prominent ones at the first visit is often sufficient, the remainder being removed at subsequent visits or falling out of their own accord.

The frequency of imbedded foreign bodies in the cornea and the loss to industry involved in these cases, emphasizing the necessity of the physician advising the use of protective goggles and other safety measures. Industrial workers should be educated to go directly to the First Aid station for proper care, and warned against allowing their fellow workers to attempt the removal of the foreign body.

Large particles of steel and, less commonly, stone, glass, etc., may perforate the globe. The foreign body may be so small and the accident happen so quickly that the patient may not experience much pain. There is immediate loss of vision and if infection occurs, successful removal of the foreign body is not easily effected. These cases should be referred for specialized opthelmic care.

Intraocular foreign bodies may be overlooked for several days. When a history of hitting metal on metal is given, such as hammering, a careful examination of the eyes with x-ray studies of the orbit should be made and if there is a suspicion of an intraocular foreign body the case should be referred for further care to an eye physician.

Burns and Chemical Injuries.—Burns by hot water, steam, hot ashes, molten metal, caustics, such as lime, strong acids or alkalis endanger the eyes in two ways, viz. by injuring the cornea and producing adhesions between the lids and the eyeball. The immediate care of severe burns is that of protecting the globe bv frequent instillation of non-irritating oils and ointments. If the burn is caused by caustic, the excess of the material must be removed by copious irrigation with water. If the burn is severe, the patient must be admitted to hospital and treatment instituted to prevent adhesions between the eyeball and lids by using a glass rod well coated with boracic acid ointment. Usually the cornea is involved and in those cases atropine ointment should be instilled daily. In the most severe cases daily treatment with vaseline or boracic acid ointment will usually allow the tissues to heal satisfactorily. An eye patch should be worn until the denuded surface of the conjunctiva and cornea are well healed. The prognosis should be guarded, however, and care taken to impress the patient with the gravity of the injury and the necessity for continued supervision.

Exposure to infra-red and ultra-violet light rays frequently results in an acutely red eye. In such cases the history is important, as the patient must be within a distance of 8 feet from the offending source of light and must be exposed for approximately 30 seconds. The eye condition should be manifested from within 8 to 12 hours. An anaesthetic ointment, such as epinephrin 1-4,000 and butyn 2%, followed by a patch on the eye usually relieves the congestion in 24 to 36 hours.

Ocular Contusions.—Injuries by blunt instruments vary in severity from a simple corneal abrasion to rupture of the globe. The cornea may suffer a simple abrasion from a scratch by a child's finger, etc. The abrasion may be recognized by the green stain on the cornea following the instillation of aqueous fluorescein 1%. There is usually considerable pain, tearing and sensitivity of the eye to light. In these cases boracic aoid ointment and a snug-fitting eye patch, changed daily, usually will suffice and the cornea heals in a few days.

If the contusion is more severe, there may be a small haemorrhage in the anterior chamber lying in front of the iris. The pupil is often large and reacts sluggishly to light stimulation. The iris may be torn away from its ciliary attachment for a variable distance. Treatment consists of rest in bed and the application of cold compresses several tmes a day until the haemorrhage is absorbed. Atropine should never be used as an acute secondary glaucoma may result because of blockage of the filtration angle in

the anterior chamber by red blood cells. All cases in which a haemorrhage occurs within the eye should be given a guarded prognosis, and in some cases it is wise to admit the patient to hospital.

Case Report: J. C., a male, aged 12, was hit in the right eye by a small rubber ball following which there was loss of vision. On examination 12 hours later there was a frank, small haemorrhage in the anterior chamber; the vision was 20/20-2 and the pupil reacted sluggishly to light. The tension was normal. He was admitted to hospital, kept quietly in bed, and the hæmorrhage in the eye rapidly cleared up. Two days later, in the middle of the night, he suffered a severe pain in the eye with marked loss of vision. On ophthalmoscopic examination the fundus details were not visible; the eyeball was soft to the palpating finger and there was marked circum-corneal injection. The patient was kept in bed for another week at which time the secondary haemorrhage from the iris absorbed completely and the vision returned to normal.

Treatment of the more serious complications of contusions of the eyeball, e.g. dislocation of the lens, detachment of the retina, haemorrhage into the vitreous, rupture of the choroid, etc., require the care of an ophthalmic specialist.

Fractures of the walls of the orbit frequently produce emphysema in the tissues of the orbital lids. This is due to a communication with the nasal air sinuses, air being forced into the orbital tissues with the blowing of the nose. There is great swelling with a peculiar, soft crepitation on palpation of the eyeballs. X-ray examination will usually demonstrate a small fracture. The treatment of simple contusions with ecchymosis of the lids requires only cold compresses. Emphysema should be treated with a pressure bandage and all straining, blowing of the nose, etc. should be avoided.

Laceration of the lids.—Lid lacerations should be repaired at once, unless signs of infection are already present, the edges being apposed as accurately as possible with fine silk. These lacerations may be either horizontal or vertical. The horizontal ones take the general direction of the fibres of the orbicularis muscle and do not tend to gape; they usually heal without appreciable scar formation and require few sutures. Vertical wounds tend to gape widely and a serious deformity of the lid results if careful apposition is not secured. Lacerations through the lid margin require meticulous repair if the result is to be both cosmetic and functional. The least debridement possible should be done, and fine silk sutures on atraumatic needles used. The most important suture to be placed is that uniting the intermarginal groove. This is the grey line situated between the openings of the Meibomian glands and the eyelashes. The lid border will be in perfect alignment if the first suture placed passes through this line, down into the substance of the tarsus, and then across the line of laceration to enter the tarsus at the same distance from the lid border and comes out in the intermarginal line on the other side of the laceration. The sutures and knots should never be left in contact with the corneal surface since the movement of the globe will cause abrasion and scarring. In the care of severe lacerations where dirt has been carried into the wound, it is safest to give a prophylactic injection of anti-tetanus serum.

Conjunctival Lacerations.—These usually heal spontaneously and require suturing only if there is wide separation of the edges of the wound. Sub-conjunctival haemorrhage should be treated with cold compresses for the first 48 hours, after which time absorption of the blood may be hastened by the use of heat.

Conclusion.—I have reviewed the treatment of ocular injuries which may be well cared for by the general practitioner. The majority of such injuries can, and should be, the responsibility of the physician first seeing the patient. In all cases it is important to record the visual acuity at the outset and at the termination of treatment as so frequently this information is required if further care is necessary, or subsequently compensation for loss of vision is sought. The physician would be well advised to refer the more serious ocular injuries immediately to an ophthalmic specialist for more detailed examination and treatment.

OPHTHALMIC INDICATIONS OF SYSTEMIC DISEASE*

By A. J. ELLIOT, M.D.
Toronto

From the Department of Ophthalmology, University of Toronto, and the Toronto General Hospital.

There are a number of systemic diseases which exhibit ocular manifestations that may be of diagnostic and possibly prognostic importance to the physician. It is my present purpose to discuss briefly a few of these diseases.

In the investigation of these cases there are certain points in the ocular history about which the physician should inquire. Has there been a loss of vision and if so was it gradual or sudden in onset? Is it in one or in both eyes? A Snellen chart is always available to record the visual acuity. Does the patient complain of a loss of part of his visual field? Detailed studies of the visual fields on a perimeter are not required as these may quickly be determined by the confrontation method, using a small white-headed pin. Has the patient complained of double vision? A pencil flashlight is all that is required to test the motility of the extra-ocular muscles.

Of fundamental importance is the actual and symmetrical size of the pupils and their reaction to light and accommodation. The direct and consensual reaction to light should be noted. The accommodative reaction may be determined by having the patient look at a close object such as the examiner's finger held at about six inches from the eye.

Ophthalmoscopic study through the undilated pupil may be made easier by instructing the patient to turn the eye slightly inwards. This will prevent the sudden constriction of the pupil and will allow inspection of the optic disc and adjacent retina. When the pupil is too small for satisfactory ophthalmoscopic examination a few drops of homatropine 1% may be safely used to partially dilate the pupils.

I shall now discuss a number of ophthalmic manifestations which indicate general disease.

Infectious Diseases.—Measles, scarlet fever, influenza and certain cases of pneumonia not uncommonly are accompanied by conjunctival inflammation, corneal ulceration or iritis. Herpes zoster may give rise to severe iritis and iridocyclitis with resultant loss of vision. Diphtheria sometmes causes paralysis of accommodation with blurring of vision at the reading point and, more rarely, paralysis of the external rectus muscle. Erysipelas may cause abscesses and gangrene of the lids, orbital cellulitis and thrombosis of the orbital veins and cavernous sinuses. Animal parasites may infect the eye; trichinosis is perhaps the most common; the larvae lodge in the eye muscles, producing localized inflammation with tenderness and pain on movement of the eye and oedema of the eyelids.

Diseases of the Respiratory Tract.—Conjunctival haemorrhages are common in whooping cough and retinal haemorrhages may also occur. Herpes frequently occurs in pneumonia. Infrequently there is a blood-born bacterial infection to the retina and choroid in pneumonia. This is a metastatic infection and in most of these cases the eye is lost, the ocular inflammation being a complication of the illness.[1]

Case Report J. S., a male aged 28, became ill with lobar pneumonia and 14 days later he complained of marked swelling of the eyelids and bulbar conjunctiva. The eye became proptosed and the cornea opaque; there was rapid loss of vision. A diagnosis of Metastatic Panophthalmitis following lobar pneumonia was made. The eyeball perforated subsequently and a heavy growth of haemolytic streptococcus was cultured

---

[1]McKee, S. H.: Metastatic Ophthalmia in a Patient with Pneumonia, Arch. Ophth. 15:787, 1936.

*Read before the Vancouver Medical Association Summer School, Vancouver, British Columbia, June 2 to June 6, 1947.

from the conjunctiva at the site of the slough. The eye continued to atrophy and later it was removed for cosmetic reasons.

Diseases of the Circulatory System.—

In Essential Hypertension the diagnostic points of retinal arteriosclerosis are compression of the veins at the arteriovenous crossings, narrowing and irregularity in the calibre of the retinal arteries and flame-shaped haemorrhages alongside the vessels. Arteriosclerotic retinitis is a further stage after the above changes have been present for some time. Hard white exudates are present between the disc and the macula and at times there is an irregular macular star or fan. There is usually no oedema at the disc nor large cotton wool patches of exudation.

A detailed ophthalmoscopic study of the retina is important when considering the advisability of Smithwick's sympathectomy for the surgical relief of hypertension.

Malignant Hypertension is the malignant phase of essential hypertension in which the increased intracranial fluid pressure results in headache, loss of vision and papilloedema. These patients often first present themselves at eye clinics. The fundus picture reveals a bilateral papilloedema with numerous flame-shaped haemorrhages alongside the blood vessels. The exudates are soft, cotton wool patches and macular star may appear later.

Digitalis Intoxication with visual hallucinations may occur when this drug is being used in normal amounts in auricular fibrillation. This results in yellowish-green vision which usually disappears within 2 or 3 weeks following cessation or reduction in the dose of digitalis.[2] It is thought to be a visual hallucination due to cortical stimulation from digitalis intoxication and is frequently associated with depression of electro-cardiagraphic ST wave.

Diseases of the Kidneys.—Blindness occurs in cases of uraemia, particularly in acute nephritis, e.g. pregnancy and scarlet fever. It is also found with chronic nephritis. The onset of blindness is sudden—in a matter of hours and is bilateral and complete. The fundus shows no changes unless there is a co-incident albinuric retinitis. The vision usually improves in 10 to 18 hours and may be restored in about 48 hours. Loss of vision is due to the circulation of toxins in the visual centres. Bilateral detachment of the retina may occur in eclampsia; the detachment usually clears up on termination of the pregnancy.

Albuminuric Retinitis usually refers to chronic nephritis with hypertension. Retinal lesions are rare in chronic nephritis without hypertension. In albuminuric retinitis papilloedema is present but is less marked than in malignant hypertension and is not confined to the area around the disc but spreads extensively into the surrounding retina. The retinal vessels show the changes of arteriosclerosis and flame-shaped haemorrhages are present alongside the vessels. Well marked soft cotton wool exudates with blurred edges are usually found around the disc. The macular star figure is present and the retina has more pallor than in malignant hypertension.

Diseases of the Blood.—Retinal haemorrhages frequently accompanied by white spots or exudates in the centre of the haemorrhage often occur in the secondary anaemias of carcinoma and are prominent signs in pernicious anaemia and leukaemia. Great loss of blood may result in a marked loss of vision which is often permanent. Ophthalmoscopic examination in these cases reveals the bilateral pale discs of optic atrophy. The optic atrophy is thought to be due to degeneration of the retinal ganglion cells and their nerve fibres from the toxaemia of the haemolysis.

Case Report: L. B., a male age 60, suffered recurrent haemoptyses from a duodenal ulcer. On one ocasion the haemoglobin fell to 28.5% and on leaving hospital a month later he complained of blurring of vision. Six weeks following this severe haemoptysis it was noticed that both optic discs were slightly pale and that the visual acuity was

---

[2]Carroll, F.: Visual Symptoms Caused by Digitalis, Am. J. Ophth. 28: 373, 1945.

reduced and could not be improved with lenses. The visual acuity was not altered on examination two years later.

Diseases of the Organs of Digestion.—Oral sepsis, especially pyorrhoea, is an important cause of iritis and may cause inflammation deeper within the eye, such as choroiditis. Mal-development of the enamel of the teeth in children is frequently associated with congenital cataracts.

Case Report: G. C., a boy aged 9, was referred by the school nurse because of defective vision and retarded progress in school. On examination with the pupils dilated there was a congenital lamellar cataract in both eyes. There was marked hypoplasia of the enamel in his permanent teeth which had an eroded appearance with transverse lines across them, the incisors and canines being most affected.

Metabolic Diseases.—

Thyroid Disease and Exophthalmos. Deficiency in function of the thyroid gland results in myxoedema and cretinism which give rise to swelling of the eyelids and sometimes produce changes in the lenses. Hyperactivity of the thyroid gland constitutes the disturbance known as exopththalmic goitre or Graves' disease. Although the ocular symptoms are not an essential part, the eyes exhibit one of the most striking manifestations of the affection. Some or all of the following may occur:

The exophthalmos is usually bilateral but unilateral proptosis does occur. Also the cardinal signs of exophthalmic goitre, e.g., lid lag retraction of both upper and lower lids, may be more marked on one side. There are cases of exophthalmos without thyroid intoxication in which there is a paralysis of the extraocular muscles. Also there are cases of very severe exophthalmos in which there is oedema of the lids and conjunctiva. There is danger of corneal ulceration in marked exophthalmos if the lids are not sutured together.

In addition to the above causes of exophthalmos there are sinus disease, sinus mucocele, carcinoma of the antrum, meningioma, aneurysm of the cavernous sinus and orbital cellulitis. These more commonly result in unilateral proptosis. In examining for unilateral exophthalmos it is wise for the examiner to stand behind the patient and look down over the patient's forehead so as to compare the relative amount of protrusion of each eyeball.

Diabetes. Ocular complications are common in diabetes mellitus but bear little relation to the severity of the disease. They occur chiefly in longstanding cases and are not usually seen in younger individuals with severe diabetes. Remarkable changes in the refraction of the eye, both in the direction of hypermetropia and myopia, not infrequently occur in diabetes due to alteration in the refractive index of the cortex of the lens brought about by osmotic changes. This may be characterized by a sudden decrease in vision which had previously been normal or may take the form of repeated smaller changes in vision necessitating frequent changes of glasses.

The ability to use the eye for close work may become impaired in some diabetic patients, because of a weakened condition of the accommodation. This invariably necessitates a stronger lens for reading and close work. Occasional cases of paralysis of the extraocular muscles are also encountered. The sixth nerve is the one most frequently affected by impaired action of the external rectus muscle.

The occurrence of cataract in patients suffering from diabetes is very common especially among older patients but it is observed infrequently in diabetic children. The development of a senile cataract in diabetes bears a closer relationship to the duration of the diabetes rather than to the severity of the disease A true diabetic cataract is rare and occurs in a younger age group and differs from the ordinary type of senile cataract found more commonly in older diabetics.

In diabetic retinitis both eyes are nearly always affected but not necessarily to the same extent. As diabetes is a disease more common in middle life, arteriosclerosis of the retinal vessels is present and vascular hypertension is closely associated. On ophthalmo-

scopic examination the optic discs are usually found to be normal, and the retinal vessels show few changes other than those associated with the patient's age. The haemorrhages and exudates are well defined and characteristic; they are small and deep and are usually not close to the blood vessels. The exudates are opaque, white and shiny, usually placed centrally at the posterior pole of the fundus. At first the exudates appear white but may soon take on a glistening, yellow, waxy appearance. Retinal oedema, papilloedema and soft cotton wool patches do not usually occur in diabetic retinitis. Many patients continue for years with only gradual or slight loss of vision, unless the haemorrhages occur in the macula in which case there is a serious impairment of vision.

Less common ocular complications of diabetes are retrobulbar neuritis, vitreous haemorrhages and retinitis proliferans, lipemia retinalis, diabetic iritis, hypotony in diabetic coma and optic atrophy.

Rheumatoid Anthritis. Chronic rheumatoid arthritis is sometimes associated with low-grade iritis in one or both eyes.[3] As a rule the ocular inflammation is minimal and the patient complains of slight pain in the eyes at night time but there is rather rapid loss of vision. Atropine ointment 1% should be instilled into the eyes three times a day. Relief from pain may be obtained from the use of warm, wet compresses to the eyes three times a day along with sodium salicylate gr. x by mouth t.i.d. .

Diseases of the Generative Organs.—

Gonorrhoea. The ocular complications from gonorrhoea are serious and frequently result in loss of vision in the eye if it is not effectively treated. Gonorrhoeal conjunctivitis is more serious in adults than in babies but fortunately it is comparatively rare. Gonorrhoeal iritis is probably more common than is generally supposed. It frequently follows an attack of gonorrhoeal arthritis, usually in the knees. The patients are almost always men and both eyes may be affected, though not at the same time. Immediate instillation of atropine 1% with the usual supporting treatment for acute iritis is necessary to prevent adhesions forming between the iris and the lens with the resultant loss of vision.

Syphilis. Interstitial Keratitis occurs in congenital luetics, more frequently in girls than in boys between the ages of 5 and 12. After slight irritative symptoms with some redness of the eye, one or more hazy patches appear on the cornea until finally the whole cornea becomes lustreless and dull. In 2 to 4 weeks the cornea becomes vascularized and the whole eye has a dull reddish-pink "salmon" appearance. Active treatment of the iritis with instillation of atropine 1% several times a day is necessary. In practically all cases the vision improves remarkably and, in the majority, the residual visual loss is not great.

Syphilitic iritis occurs from 3 to 6 weeks after the primary infection. It rarely affects both eyes simultaneously but very often the two eyes in succession. Secondary syphilitic iritis accounts for about 15% of the cases of acute iritis in adults.

Disseminated patches of choroiditis due to syphilis are not uncommon and are usually scattered about in the periphery of the retina; usually both eyes are affected. These patches are sharply outlined with black pigment, in the centre of which are areas of choroidal atrophy.

Optic neuritis may occur during the secondary stage of syphilis. It develops 6 to 8 months after the primary chancre. The retina, and often the vitreous, becomes blurred and hazy and there may be well-defined white patches of exudation near the optic disc.

Summary.—In conclusion, although the above remarks were of necessity briefly presented in a somewhat dogmatic fashion, my purpose was to call your attention to the help that these ophthalmic indications of systemic disease can give to the physician in solving some of the problems with which he is so often confronted.

[3]Sorsby, A. and Gormaz, A.: Iritis in the Rheumatic Affections, Brit. Med. J. 4450:597, 1946.

OCULAR FINDING IN IMPORTANT NEUROLOGICAL CONDITIONS*

By A. J. ELLIOT, M.D.
Toronto

From the Department of Ophthalmology, University of Toronto, and the Toronto General Hospital.

The general practitioner is frequently requested to examine patients in whom symptoms of intracranial lesions are found or suspected. It has been said that the practitioner should regard the opthalmoloscope as an instrument as valuable as a stethoscope. He will find the ophthalmoscope distinctly useful in the diagnosis of many obscure cases. With a little experience he can learn to detect the pathological alterations important in the diagnosis of intracranial tumours, viz. optic atrophy and papilloedema.

Pupils.—Normally the pupil measures from 2.5 to 4 mm. The pupil is usually smaller in hyperopia than in myopia, and it is small in infancy and old age. A dilated pupil may follow trauma, the use of a mydriatic, a psychic stimulus, stimulation of the cervical sympathetic nerve, glaucoma, or paralysis of the III nerve. Miosis or contracted pupil will result from the use of a miotic, from synechiae, from stimulation by light or accommodation, in acute iritis, following the administration of morphine, and in paralysis of the sympathetic nerve or stimulation of the III nerve.

The physician should note whether the pupil of one eye is equal in size to the pupil of the other eye and whether it remains so as the intensity of the illumination is increased. If the inequality in the size of the pupils (anisocoria) exists it may be considered physiological if both pupils react alike to all stimuli and to the instillation of cocaine.

In examining the direct and the consensual pupillary reactions to light, care should be taken to ensure that the patient is regarding a distant object and the eyes are well shaded. Note if the constriction of the pupil is well maintained as the lack of sustained constriction is of diagnostic significance in acute retrobulbar neuritis. In testing the accommodative-convergence response, have the patient look in the distance and then quickly have him look at the index finger of the examiner held six inches from the patient's eyes.

If the pupils do not react to light but do react to accommodation-convergence they are called Argyll Robertson pupils. These pupils are small, irregular in shape and often unequal in size. They dilate slowly and unevenly with atropine and do not constrict after the instillation of eserine. The fully developed Argyll Robertson pupils are most frequently seen in tabes but they occur at times in disseminated sclerosis, encephalitis, diabetes, midbrain tumours, chronic alcoholism, syringobulbia and in trauma. The lesion is thought to be somewhere between the point where the pupillary fibres leave the optic tract and the constrictor centre in the III nerve nucleus.

The myotonic (or Adie's) pupillary reaction resembles the Argyll Robertson but occurs in the absence of all signs of syphilis. The tonic pupil is always larger than its fellow and there is a very sluggish reaction directly and consensually to continued light stimulation and to accommodation. It is more common in young women and is often asymptomatic but in others there may be a blurring of vision. The tendon reflexes may be absent. The pupil dilates after remaining in a dark room and eserine constricts the pupil as in the normal pupil.

In Horner's syndrome the pupil is small and there is an incomplete ptosis with a slight enophthalmos. The lesion may be in the descending sympathetic fibres from the hypothalamus or in the cervical sympathetic chain and as a result the pupil cannot be dilated on instillation of cocaine. The most frequent causes of Horner's syndrome

* Read before the Vancouver Medical Association Summer School, Vancouver, British Columbia, June 2 - June 6, 1947.

are spinal cord tumour and syringomyelia above the second thoracic segment. Less commonly enlarged lymph nodes, cervical rib, aortic aneurysm, mediastinal tumour, oesophageal disease and trauma produce the syndrome.

Traumatic paralytic mydriasis may occur after contusion to the eyeball and is probably due to damage to the short ciliary nerves in their passage through the ciliary body. The pupil usually remains moderately dilated and is accompanied by a loss of accommodation.

Optic Atrophy.—The distinction between primary and secondary optic atrophy is an ophthalmoscopic one rather than a pathological differentiation; the essential feature in both instances is a pallor of the disc. In primary optic atrophy the edges of the disc are sharp, the vessels appear normal and the physiological cup is not filled in; whereas in secondary optic atrophy the disc margins are blurred, the vessels are contracted and the physiological cup is obliterated.

The chief cause of primary optic atrophy is tabes. It may be the first sign and other signs and symptoms may be long delayed. The patient should be examined for the presence of Argyll Robertson pupils; the pupils are small, often irregular in shape and unequal in size, and there is absence or impairment of the light reflex with marked accentuation of the accommodative response. The visual fields show progressive peripheral contraction which may result in blindness in a year or two. Less common causes of primary optic atrophy are disseminated sclerosis, cerebral tumours, certain hereditary diseases and poisons such as lead, methyl alcohol and quinine.

Secondary optic atrophy follows long-standing cases of papilloedema and optic neuritis. The opthalmoloscopic appearance is due to inflammatory reaction and the production of fibrous tissue at the nerve head.

Papilloedema—or choked disc, is due to a swelling of the optic nerve head as a result of increased intracranial pressure or interference with the venous circulation of the orbit. Intracranial sinus thrombosis and subarachnoid haemorrhage are causes of such swelling.

In the early stage of papilloedema the retinal veins are congested and the disc is pink, the margins are blurred above, below and nasally, and the physiological cup is filled in. Minute pin point haemorrhages should be noted as their presence will differentiate this stage from the similar appearance of the disc in high degrees of far-sightedness. In the later stages the nerve had is well elevated, the retinal veins are distended, haemorrhages are marked and a macular fan may be seen.

Symptoms may be extremely vague at first. The central vision may be quite normal in which case the pupils will also be normal in size and reactions; this is important to remember and emphasizes the importance of examining the fundus in all cases complaining of headache. However, well developed papilloedema may be present without a history of headache. Normal vision usually remains for a long time after papilloedema has become established. At times there may be transient periods of blurred vision lasting for a few minutes or an hour or two. However, the visual acuity may remain practically unaltered or, if it is diminished slightly, the visual loss bears no direct relationship to the amount of swelling of the discs. If the increased pressure of the intracranial fluid persists, optic atrophy results with permanent loss of central vision even to complete blindness.

Case Report.—D. B., A married woman, aged 42, complained of frontal headache of three years' duration and blurring of vision for one year. Her glasses were changed several times without improvement of vision. During the previous three years she had noticed progressive loss of smell. On examination the vision in the right eye was 5/200 and in the left eye 20/30. The right optic disc was pale; the disc margins were blurred and the blood vessels were sheathed as they left the optic nerve head, indicating papilloedema with advanced secondary optic atrophy. There was marked papilloedema of the disc in the left eye but no pallor. The right visual field was contracted inferiorly while the left visual field revealed enlargement of the blind spot. The sense of smell

was defective. X-ray examination of the skull showed an area of increased vascularity and erosion of bone in the left supraorbital region. Ventriculography revealed a shift of the ventricles to the right with a backward displacement of the left lateral ventricle. A diagnosis of Meningioma of the Olfactory Region was made. A large Meningioma was removed successfully at operation.

There are instances, especially after a recent head injury, where the disc appears as if an early papilloedema were present. In these cases a study of the visual fields is of assistance in differentiating a pathological disc from a normal one with blurred margins. The earliest visual field sign in papilloedema is an enlargement of the blind spot due to oedema at the disc. If this oedema involve the macular area, there may be a blurring in the central part of the visual field. In the later stages the visual field indicates a concentric contraction, which marks the onset of optic atrophy and consequent loss of vision.

The diagnosis of papilloedema is not difficult in severe cases; however, it may be exceedingly so in slight cases. The higher degrees of astigmatism cause apparent blurring of the disc margin, and in markedly far-sighted eyes the disc has the appearance of papilloedema although it is due only to the shortness of the eyeball. In such cases attention must be directed to other signs, such as exudates or haemorrhages. In some cases it is necessary to keep the patient under observation for a period before the presence of papilloedema may be definitely ascertained.

Optic Neuritis and Retrobulbar Neuritis.—These result in a loss of central vision usually in one eye and commonly in the young adult. There may be pain in and around the eye on movement of the globe or on digital pressure over the insertion of the superior rectus muscle. Often the contraction of the pupil is not sustained on prolonged stimulation by light.

In optic neuritis the inflammation is at the nerve head, and on ophthalmoscopic examination there is hyperaemia of the disc with blurring of its margins up to five dioptres of swelling. In retrobulbar neuritis the inflammation is behind the nerve head and the optic disc appears normal. This latter condition has given rise to the aphorism, "the patient sees nothing and the doctor sees nothing".

Visual field examination is important in both conditions and a large central scotoma is always found sooner or later.

In the majority of these cases the patient later develops Disseminated Sclerosis; a careful neurological examination is thus indicated. In some, many years may pass before other manifestations of this sclerosis appear. The local inflammation in the optic nerve subsides in 2 or 3 weeks in the majority of cases with a return of normal vision.

Less commonly, Bilateral Retrobulbar Neuritis with central scotomata occurs in Disseminated Sclerosis, Methyl alcohol poisoning and certain hereditary optic atrophies.

Case Report—J. P., a married woman aged 29, complained of pain over her right eye and pain on movement of the eye. The following day she noticed a blurred area in the centre of her right visual field and the pain on movement of the eye was diminished. Ten years previously she had had a right foot drop with loss of skin sensation from the waist down which remained three months. Ocular examination at the present time revealed marked loss of vision in the right eye with normal vision in the left eye. There was lack of sustained constriction of the right pupil to light. There was pain on palpation over the insertion of the superior rectus muscle of the right eye. The field of vision revealed a large central scotoma which was outlined by the examiner sitting in front of the patient using a white-headed hat-pin. Ophthalmoscopic examination showed normal discs in both eyes. A diagnosis of Retrobulbar Neuritis of the right eye was made. In one month the vision of the right eye had returned to normal. Neurological consultation was advised in view of the previous history and a provisional diagnosis of Disseminated Sclerosis was made.

Ocular Palsies.—Ocular palsies may be supranuclear, nuclear or infranuclear. If the paralysis be in terms of movements of both eyes the lesion is either in the nucleus or

supranuclear in the cerebral hemispheres. Infranuclear palsy is the common finding in which an isolated muscle is paralysed. The third and sixth nerves are affected more frequently than the fourth.

In third nerve palsy there is a partial or complete ptosis; the pupil is dilated and there is no reaction to light or accommodation and the eye is turned downwards and outwards. In sixth nerve palsy the eye is deviated inwards and there is a constant and annoying double vision. A paralysis of the sixth nerve cannot always be used to determine the site of the intracranial lesion as it is often a false localizing sign.

There are numerous causes for ocular palsy. *Trauma* frequently affects the third and sixth nerves. Of the *inflammatory causes* syphilis is the most important and may take the form of a gummatous meningitis or tabes dorsalis. Other inflammatory lesions are pneumococcal meningitis and chronic otitis media with petrositis. Disseminated sclerosis practically never involves the third nerve while the sixth nerve is frequently affected. Of the *neoplasms* producing ocular palsy there are meningiomata of the lesser wing of the phenoid, metastases to the orbit, and carcinoma of the naso-pharynx. *Vascular* lesions from intracranial aneurysms, diabetes and hypertensive accidents are not uncommon causes of ocular palsies.

Hemanianopia.—Hemanianopia denotes the loss of half of the visual field. The commonest clinical form is homonymous hemanianopia in which the left or right half of the binocular field of vision is lost; this condition may be due to a lesion situated in any part of the visual paths from the occipital lobe to the chiasma. Disease in this area causes loss of vision in the corresponding halves in each retina, which results in loss of the opposite halves in the visual fields. Right hemanianopia is more quickly discovered than left, owing to the fact that reading is impossible. The majority of cases of hemanianopia are due to lesions in the occipital lobe or optic radiations; the chief causes are injury by blows on the back of the head or gun-shot wounds, brain tumour, cerebral softening due to syphilis or thrombosis of the blood vessels supplying the occipital cortex.

Lesions between the eyeball and the optic chiasma produce severe damage to only one eye. As a rule, lesions in the chiasma affect both visual fields. A pituitary tumour may result in bi-temporal hemanianopia and, if it grows asymetrically, may cause blindness in one eye and loss of the temporal field of vision in the other. Enlargement of the pituitary body leads to visual defects in about 80 per cent of the cases due to pressure upon the chiasma which lies immediately above, and upon the inner sides of the optic tracts. The visual field is lost from the temporal side and from above downwards, finally involving the nasal field and leading to complete blindness of the affected eye. Soon the vision of the other eye becomes affected in a similar manner. Ophthalmoscopic examination frequently reveals normal discs, or, if the tumour has been present for a considerable time, there may be pallor in the temporal portion of the discs. Papildoedema or choking of the disc is not commonly found in pituitary tumours. In all cases x-ray studies of the skull should be made and often the sella turcica will be found enlarged.

Case Report:—R. W., male, aged 25, complained of dull coronal headaches for the past year and a half, infrequent in periodicity and varying from 2 to 6 hours in duration. He noticed that his lower jaw had enlarged during the past two years. Ocular examination revealed 20/15 vision in both eyes. Visual field examination with a 1 mm. test object at 1 meter's distance indicated contraction of the upper temporal fields of both eyes. X-ray examination revealed a normal condition of the sella turcica. A provisional diagnosis of early acromegaly was made. In view of the commencing visual field loss, radiological therapy to the pituitary body was given.

In conclusion, it is a well-established fact that the eye findings are most important, clinically, in many neurological conditions. The diagnosis will often be delayed if the physician ignores these ocular complaints; whereas, familiarity with some of the more common ocular manifestations will, in many instances, lead to the correct diagnosis.

THE DIFFERENTIAL DIAGNOSIS AND TREATMENT OF AN ACUTELY RED EYE*

By A. J. ELLIOT, M.D.
Toronto

From the Department of Ophthalmology, University of Toronto, and the Toronto General Hospital.

An acutely red eye is a not uncommon medical condition with which the general practitioner is confronted. In its minor forms there may be only slight discomfort and no loss of vision, but in its more serious types it may be fraught with disastrous results and even blindness. It is my purpose to review briefly the differential points in the diagnosis of acute conjunctivitis, acute iritis, and acute glaucoma and in each case to mention the accepted forms of therapy which the general pactitioner may utilise.

Of the three conditions mentioned above, the differential diagnosis of acute glaucoma and acute iritis is of the utmost importance since the treatment of the two is diametrically opposed, atropine being a necessity in iritis and disastrous in glaucoma; on the other hand, it is not necessary or wise to use atropine indiscriminately in cases of acute conjunctivitis where local antiseptics are all that are required in the more benign forms of inflammatory conditions of the conjunctiva.

Conjunctivitis.—Acute conjunctivitis is a common condition which in its minor degrees causes more discomfort and annoyance than its seriousness warrants, but which in the more aggravated types may result in marked loss of vision.

Clinically there are two groups:

1. Those which run an acute course and when successfully treated leave no permanent damage. This group includes simple acute conjunctivitis or "pink eye", and inflammation of greater severity, such as gonorrhoeal conjunctivitis.

2. Those which run a chronic course exhibiting hyperplasia to a marked degree and tend to leave permanent defects. In the latter group trachoma is the chief example.

Signs and Symptoms.—The typical signs and symptoms of conjunctivitis are redness, swelling, pain and conjunctival discharge. Redness occurs from hyperaemia of the blood vessels of the conjunctiva and sometimes from minute haemorrhages. Swelling varies from a barely perceptible oedema to a swelling so intense as to render the lids and globe immobile. Pain is always present in acute cases and these patients complain of a sensation of sand or grit in the eye. The inflammatory reaction affects all the neighboring glands; the tears are excessive, the Meibomian glands are stimulated, the mucous secretion of the conjunctival cells is greatly increased, small pledgets of mucus are seen in the tears, and in more severe case pus cells mingle with the discharge in large numbers. The discharge may become muco-purulent and in severe cases frankly purulent. In intense inflammation the initial discharge may be serous or sanguinous and the discharges readily dry on the edges of the lids, sealing them down. In mild cases there is some blurring of vision while in severe cases the blurring is more marked because of the swelling of the corneal epithelium.

Bacteriological Investigation.—Bacteriological study of the secretion is important in order to determine the aetiological agent. This examination includes smears, scrapings and cultures of the conjunctiva. The cultures are taken with sterile cotton swabs moistened in 1% glucose infusion broth and then streaked over the surface of a blood agar plate. The smears and cultures should be taken directly from the surface of the conjunctiva. The smears are stained by the Gram method and the scrapings by the Giemsa stain.

Treatment of Acute Conjunctivitis.—As in all diseases the most important factor in the treatment is prophylaxis, and once it is developed, the prevention of its spread. Its spread among contacts should be guarded against by scrupulous care of the hands, handkerchiefs, towels and other possible sources of contamination with the discharge.

---

* Read before the Vancouver Medical Association Summer School, Vancouver, British Columbia, June 2 - June 5, 1947.

In wiping the eyes, cotton wool or tissue handkerchiefs should be used and then destroyed. The affected eye should not be bandaged or treated with the old fashioned remedy of poultices of tea leaves, oatmeal or bread. Care should be taken to keep the lids open. If photophobia is present dark glasses may be advised. Before bedtime the conjunctiva should be smeared with an ointment to prevent the lids from sticking together.

The most important single factor in the treatment of acute conjunctivitis is the frequent washing out of the conjunctival sac for its mechanical cleansing action. Warm boracic or saline bathings several times a day with cotton wool pledgets are advised. Local treatment consists of the application of drugs to the eye by lotion, drops or ointments. Drops are instilled into the lower fornix after the lower lid has been pulled down. A large number of drops are in use. Some of the more common are: zinc sulphate gr. ¼ to the ounce, boracic acid gr. 1 to the ounce, argyrol 10%, sulphonilamide or sulphathiazole drops 0.8%, sodium sulphacetamide drops 2½ to 10% and penicillin in saline 200 to 1,000 units per c.c. Ophthalmic ointments may be used instead of drops. The most frequently used eye ointments are: mercury bichloride 1:2,500, metaphen 1:3,000, sulphathiazole 5%, sodium sulphacetamide 2½%, and penicillin 200 to 500 units per gram. These ointments should be instilled into the lower fornix 3 or 4 times per day.

The most serious acute conjunctivitis which must be diagnosed as soon as possible is gonorrhoeal conjunctivitis. In this condition penicillin drops 1,000 units per c.c. are instilled into the conjunctival sac every hour. Frequent copious irrigation of the conjunctival sac with boracic acid or saline solutions are required. Intramuscular injections of penicillin should be given. Great care must be taken to prevent the infection from spreading to the other eye and to other individuals.

Ophthalmia Neonatorum.—It is important to remember that Ophthalmia Neonatorum is not always caused by gonorrhoeal infection. In one series[1] of 261 cases of Ophthalmia Neonatorum reported in the United tates 51% were due to staphylococci, 13% were pneumococcal, 8.8% demonstrated epithelial inclusion bodies, and only 0.5% were gonococcal. However, these figures vary in different centres, as McKee[2] in Montreal found 20% of 55 cases of Ophthalmia Neonatorum due to the gonococcus and 65% demonstrated epithelial inclusions.

Inclusion conjunctivitis of the newborn begins acutely from the 5th to the 8th day after birth and is characterized by severe conjunctival inflammation with oedema and infiltration which is most marked in the lower lid. The acute stage lasts 2 to 3 weeks and is followed by a chronic stage of some weeks' duration. The prognosis is good and a return to normal may be expected in all cases. The condition responds well to the sulphonamides locally and systemically. The diagnosis depends on careful scrapings of the conjunctiva and staining with Giesma stain to show the inclusion bodies.

Chronic Catarrhal Conjunctivitis.—No single causative factor may be responsible for the condition. Among the important aetiological agents are the following: bacteria, principally the staphylococcus and the diplobacillus of Morax-Axenfeld; viruses, such as those causing molluscum contagiosum and the common wart; acme rosacea; allergy streptothrical concretions of the canaliculi; trichiasis; minute foreign bodies; irritants, such as smoke ;refractive errors; excessive secretion of the Meibomian glands; vitamin deficiency; deficient lacrimal secretion; and chronic sinusitis. The treatment of chronic catarrhal conjunctivitis must be directed towards the removal of the responsible aetiological agent.

Acute or chronic conjunctivitis more commonly affects both eyes than one eye only. Even with the utmost care in the prevention of spread from one eye to the other, this eventuality occurs frequently; hence it is important to note that conjunctivitis is often bi-lateral, whereas acute iritis or acute glaucoma is almost invariably uni-lateral. In addition, it should be remembered that conjunctivitis is common in children while

[1]Thygeson, P.: Bacteriologic differentiation of the Common Forms of Conjunctivitis with Particular Reference to Types Prevailing in Iowa, J. Iowa State Med. Soc. 27:15, 1937.

[2]McKee, S. Hanford: Inclusion Conjunctivitis, C. M. Assoc., J. 41:535, 1939.

iritis and glaucoma are rare in this age group; on the contrary, acute iritis and acute glaucoma occur more frequently in adults.

Acute Iritis.—An acutely red eye due to iritis is characterized by a rather sudden onset of marked redness of the eyeball, severe neuralgic pain in the eye and over the forehead, usually worse at night-time, blurring of vision, sensitivity to light and watering of the eye. The clinical course of the disease varies with its severity but the average case lasts from 3 to 6 weeks. The objective signs are redness of the eyeball with a marked circum-corneal blush, exudates into the anterior chamber resulting in cloudiness of the aqueous or solid deposits in the pupillary area and often on the iris, constriction and irregularity of the pupil. On palpation through the lids there may be slight tenderness of the eyeball but the ocular tension is not elevated and it is unusually normal or may be slightly low.

If the patient is seen early and adequate treatment is instituted, the symptoms usually diminish rapidly and in most cases the conditions clears up quickly; the iris returns to normal, the exudates disappear, adhesions between the iris and lens are broken down and there is little, if any, loss of vision. If, however, treatment has not been adequate or timely, the story may be very different, for the iris is permanently bound down to the lens, the inflammatory condition is increased, useful vision is irretrievably lost and the patient is functionally blind in the affected eye.

Aetiology of Iritis.—Iritis is frequently dependent on some systemic disorder, e.g. syphilis or tuberculosis. It may result from a toxin derived from a septic focus in some part of the body, e.g. tonsils, teeth, nose and nasal accessory sinuses, prostate and female genito-urinary organs. In the young adult male it is commonly caused by a previous gonorrhoeal infection. In many cases, even after the most diligent search for a focus of infection, no aetiological agent is discovered.

Treatment of Iritiss—Prompt treatment is a vital factor in the prognosis in acute iritis. This involves rest following atropinization at the earliest possible moment, local heat in the form of warm compresses to the eye several times a day, massive doses of salicylates and a thorough search for the aetiological factor and its elimination.

Atropine 1% or 2% in aqueous solution or ointment diminishes congestion of the iris, puts the iris at rest, dilates the pupil and prevents the formation of adhesions between the iris and the lens or tends to break up those which have already formed. Sufficient atropine should be instilled to keep the pupil widely dilated, every two hours at first and latterly, after the pupil is well dilated, 3 or 4 times a day. Moist hot compresses several times a day diminish pain and inflammation and, with the atropinization, assist in breaking down adhesions which may have formed between the lens and the iris. Salicylic Acid gr.x t.i.d gives relief from pain in the acute stages of iritis. Other important indications are rest in bed in the early stages, protection from light by tinted lenses or a shaded room, a light diet, catharsis and avoidance of all use of the eyes for near work. In the more serious forms of acute iritis the injection of boiled milk 5 to 10cc. into the gluteal region or intravenous injection of typhoid vaccine, starting with 5 million bacilli and increasing the dosage every 2nd or 3rd day to 60 or 70 million bacilli is often of great therapeutic value.

Glaucoma.—One out of ten blind persons in this country is so because of glaucoma. Gluacoma is a pathological condition of the eye which is characterized by an increase in intraocular pressure. When glaucoma is not treated, blindness invariably results if the patient lives long enough.

Acute Congestive Glaucoma.—Acute congestive glaucoma has a stormy beginning. It manifests itself by excruciating pain in and around the eye, head, ears or teeth. Sometimes there is nausea or vomiting; and there may also be fever. Such attacks have been diagnosed wrongly as "bilious attacks". The visual acuity rapidly diminishes and the field of vision is considerably reduced, mostly on the nasal side. Usually only one eye is affected and it quickly becomes very red. One may feel he is dealing with an acute conjunctivitis or iritis. However, the eyelids are never matted together in acute congestive glaucoma and the eye is always hard. The cornea is cloudy and it is almost insensitive to touch with a small piece of cotton wool. The anterior chamber is shallow, the iris discoloured and the pupil dilated. There is usually a greyish-green reflex in the pupillary area. Immediate action is necessary to save this eye from blind-

ness. A miotic such as eserine 1% or pilocarpine 2% must be instilled every few minutes. *At no time must atropine be put into an acutely glaucomatous eye,* and such ointments as yellow oxide of mercury or metaphen have no therapeutic value. It can be seen that there is nothing insidious about this type of glaucoma.

Chronic Non-Congestive or Simple Glaucoma.—For every case of acute glaucoma there are ten cases of simple glaucoma. This is a disease of the eye which slowly and without the patient's knowledge, robs him steadily and painlessly of his sight. It is in this type of glaucoma that the medical practitioner's help is needed for its early discovery.

The impairment of vision is usually at first only in one eye. It may occur as early as 40 years of age with an occasional blur in front of one or both eyes. The blurred vision may last several hours and is often accompanied by a slight one-sided headache. Sometimes he may complain of tearing or experience some difficulty in reading. However, the eye is never red. These symptoms often occur at times of excitement, overindulgence or worry, or after attending the theatre. The vision is often blurred at night and he may see halos around street lights or car lamps; and walking at night is difficult. Sleepless nights accentuate these symptoms.

This dangerously mild course may last months or years before the patient becomes aware of the loss of his central vision. He may have had his glasses changed several times during this period without much improvement in his vision. All this while there is a serious defect developing in his peripheral visual field. When treatment is instituted at this stage it is usually impossible to recover lost vision and the problem now is to arrest the progress and prevent further loss of vision.

The question arises as to how the medical practitioner may acquire the essential points which will assist him in recognizing or at least suspecting glaucoma.[3]

First, he must measure the visual acuity with a Snellen chart with and without the patient's glasses. Any case of subnormal vision in one eye or both eyes must always be investigated further.

Second, he must ask the patient about the occasional occurrence of blurring or clouding of vision, of seeing coloured rings around distant lights, of one-sided headache, or discomfort in and around the eyes after attending theatres, excitement or worry.

Third, he must feel with his fingers whether the eyes are normally soft or abnormally hard. One can easily acquire the sense of normal tension of the eyeball.

Fourth, he must examine the size of the pupils and their reaction to light. Inequality of the pupils or poor reaction to light must be checked further.

Fifth, he should examine each eye with the ophthalmoscope noting whether there is pallor of the optic discs and any excavation. The technique of using the ophthalmoscope is not difficult and one is soon able to acquire sufficient skill to be able to see the optic discs in the majority of patients.

Sixth, he should inquire if there is a history of glaucoma in the family.

These six points will enable the general practitioner to suspect or even detect a case of glaucoma. Having done so he should then direct his patient to an eye clinic or to an eye physician for more detailed ophthalmic examination. Above all, the practitioner should exercise great tact so as not to alarm the patient unduly until the diagnosis of glaucoma is confirmed. Once the diagnosis is established the patient will remain a glaucoma patient, with all that this entails, for the rest of his life.

The general practitioner should remember also that this blindness from glaucoma is frequently preventable. He should know that prevention of blindness from glaucmoa is often attainable by early diagnosis, early treatment and constant watchfulness. On the other hand late diagnosis and late treatment in the majority of cases mean failure.

Summary.—Although the above remarks have been briefly presented, my purpose has been to call your attention to the importance of differentiating between acute conjunctivitis, acute iritis and acute glaucoma when confronted with an acutely red eye. It is not my wish to convert the general practitioner into an ophthalmic specialist but to make him conscious of the important differential points which may be of assistance to him in taking care of this common ophthalmic problem.

[3]Schoenberg, M. J.: The General Practitioner's Part in the Campaign for the Prevention of Blindness from Glaucoma, N. Y. State J. Med., 41: 2216, 1941.

LUMBAR AND SACRAL INTERVERTEBRAL DISCS

J. Gordon McPhee, M.D.

An analysis of one hundred and sixty-eight cases of suspected intervertebral disc protrusion admitted to The Vancouver General Hospital from 1939 to 1946.

From the Department of Radiology, Bede J. Harrison, M.B., Director

According to the records the first laminectomy for protruded intervertebral disc at The Vancouver General Hospital was done on the fourth of November, 1939. Since then, one hundred and sixty-seven others have been done. Eighty-one have been preceded by myelography. Air was used in three as the contrast medium but in the remainder Lipiodol or Pantopaque was used. Usually myelography is requested in cases where confusion or uncertainty exists. We think the request has been necessary in many cases. Operations have proved our point. We wish to state as our thesis that myelography is worthwhile and to prove it we wish to review one hundred and sixty-eight records. Little or no information has been discovered and there is only one legitimate cause for this publication, i.e., to encourage the average practitioner to take more seriously the complaint of low-back pain, whether or not a history of trauma can be obtained. Many practitioners will feel that such a plea would have been correct two or three years ago but that it is unnecessary at the present time. Still it is certain that at least one positive fact appeared out of the cases analyzed, which is, that nearly every individual in this series received therapy of some form or other which in most instances could not possibly have any effect upon a protruded intervertebral disc and less still upon a disc which had ruptured into the neural canal. The writer feels that much time is wasted and that this is the direct result of lack of appreciation of the various manifestations on the part of the patient who has a disc injury.

There is no consistent relationship between protrusion and clinical signs and/or symptoms. It is quite wrong to adopt the attitude of "wait and see," when one keeps the diagnosis of this injury in the differential and it seems unwise to treat the complaint with massage, manipulation, sedation, heat for a prolonged length of time, or, in the writer's opinion, traction of the painful limb. Regarding traction anyone who has dissected in detail the vetebral column will appreciate that a great amount of weight would have to be applied to increase the circumference of any of the lumbar intervertebral foramina in order to diminish pressure upon a nerve root. Even if one admits that such increase of circumference can occur, such a procedure does nothing to alter the relationship betwten root, protruding disc and the *ligamentum subflavum.*

ETIOLOGY: In this series there were forty-three instances in which no known factor could be discovered to account for the complaint. This would tend to emphasize th eneed to keep a disc lesion uppermost in mind. Of this number twenty-five were males and eighteen were females. Straining to lift, move or carry heavy weights accounted for the largest single group of known factors which resulted in disc injury. A significant number of these individuals recalled slipping while attempting to perform a difficult task. This group was comprised of forty-four males and two females. These and other causes in order of frequency are tabulated in Chart No. 1.

By "repeated minor trauma' one refers to the occasional patient whoes job is that of driving a truck, tractor, etc., which entails much bouncing on the seat of his machine.

"Recurrent factors" refers to the rate patient whose occupation results in repeated, very minimal, low-back strain, i.e., elevator operators, (opening and closing the elevator door), operators of compressed air-guns.

I

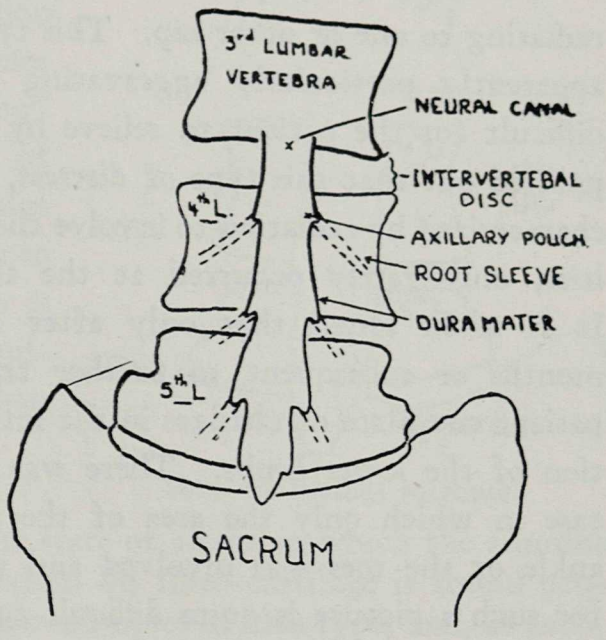

The one cause of childbirth and disc lesion was interesting. The patient had had four children. During the third trimester of the second, third and fourth pregnancies, lumbar pain appared and gradually dominated the patient's life. Following delivery of the second and third pregnancies the pain was greatly diminished. Only because of considerable disability of the left leg following the fourth delivery did she receive attention to the back. A neuro-surgical consultation resulted in the proof of the existence of a herniated nucleus pulposus.

The unfortunate epileptic had complained of lumbar discomfort for years and so repeatedly informed the various medical officers of the Outpatient Department. Following a grand mal attack he was brought into the Emergency Department refusing to move because of the low-back pain which, he stated, radiated as far as the toes of both feet.

Seventeen individuals gave a history of a second severe accident which resulted in back injury. When these individuals were surgically explored a protruding disc with extensive rupture of the *annulus fibrosus* was found in every case, and often pieces of disc fibro-cartilage were found lying free in the neural canal.

II

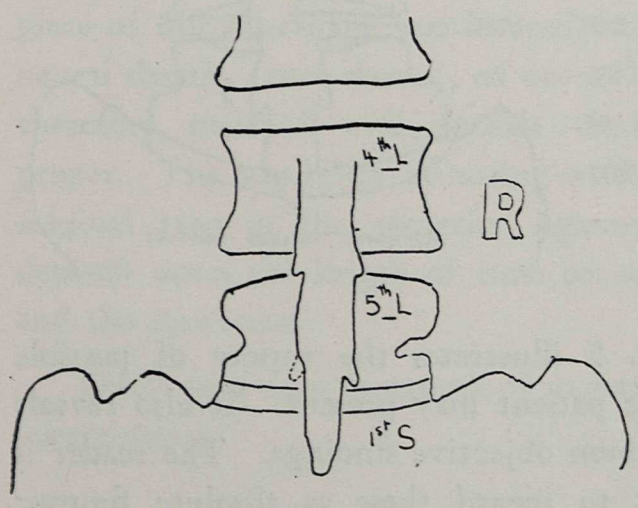

HERNIATION – OBLITERATION AXILLARY POUCH AT L5-S1 LEFT SIDE

The average time interval between the onset of signs or symptoms and operations, whether or not a history of injury is obtainable, for the group twenty to twenty-nine years has been 3.05 years; for the group thirty to thirty-nine years ,it has been 5.3 years; for the group forty to forty-nine years, it has been 4.2 years; and for the group fifty to fifty-nine years, it has been 0.80 years.

Chart No. 2 indicates the number of patients in various ten-year age groups at the time of admission for surgical exploration of the lumbar neural canal.

SIGNS AND SYMPTOMS: Lumbar pain, discomfort or distress was easily the most impressive symptom. The great majority of individuals felt some degree of pain at the time of injury but a large number of this group were able to continue working after a few minutes' rest. Disablement occurred after an interval of days or weeks or months and gradually developed into either a constant or intermittent character. An equally large number complained that the pain occurred subsequent to the injury becoming more severe in a relatively short space of time. This pain also developed into a persistent or an intermittent type.

The incidence of these findings is recorded in Chart No. 3.

One-third of the patients complained of the pain radiating to one or other hip. This type of pain was apparently particularly aggravating and extremely difficult for the patient to relieve by himself. It is pointed out that this type of distress, as well as that characerized by radiation to involve the lower extremities, only rarely occurred at the time of injury. It is often noted that only after an interval of months or subsequent to further trauma does the patient complain of changes in the integrity or function of the lower limbs. There was the infrequent case in which only the area of the knee or lateral ankle or the toes was involved and the explanation for such a picture is quite difficult to find since the disc injury in such cases showed no signficant gross differences from that found in an individual with extensive objective and subjective findings.

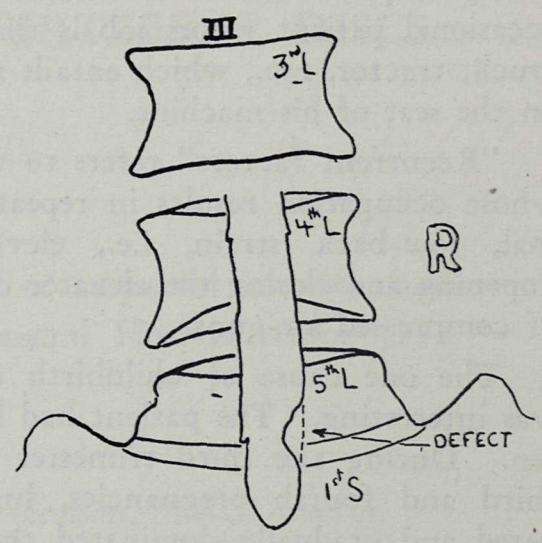

RUPTURED DISC.

The large number of factors which aggravated the pain is indicated in Chart No. 4.

This is impressive when compared with the smaller number of methods by which a patient could obtain relief and also the small number of patients who did obtain relief by using such techniques. This chart should not be regarded as a true indication of the number of times each complaint was made, since many of the histories read by the recorder were not at all complete; but one can say that at least fifty-nine patients complained of aggravation of pain on coughing; and at least thirteen complained of discomfort while walking.

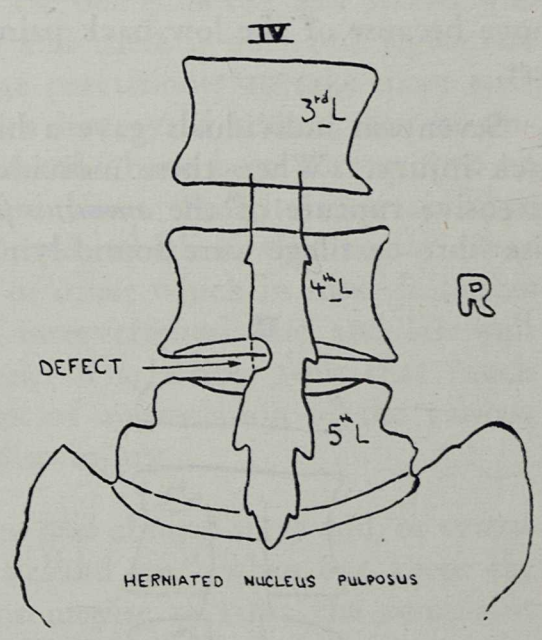

HERNIATED NUCLEUS PULPOSUS

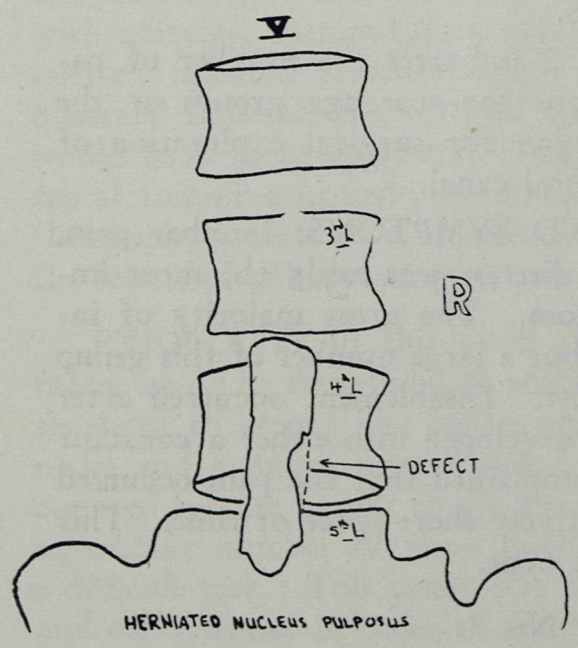

HERNIATED NUCLEUS PULPOSUS

Chart No. 5 illustrates the variety of possible complaints the patient may present. It also reveals the most common objective findings. The reader is cautioned not to regard these as absolute figures; once again one can merely state that at least sixty-six patients had loss of the ankle jerk and that muscle wasting was noted in twenty-five cases.

Twenty-four patients stated that they observed a definite sensation described as a "tightening up," "crack," "snap," "click," "something giving away," "something tearing," or a sudden feeling of weakness in the lower back, at the time of injury.

OPERATIVE FINDINGS: Chart No. 6 classifies the findings at operative exposure of that portion of the intervertebral disc forming part of the anterior wall of the neural canal. The term "protrusion" usually indicates that there has been a separation of all but the outer layer of the fibres of the annulus fibrosus, with herniation of the nucleus pulposus into the partial defect. This is the only type which is correctly termed a herniation of the nucleus pulposus, and, in this series, occurred more often than the other possible types.

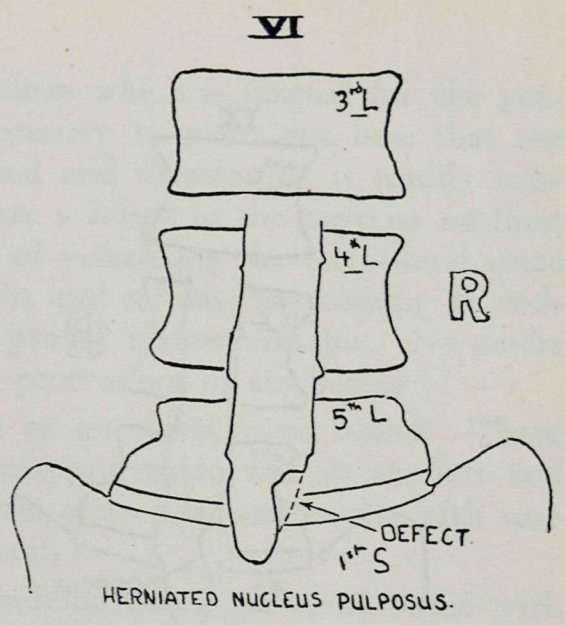

HERNIATED NUCLEUS PULPOSUS.

The term "protrusion and rupture" refers to the state of affairs in which the annulus fibrosus has been torn to the extent that intravertebral dis fibro-cartilage is found protruding into the neural canal. There were sixty-two examples of this type, and, as such, were found in the patients who had the most serious symptoms and were the most disabled. It is suggested that this finding may be due to the fact that, subsequent to partial extrusion of the fibro-cartilage, a greater amount of pressure is placed upon a nerve root which is often found pinched between the protrusion anteriorly and the ligamentum subflavum posteriorly.

The third group is composed of rather a small number of cases in which disc fibro-cartilage was discovered lying outside the traumatized disc and therefore lying in various positions and at varying distances from the damaged disc. An example of this type is well illustrated by the case of one man upon whom a laminectomy was performed a second time because of gradual increase of symptoms following the first exposure which had not revealed the cause of the complaint. At the second exposure a large elongated piece of fibro-cartilage was located down outside the neural sheath, (root sleeve), of one of the nerves and therefore situated well outside the neural canal proper. The possibility of noting whether or not the original tear in the posterior ligament has healed depends upon the length of time between the injury and the operation.

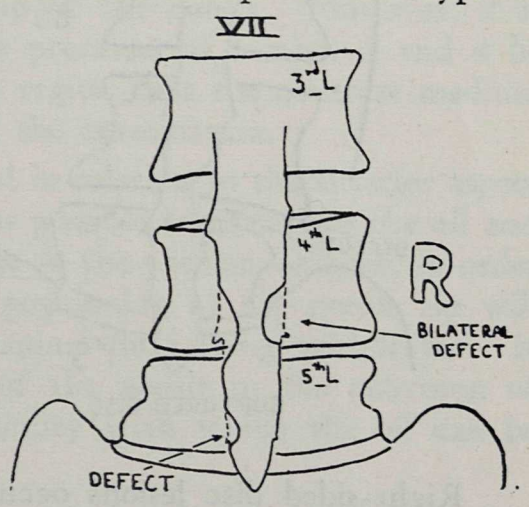

3 HERNIATED NUCLEI PULPOSI

There were four instances of negative findings at operations.

Chart No. 7 shows the intervertebral spaces at which disc lesions were found on surgical exploration. The percentages compare fabourably with those of most investigators. An exception is that only a very few have recorded the positive findings at the space between the first and second sacral bodies.

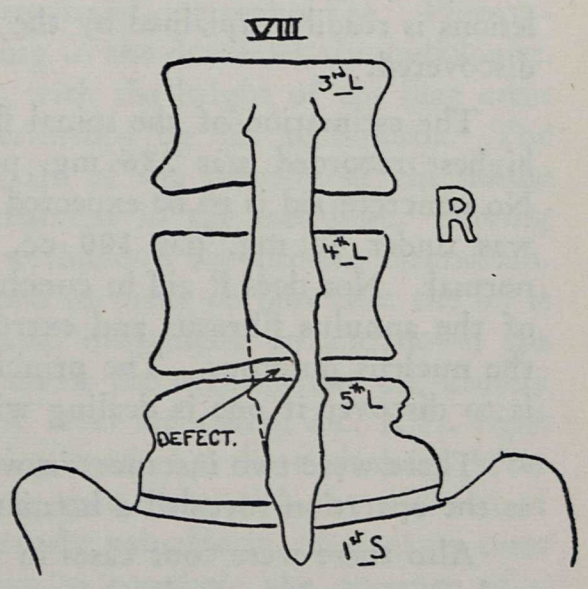

HERNIATION PRODUCING PARTIAL BLOCK

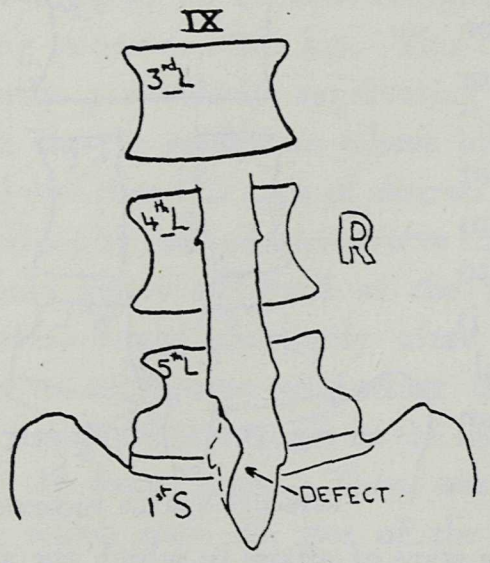

RUPTURED DISC.

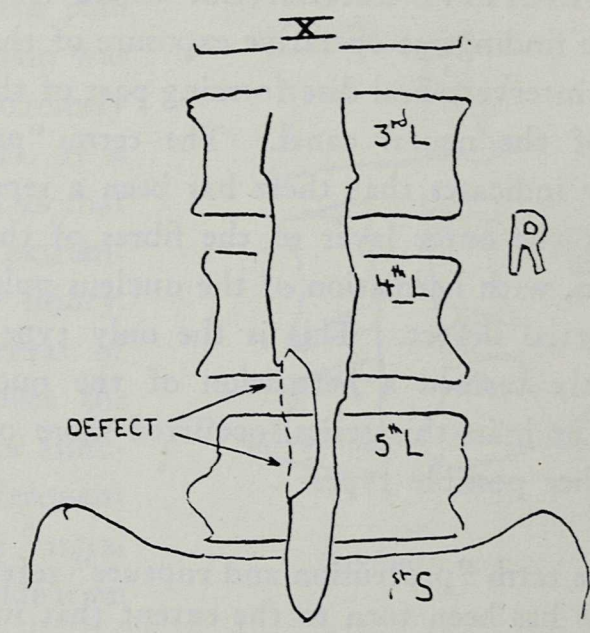

RUPTURED DISC

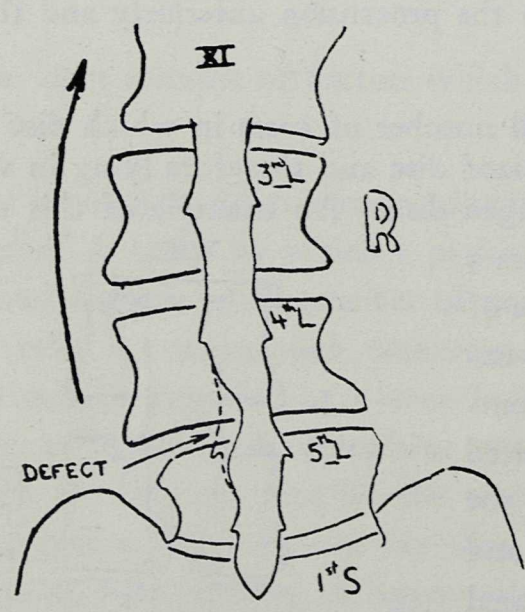

RUPTURED DISC

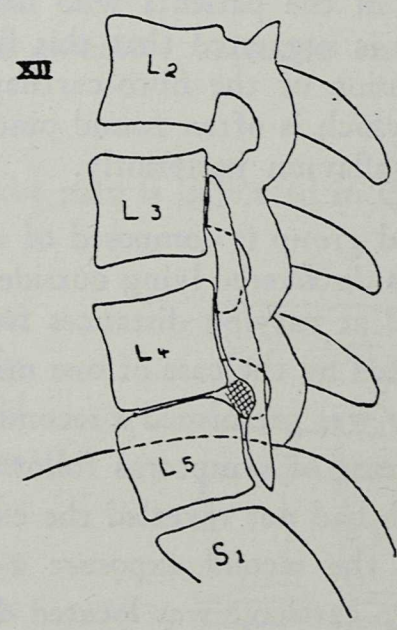

LATERAL VIEW of COLLAPSED INTERVERTEBRAL DISC & ASSOCIATED POSTERIOR PROTRUSION

Right-sided disc lesions occurred in eighty-two cases and left-sided disc lesions in ninety cases. The discrepancy betwen the number of patients and the number of disc lesions is readily explained by the fact that in eleven cases more than one protrusion was discovered.

The estimation of the spinal fluid protein was carried out on fifty-three cases. The highest recorded was 286 mg. per 100 cc. of spinal fluid. The lowest was 20 mg. No concrete aid is to be expected from this procedure for in twenty-two cases the level was under 50 mg. per 100 cc. of spinal fluid, which figure is only slightly above normal. Nor does it aid in concluding whether one is dealing with an extensive rupture of the annulus fibrosus and extrusion of fibro-cartilage or with a simple herniation of the nucleus pulposus. The principle reason for estimating the spinal fluid protein level is to discover if one is dealing with a neoplasm.

There were two instances in which the myelogram was interpreted as negative whereas the operation revealed a herniated disc which was situated laterally.

Also there were four cases in which the myelogram was interpreted as being positive and the operative findings negative. This might be interpreted in the light of the knowledge that the anatomical configuration of the neural canal is not always quite

smooth and can have an intermittent, undulating course which is normal for the particular individual undergoing examination. It is necessary to point out here that the dural sac occupies only two-thirds of the neural canal and therefore it is readily conceivable that disc protrusion can exist but fail to create a defect in the contrast medium contained within the dural sac. No practical method of visualizing the extra-dural space is as yet available. This admittedly is an ever-present and serious shortcoming in each myelographic investigation, and one which has so far proved insurmountable. No doubt there are many cases of low-back distress due to disc protrusions of small size.

Altogether six instances of bi-lateral protrusion at one level were found. There were five instances of two protrusions; in one case one protrusion was on the left and one on the right; in three cases the lesions were on the same side, and in the fifth case one lesion was on the left and the second was bi-lateral.

There is only one instance each of associated spondylolisthesis and spina bifida with disc lesions.

In four instances the signs and symptoms were considered by the surgeon to be due to localized hypertrophy of the annulus fibrosus in the region of the nerve root.

In eleven instances very firm adhesions had formed between the disc and the nerve root which aggravated the difficulty of the operative procedure. In one case adhesions were the only finding but they had obviously interfered with the integrity of the nerve root.

MYELOGRAPHIC TECHNIQUE: The vertebral levels of disc protrusion as indicated by Chart No. 7 would seem to force one to place the spinal puncture needle in the interspace between the spinous processes of lumbar 1 and 2. Our experience has led us to believe that any level can be chosen providing the proper precautions are taken during the positioning and control of the bevelled tip of the needle. However, it is recommended that the interspace between the spinous processes of lumbar 3 and 4 be used since it has become apparent that it is from this region that the contrast medium can be most readily aspirated after the completion of the examination.

It is essential that the needle tip be centrally placed in relation to the anterior aspect of the dural sac if one desires to spend as little time as possible in removing the oil and to avoid the frustrating manoeuvres of tilting the table or the patient, or both, in order to keep the oil and needle in contact. The correct positioning of the needle tip will also result in the removal of the oil with very little spinal fluid being withdrawn. It has become evident that a redesigning of the shape of the needle or the provision of accessory stomata will be required to increase the facility with which the oil can be removed in each case.

At the X-ray Department of The Vancouver General Hospital the entire procedure is carried out by one member of the staff with the assistance of one technician. Preparation and positioning the patient are carried out according to the desires of the radiologist. Usually simple iodine sterilization of the lumbar area, with the height of the iliac crest being indicated by a thin mercurochrome line, is performed by the technician. The radiologist inserts the needle, at all times making certain of the position of the needle tip and altering the bevel in order to keep the instrument in the mid-line. Having entered the dural space, three cc. of spinal fluid are withdrawn for protein estimation. One cc. of oil is injected and the patient is fluoroscoped to make certain that the oil is in the dural sac by noting its single mass and its rapid movement up and down the canal as the table is tilted. Having positioned the oil under the needle, more oil, usually three to five cc. is injected. Three views of each disc level are taken, i.e., A.P., right and left posterior oblique, with four Bucky films being made by the technician after the lesion has been located. These are repetitions of the spot films with the addition of a prone lateral view. The latter film has proved extremely valuable in all positive cases and has many times been instrumental in allowing us to conclude the presence of a protrusion in doubtful cases.

Figure 1 illustrates the outline of the normal lumbo-sacral neural canal. It is on the basis of defects of the contours of the dura mater that a disc lesion can be ascerained. Figures II to XI show a variety of alterations in neural canal contours or anatomical landmarks, e.g., axillary pouch, which have been observed on myelographic films. Figure XII illustrates a lateral view of a disc lesion showing disc material protruding posteriorly and marked narrowing of the intervertebral space. The titles of each drawing indicate the operative findings at exploration.

SUMMARY:

1. The pre-operative and operative findings of one hundred and sixty-eight cases of suspected intervertebral disc protrusion have been presented.

2. A plea is made that in cases of low-back distress, damage to an intervertebral disc should be given a more prominent position in the list of differential diagnosis of the cause of this symptom.

3. Examination of the lumbo-sacral neural canal by contrast myelography has been proven to be a valuable aid in confirming a clinically presupposed level of disc protrusion and of revealing the occasional existence of multiple protrusions in those cases where only a single protrusion had been suspected.

Chart No. 1.

ETIOLOGY

Type	Male	Female	Final Total
Unknown	25	18	43
Weight bearing strains (associated with slipping)	44	2	46
Direct trauma	23	3	26
Sudden twisting or bending forward	16	5	21
Fall	16	4	20
Repeated minor trauma	3	0	3
Indirect trauma	1	0	1
Associated with:			
1. Fracture	1	0	1
2. Dislocated hip	2	0	2
3. Recurrent factors	2	1	3
4. Epilepsy	1	0	1
5. Childbirth	0	1	1
	134	34	168

Chart No. 2.

AGE

Years	Male	Female	Final Total
10 - 19	1	1	2
20 - 29	22	8	30
30 - 39	47	15	62
40 - 49	38	14	52
50 - 59	18	2	20

Chart No. 3.

CHRONOLOGY OF PAIN

		Male	Female	Final Total
Immediate Onset	Constant	46	7	53
	Intermittent	25	4	29
Delayed Onset	Constant	18	3	21
	Intermittent	11	4	15
		100	18	118

Chart No. 4.

DISTRIBUTION AND CHARACTERISTICS OF PAIN

Site	No.	Aggravated By	No.	Relieved By	No.
Lumbar	110	Coughing	59	Bed rest	25
Hip, right	36	Sneezing	52	Buck's extension	10
Hip, left	26	Bending	29	Heat	7
Right Thigh	26	Straining	19	Manipulation (Chiropractic)	6
Calf	11	Walking	13	Physiotherapy (Unqualified)	3
Foot	48	Movement (any type)	10	Sitting	3
Left Thigh	23	Sitting	8	Flexing at hip	3
Calf	18	Standing	6	Walking	1
Foot	46	Flexing hip	4		
Both Legs	11	Straight leg raising	2		
		Laughing	2		
		Low temperature	1		
		Lying down	1		

Chart No. 5.

ASSOCIATED SYMPTOMS AND/OR SIGNS

Symptom	No.
Sensation of numbness	49
Sensation of "pins and needles"	25
Easy fatiguability of back	12
Sensation of stiffness of back	7
Sensation of stiffness of leg	2
Sensation at time of injury of:	
1. "a snap" in the back	8
2. "weakness" in the back	8
3. "a click" in the back	3
4. "tearing" in the back	2
5. "tightening up" in the back	1
6. "crack" in the back	1
7. "giving away" in the back	5
Sensation of cold in leg	5
Sensation of cramps in leg	1

Sign	No.
Muscle spasm	
1. hamstring	66
2. erector spinae	13
Absent ankle jerk	35
Anaesthesia, thigh	24
calf	37
ankle	25
foot	34
Lumbar scoliosis	21
Reduced lumbar lordosis	13
Wasting (muscle)	25
Absent knee jerk	10
Sciatic nerve tenderness	5
Forward bending restricted	5
Backward bending restricted	4
Foot drop	2
Lumbar spine pain (elicited by firm pressure on the spinous process)	L.3- 2
	L.4-20
	L.$-15
	S.1- 5

Chart No. 6.

TYPE OF DISC LESION SEEN AT OPERATION

	Male	Female	Total
Protrusion	68	19	87
Protrusion with rupture	47	15	62
Loose fibro-cartilage	12	2	14
Negative	3	1	4
	130	37	167

Chart No. 7. VERTEBRAL LEVEL OF DISC LESION

	Male	Female	Total
Lumbar 2 and 3	1	0	1
Lumbar 3 and 4	6	0	6
Lumbar 4 and 5	73	9	82
Lumbar 5 and S 1	54	24	78
Sacral 1 and 2	0	2	2
	134	35	169

News and Notes

Congraulations to Dr. James Rankine of Kelowna who was recently awarded the Fellowship to the American College of Surgeons, at the convocation of the College in New York.

Dr. H. E. Taylor, newly-appointed pathologist at Shaughnessy Military Hospital, will lecture in the Department of Bacteriology and Preventive Medicine at U.B.C. We welcome Dr. Taylor to Vancouver and extend best wishes to him in his work.

We note with interest that Dr. V. J. Guttormsson has left his practise at Vanderhoof and is at present studying law at the University of British Columbia.

Dr. A. W. Mooney, of Vancouver, has taken over Dr. Guttormsson's practise at Vanderhoof.

Dr. John Cruise, formerly of Winnipeg, has joined Mr. L. A. C. Panton in Kelowna, and will limit his practise to opthalmology.

Dr. R. W. Woodsworth has moved from Kelowna to Langley Prairie where he will be associated with Dr. A. O. Rose.

Dr. and Mrs. W. J. Knox has returned from a trip to Montreal, Kingston and Toronto.

Dr. H. B. MacGregor has returned from a successful fishing trip to the Cariboo, and Dr. and Mrs. D. J. M. Crawford had a most enjoyable holiday at Banff.

Dr. W. H. White of Penticton has gone to Montreal for several months to do post-graduate work in surgery.

We regret to report the death of Dr. F. H. Trousdale, who has for many years practised in Vancouver. Sincere sympathy is extended to Mrs. Trousdale and family.

Dr. Hugh K. Atwood has moved from Kelowna to take up practise in Vancouver.

Dr. F. W. Brason is now with the Edward J. Meyer Memorial Hospital, Department of Pathology, in Buffalo, New York.

Members of the profession extend deepest sympathy to the following doctors on their recent bereavements: Dr. A. J. Cook, on the loss of his wife; Dr. J. P. Ellis, on the loss of his mother; Dr. L. Friesen, on the loss of his mother; Dr. and Mrs. N. A. Stewart, on the loss of their infant daughter.

Dr. T. C. Harold, resident doctor at Wells, has left for Vancouver, where he has accepted a position with the Workmen's Compensation Board.

Dr. D. T. R. McColl, formerly of Sardis, is now practising at Wells.

We note the appointment of Dr. D. G. Ulrich as medical health officer for the Zeballos district.

Dr. H. S. Hamilton is at present doing post-graduate work at the University of Toronto in opthalmology.

Dr. Douglas Findlay has left Vancouver to join Dr. R. N. Dick at Chemainus.

Congratulations to the following parents on their recent good fortune: Dr. and Mrs. N. J. Blair—a son. Dr. and Mrs. M. L. Edgar—a son. Dr. and Mrs. A. S. McConkey —a danghter.

Dr. F. P. Patterson will be resuming practise with Dr. J. R. Naden in Vancouver.

FOR SALE!

Beck Monocular microscope, with low power, high-dry, and oil immersion objectives, sub-stage condenser and mirror, eyepieces x6 and x10. Like new. $100.00.

ALSO THE FOLLOWING:

American Office Sterilizer.
Bozeman uterine dressing forcep, 9", stainless.
Graves Vag. Speculum, med., stainless.
Schroeder uterine tenaculum, stainless.
Sklar Collyer Pelvimeter.
Diagnostic floor lamp, gooseneck, chrome.
Infra-Red lamp, floor model.
White enamel instrument cabinet, stainless steel trim.
Kirschman Anoscope.
Perfection splinter forcep.
Sprague Ear Set.
Examining Table, adjustable back, footpiece, armboard.

And an assortment of instruments and office paraphernalia. All new.
Terms: List price less 33-1/3%.

For further information, or to view, phone North 666.

IF ARTHRITIS and ECZEMA ARE ALLERGIC ETIOLOGICALLY

effective treatment suggests the use of agents to correct mineral deficiency, increase cellular activity, and secure adequate elimination of toxic waste.

LYXANTHINE ASTIER

orally given, supplies calcium, sulphur, iodine, and lysidin bitartrate — an effective solvent. Amelioration of symptoms and general functional improvement may be expected.

Write for Information.

L-15

Canadian Distributors
ROUGIER FRERES
350 Le Moyne Street, Montreal

Nunn & Thomson

2559 Cambie Street
Vancouver, B.C.

Ayerst

FOR THEIR PROTECTION

Vitamins essential for proper growth and development are readily available in Ayerst biologically-tested Vitamin A and D products.

"ALPHAMETTES"
"ALPHAMETTE" LIQUID
AYERST COD LIVER OILS

Ayerst

AYERST, McKENNA & HARRISON LIMITED • *Biological and Pharmaceutical Chemists* • MONTREAL, CANADA

Introducing

'PENEUCIN'

TRADE MARK BRAND

PENICILLIN OINTMENT

We take pleasure in announcing the introduction of 'PENEUCIN' brand penicillin ointment, in which penicillin is compounded with 'Eucerin' Anhydrous, our well-known brand of Ung. Alcoh. Lanae.

'PENEUCIN' is a stable, elegant and non-irritant ointment that can confidently be prescribed whenever penicillin ointment is required.

'PENEUCIN' is indicated for the treatment of staphylococcal and streptococcal infections of the skin, e.g. Sycosis barbae, impetigo, secondary infected eczema.

'PENEUCIN' is supplied in tubes of 30 grammes, each gramme containing 1,000 units of penicillin (calcium salt).

(M.30)

HERTS. PHARMACEUTICALS LTD., WELWYN GARDEN CITY, HERTS., ENGLAND

Distributing Agents:

MESSRS. VANZANT & COMPANY, 357 COLLEGE STREET, TORONTO, ONTARIO

For the Treatment of

BURNS
INFECTED WOUNDS
ABSCESS CAVITIES
SUPERFICIAL SKIN DISEASES
VAGINAL INFECTIONS

Photograph:
H. S. HAYDEN, F.R.P.S.

"Sulfamul"

A non-adhesive, non-hydroscopic, stable emulsion containing
5% SULFATHIAZOLE "Frosst"

The most effective concentration . . . the most effective vehicle . . . the most effective method yet developed for local application of sulfathiazole. Sulfamul is applied with minimum discomfort to the patient, provides definite local anaesthetic action, requires no frequent changes of dressing, tends to shorten healing time, and promotes most satisfactory cosmetic results.

- *In the treatment of:* Infected Wounds, Abscess Cavities, Burns, Chronic Ulcers and Superficial Infections.
- *As a non-adhesive bacteriostatic pack:* In the Vagina before and after operative procedures on the birth canal.
- *As a dressing for:* Burns about the face, hands and points of flexion.
- *As a bacteriostatic packing in:* Infections about the cervix and vagina.

ADMINISTRATION

Sterile gauze is impregnated with Sulfamul and then packed with moderate firmness into abscess or other infected cavity. The pack may be left in position for periods up to 72 hours, surface changes only being made.

In superficial infections Sulfamul or Sulfamul impregnated gauze, may be directly applied.

MODES OF ISSUE: 2 oz., 1 lb. and 7½ lb. glass jars.

"SULFAMUL" OPHTHALMIC

(Sulfathiazole Emulsion 5% "Frosst")

For the treatment of eye infections such as Conjunctivitis and other pyogenic infections about the eyelids. Remarkable effects have been obtained where the emulsion has been applied locally.

Available in 1/8 oz. long nozzled, collapsible tubes.

Charles E. Frosst & Co.
MONTREAL CANADA

Frosst
SINCE 1899
THE SYMBOL OF PROGRESS
IN PHARMACEUTICAL RESEARCH

Analgesic power

Demerol hydrochloride ranks between morphine and codeine in analgesic power. Furthermore, it possesses marked spasmolytic and mild sedative action. It causes less nausea and vomiting and less urinary retention than morphine, and no constipation. The danger of respiratory depression is also greatly reduced with Demerol hydrochloride. Warning: May be habit forming. Ampuls of 2 cc. (100 mg.) and tablets of 50 mg. Narcotic blank required.

WINTHROP

Write for detailed literature

DEMEROL
HYDROCHLORIDE

Brand of meperidine hydrochloride (isonipecaine)

Winthrop
CHEMICAL COMPANY, INC.
NEW YORK 13, N. Y. • WINDSOR, ONT.

DEMEROL, trademark Reg. U.S. Pat. Off. & Canada

for the patient with distressing urinary symptoms

The prompt sympomatic relief provided by Pyridium is extremely gratifying to the patient suffering from distressing symptoms such as painful, urgent, and frequent urination, nocturia, and tenesmus.

Pyridium, administered orally in a dosage of 2 tablets t.i.d., will promptly relieve these symptoms in a large percentage of ambulant patients, thereby permitting them to pursue normal activities without undue discomfort.

Since Pyridium acts directly on the mucosa of the urogenital tract, this important effect is entirely local. It is not associated with or due to systemic sedation or narcotic action.

Therapeutic doses of Pyridium may be administered with little fear of serious toxic effects throughout the course of most cases of cystitis, pyelonephritis, prostatitis, and urethritis.

• LITERATURE ON REQUEST •

PYRIDIUM

(Phenylazo-alpha-alpha-diamino-pyridine mono-hydrochloride)

MERCK & CO. LIMITED

Manufacturing Chemists

MONTREAL • TORONTO • VALLEYFIELD

Pyridium is the Canadian registered trade mark of the product manufactured by Pyridium Corporation.

Clinical experiences have demonstrated that the administration of xanthines may double coronary circulation and allow a greater amount of work to be performed.

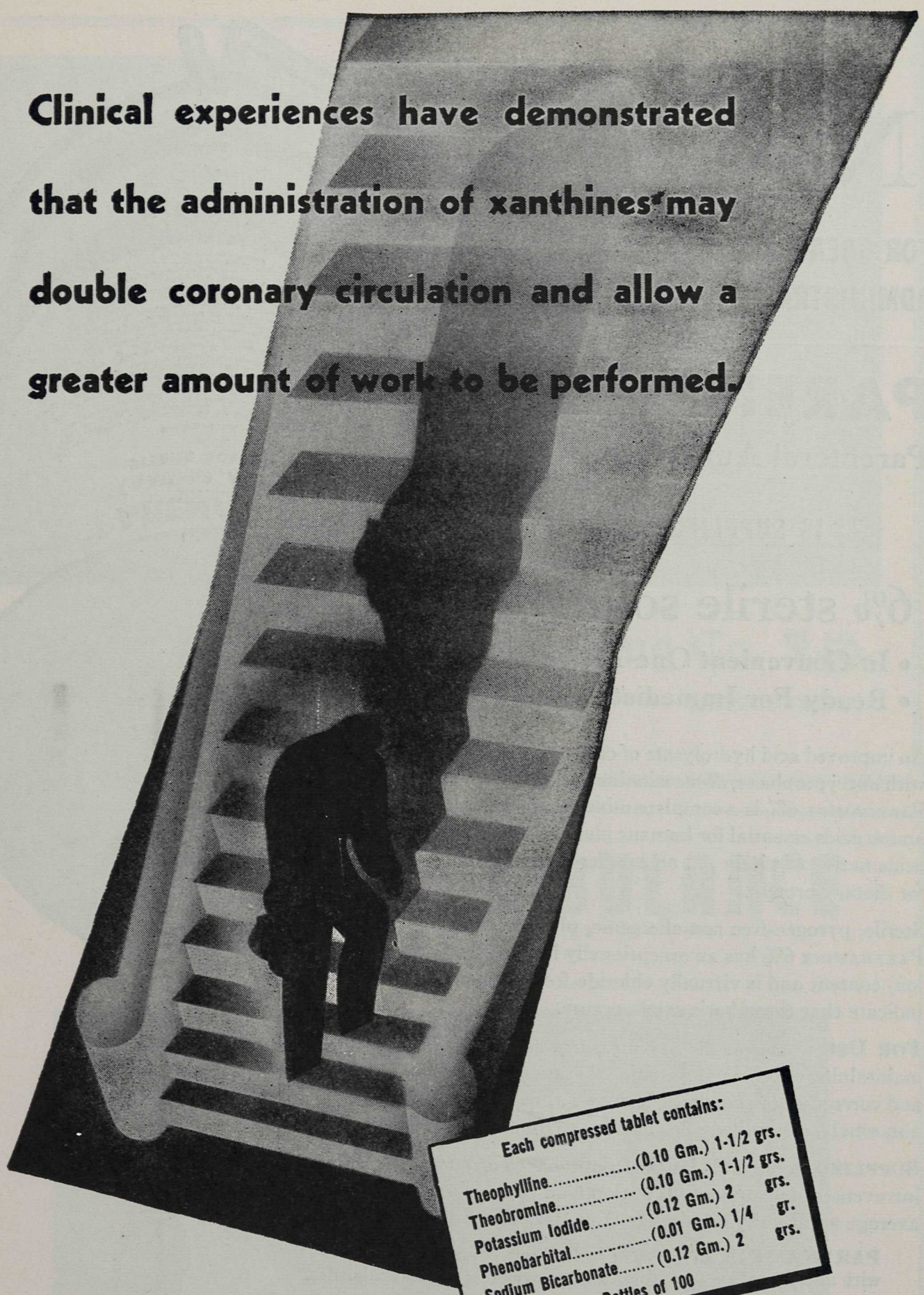

Each compressed tablet contains:

Theophylline	(0.10 Gm.)	1-1/2 grs.
Theobromine	(0.10 Gm.)	1-1/2 grs.
Potassium Iodide	(0.12 Gm.)	2 grs.
Phenobarbital	(0.01 Gm.)	1/4 gr.
Sodium Bicarbonate	(0.12 Gm.)	2 grs.

Bottles of 100

XANTOPHEN

ROUGIER FRÈRES, 350 Le Moyne Street, MONTREAL (1)

Now...

FOR GREATER EASE OF ADMINISTRATION

PARENAMINE

Parenteral Amino Acids Stearns

IS SUPPLIED IN

6% sterile solution

- In Convenient One-Liter Bottles
- Ready For Immediate Use

An improved acid hydrolysate of casein, fortified with *dl*-tryptophane, *dl*-methionine and glycine, PARENAMINE 6% is a complete mixture of all the amino acids essential for humans plus other amino acids native to casein . . . an excellent substitute for dietary protein.

Sterile, pyrogen-free non-allergenic, pH 5.5, PARENAMINE 6% has an exceptionally low ash (sodium ion) content and is virtually chloride-free. Clinical studies indicate that thrombosis rarely occurs.

FOR USE whenever dietary measures are inadequate for maintaining an optimal nutritional status . . . for prevention and correction of protein deficiency . . . to compensate for abnormal losses of body proteins . . . to fulfill increased demands.

SUPPLIED in one-liter bottles adaptable to any type of intravenous delivery set-up . . . 60 Gm. of amino acids (the average adult daily requirement) in 1000 cc. of distilled water.

PARENAMINE 15%—acid hydrolysate of casein fortified with *dl*-tryptophane—continues to be available in 100 cc. bottles.

Frederick Stearns & Company of Canada, Ltd.

WINDSOR, ONT.

S-117A

Parenamine Trade Mark Reg.

NEW YORK KANSAS CITY SAN FRANCISCO DETROIT ATLANTA SYDNEY, AUSTRALIA AUCKLAND, NEW ZEALAND



Mount Pleasant Undertaking Co. Ltd.

KINGSWAY *at* 11th AVE. Telephone FAirmont 0058 VANCOUVER, B. C.

W. E. REYNOLDS

EXCLUSIVE AMBULANCE SERVICE



VANCOUVER: 13th Avenue and Heather Street **FAir. 0080**

NEW WESTMINSTER: 814 London Street **NW. 60**

We Specialize in Ambulance Service Only

J. H. GRELLIN W. L. BERTRAND

DYCHOLIUM

CHOLERETIC OF CHOICE

★ A practically nontoxic derivative of cholic acid, DYCHOLIUM exerts a prompt and active stimulation on the secretion and flow of bile.

★ The action of DYCHOLIUM does not apply only to the external secretory function of the liver, but also to certain internal functions, especially that of detoxification.

HOW SUPPLIED

Tubes of 20 and bottles of 100, 500 and 1,000 tablets each containing 5 grains (0.30 Gm.) of dehydrocholic acid

Boxes of 6 ampoules of 5 c.c. each containing 1 Gm. of active product

★ INDICATIONS

ICTERUS — ANGIOCHOLITIS — CHOLECYSTITIS
CHOLELITHIASIS — POSTOPERATIVE MANAGEMENT OF GALL BLADDER SURGERY — CIRRHOSIS
MILD DEGREES OF LIVER IMPAIRMENT

Laboratory Poulenc Frères
OF CANADA LIMITED — MONTREAL

Amphojel gives excellent results in the prophylaxis and treatment of peptic ulcer because:

- it relieves pain promptly and hastens healing
- it enables the patient to take a well balanced diet without aggravating ulcer symptoms—weight gain during treatment is frequently reported
- it buffers gastric chyme within physiological limits and without risk of producing secondary hypersecretion of acid
- it prevents peptic digestion by immediately precipitating pepsin
- it is an amphoteric, unabsorbable substance and will not disturb the acid-base balance of the body

Bottles of 12 fl. oz.

For your convenience
AMPHOJEL IN A NEW FORM
AMPHOJEL
Magnesium Trisilicate Added

Amphojel • *Alumina Gel* • *Wyeth*

Trade Mark Reg. in Canada

JOHN WYETH & BROTHER (CANADA) LIMITED • WALKERVILLE, ONTARIO

Radium

THE INDISPENSABLE IN MODERN MEDICAL PRACTIC

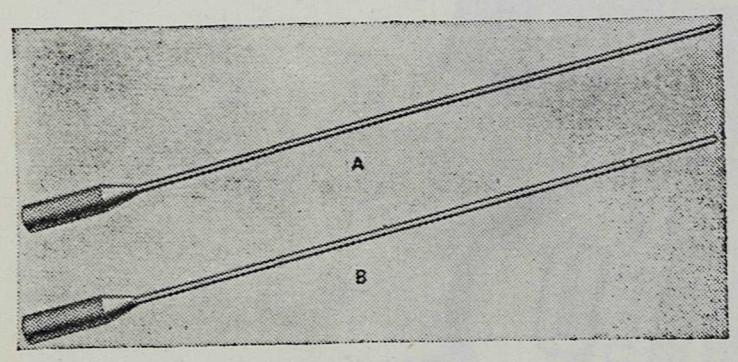

A—Nasal Applicator, Burnham Crowe Type
A comparatively new development found to be of great value in Naso-Pharyngeal Therapy. Tube is constructed of Monel metal with a wall thickness of 0.3 mm. Radioactive length of 15 mm. external length 21 mm. and external diameter 2.3 mm. Permanently attached semi-rigid handle.

B—Nasal Applicator
Similar in all respects to (A) but with detachable handle.
Tube is equipped with thread holes for uses other than naso-pharyngeal.

High purity RADIUM is available Medical needles, tubes and plaques of sizes.

Excellent service is offered in the i spection, repair, and reconditoning your present RADIUM stock, and in co version of RADIUM from defecti containers into containers of new desi and size.

Complete supplies of Accessory Equi ment are maintained at all branches.

The highly skilled Physicists and Che ists of this firm are fully qualified to gi expert assistance in planning t RADIUM stocks most suited to yo needs.

Contact any office of X-Ray and Radium Industries Ltd., for further information.

KELEKET

X-ray AND Radium
INDUSTRIES LIMITED

261 Davenport Rd. - Toronto 5

QUEBEC • MONTREAL • WINNIPEG • EDMONTON • CALGARY • VANCOUV

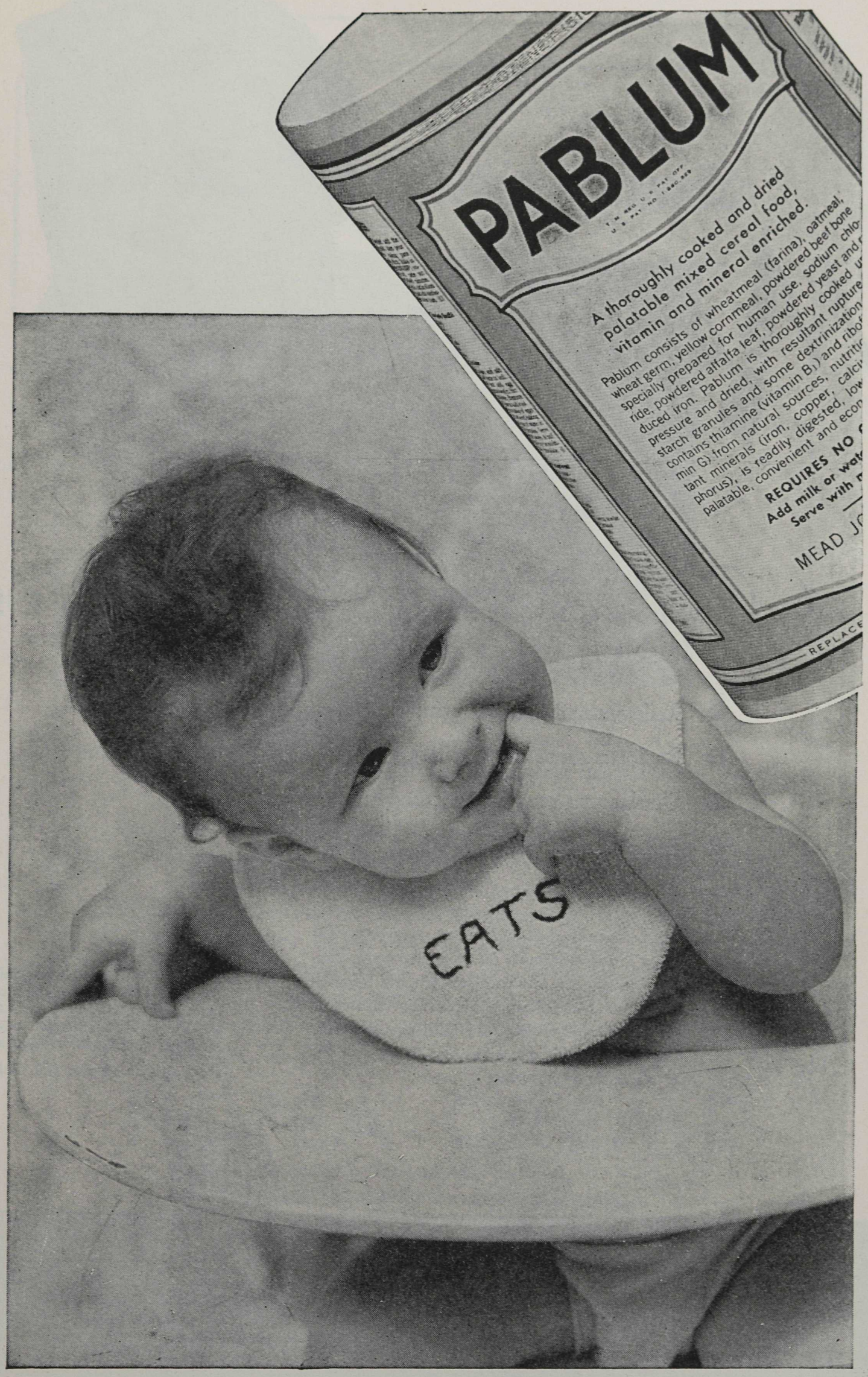
PABLUM
A thoroughly cooked and dried palatable mixed cereal food, vitamin and mineral enriched.
Pablum consists of wheatmeal (farina), oatmeal, wheat germ, yellow cornmeal, powdered beef bone specially prepared for human use, sodium chloride, powdered alfalfa leaf, powdered yeast and reduced iron. Pablum is thoroughly cooked under pressure and dried, with resultant rupture of starch granules and some dextrinization. Pablum contains thiamine (vitamin B1) and riboflavin (vitamin G) from natural sources, nutritionally important minerals (iron, copper, calcium, phosphorus), is readily digested, low in bulk, palatable, convenient and economical.
REQUIRES NO
Add milk or water
Serve with
MEAD JO
REPLACE
EATS

Meprane

ORALLY POTENT ESTROGEN

4 Outstanding ADVANTAGES

- Relieves menopausal symptoms promptly.
- Restores sense of well-being.
- Unpleasant reactions virtually unknown.
- Exceptionally economical.

The brilliant synthesis of Meprane culminates eight years' intensive research for an orally potent, clinically dependable, synthetic estrogen, free from the disadvantages of diethylstilboestrol. Estrogenic economy is now available to physicians without the hazards of patient discomfort and imperfect relief of menopausal symptoms.

Dosage: In the menopause, initial therapy—1 tablet t.i.d. after meals; maintenance therapy—1 to 2 tablets daily. Recommended dosage for other conditions on request.

Packaging: 30 and 100 tablets.

R AND C

REED & CARNRICK (CANADA) LTD.

TORONTO, ONTARIO, CANADA

The therapeutic cosmetic

In addition to its value as a cosmetic, Nivea Creme has certain therapeutic properties. Nivea is a water-in-oil emulsion containing Eucerite, a mixture of solid alcohols closely related to the skin's fatty secretions. Nivea readily penetrates the epidermis and combines with the skin's natural oils. It is valuable in cases where disease has left the skin scaly; to protect the skin during radiant heat and X-ray treatment; as a cleansing medium where soap and water is contra-indicated. Doctors themselves will find Nivea useful to counteract the effects of "scrubbing up" and frequent washing.

NIVEA CREME

Professional Pack containing 1lb. 370A

'NIVEA' and 'EUCERITE' are registered Trade Marks

Made in Canada by NIVEA PHARMACEUTICALS LTD., 357 College Street, TORONTO
Distributing Agents: VANZANT & COMPANY, 357 College Street, TORONTO

(C29)

G-E X-RAY PROUDLY ANNOUNCES

THE NEWEST ADDITION TO THE FAMILY

The G-E Prescription Model Ultraviolet Lamp offering you all the famous G-E X-Ray quality and service in a new low cost ultraviolet lamp.

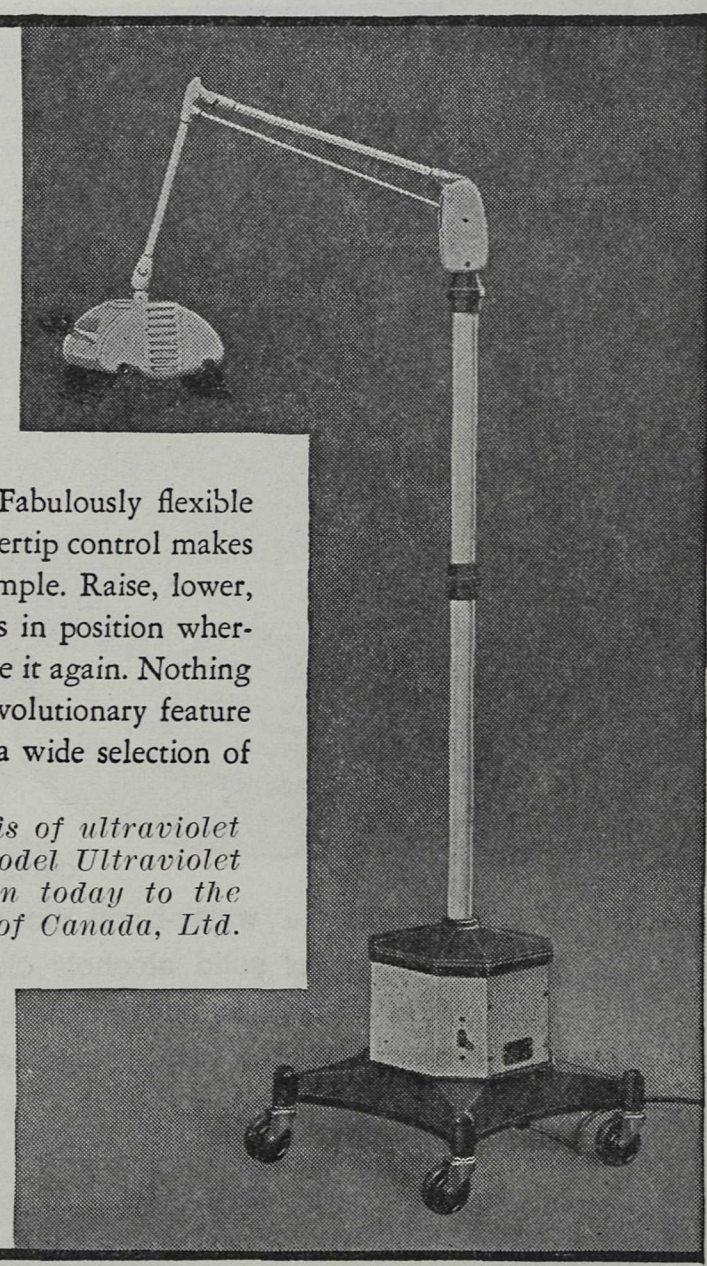

This new, economically priced lamp features the famous G-E Uviarc high pressure mercury quartz burner—economical to operate and with emission characteristics covering the full range of therapeutic ultraviolet. Long familiar to users of G-E professional type lamps, the Uviarc burner emits intense, uniform radiation throughout the spectral bands of proven clinical value.

The compact, sturdily constructed burner housing is mounted on the Dazor Floating Arm. Fabulously flexible and almost human, this remarkable arm with its fingertip control makes the positioning of the lamp amazingly swift and simple. Raise, lower, swing the burner housing through an arc; it freezes in position wherever you stop it—and it stays there too until you move it again. Nothing to tighten, no time consuming adjustments. This revolutionary feature facilitates rapid positioning of the lamp and offers a wide selection of treatment distances.

Plan now to offer your patients the benefitfis of ultraviolet the year-round with the G-E Prescription Model Ultraviolet Lamp. Clip and mail the convenient coupon today to the nearest office of Victor X-Ray Corporation of Canada, Ltd.

VICTOR X-RAY CORPORATION of CANADA, Ltd.

DISTRIBUTORS FOR GENERAL ELECTRIC X-RAY CORPORATION

TORONTO: 30 Bloor St., W. - VANCOUVER: Motor Trans. Bldg., 570 Dunsmuir St.
MONTREAL: 600 Medical Arts Building - WINNIPEG: Medical Arts Building



℞ Please send me detailed information on your new Prescription Ultraviolet Lamp.

Name_____

Address_____

City_____

State or Province_____

2667

BULLETIN

of the

Vancouver Medical Association



Volume XXIII. 1946 - 1947

BULLETIN OF THE VANCOUVER MEDICAL ASSOCIATION

VOLUME XXIII.

1946-47

INDEX

A

Page

ABDOMINAL PAIN IN INFANTS AND CHILDREN, CAUSES OF—Clement A. Smith.... 302
AMERICAN COLLEGE OF SURGEONS—Sectional Meetings.... 98
AMERICAN UROLOGICAL ASSOCIATION—Urology Award.... 67
ANGINA, AGRANULOCYTIC, TREATED WITH PYRIDOXINE HYDROCHLORIDE—
E. S. James.... 58
ANTHONY, A. R.—Highlights of Ophthalmology.... 81
APPLEBY, L. H., & JACKSON, PAUL P.—Case of Unusual Mesenteric Tumour.... 20
APPLEBY, L. H.—Vagotomy.... 84
—Surgery or Propyl Thiouracil.... 135
ARTHRITIS, RHEUMATOID—Russell L. Cecil.... 40

B

BAKER, H.—Kernicterus.... 239
BALFOUR, JOHN—Sterility in the Male.... 112
BLOOD DISEASES—Discussion of some Aspects of Leukemia, Infectious Mononucleosis
and Agranulocytosis—Cyrus C. Sturgis.... 277
BLOOD BANK SUPPLIES—Growing Deficit.... 322
BRITISH COLUMBIA MEDICAL ASSOCIATION—
Annual Meeting.... 250
Annual Reports.... 252
Benevolent Fund.... 151
Report of Representative on Executive Committee C.M.A.... 320
Southern Interior Medical Association.... 11
Upper Vancouver Island Medical Association Annual Meeting.... 51
West Kootenay Medical Association Annual Meeting.... 11
BURKE MEMORIAL CANCER FUND.... 9
BURNS, TREATMENT OF—Roy D. McClure.... 270

C

CANTRIL, SIMEON T.—The Use of Radioactive Isotopes in Biology and Medicine.... 152
CECIL, RUSSELL L.—Rheumatoid Arthritis.... 40
CHEMOTHERAPY IN INFECTIONS OF THE EARS AND PARANASAL SINUSES—
J. R. Lindsay.... 35
CHEMOTHERAPY IN SURGERY—Roy D. McClure.... 267
CHEST DISEASE, NON-TUBERCULOUS, SURGERY FOR—Elliott Harrison.... 121
CHIVERS, N., and VICKERS, K.—Progress in the Treatment of Meningitis.... 44
CHIROPODY—AN AUXILIARY TO MEDICAL PRACTICE—J. H. MacDermot.... 296
CLEVELAND, D. E. H.—Preparation of Manuscripts for Publication.... 137
COLLEGE OF PHYSICIANS AND SURGEONS—
Appointment of Dr. F. L. Whitehead.... 223
Coroners Act.... 322
COLON, POLYPOSIS OF—C. G. Pow.... 178
CORRESPONDENCE—
Moukden Medical College.... 186
Pharmaceutical Association of B. C.... 52
Specimens mailed to Provincial Laboratory.... 218
Vancouver General Hospital Staff Appointments.... 218

D

DIRECTION IN WHICH WE ARE GOING—A. E. Grauer.... 224

E

ELECTROLYTES, RECENT ADVANCES IN ADMINISTRATION OF—A. T. Hardyment 60
ELLIOT, A. J.—The Treatment of Ocular Injuries in General Practice.... 333
—Ophthalmic Indications of Systemic Disease.... 336
—Ocular Findings in Important Neurological Conditions.... 340
—The Differential Diagnosis and Treatment of an Acutely Red Eye.... 344
EPILEPSY, A CASE OF PSYCHOMOTOR—W. J. Fowler.... 66
EUSTACHIAN TUBE FUNCTIONS AND ITS RELATION TO DEAFNESS—
J. R. Lindsay.... 160
EYE, EAR, NOSE AND THROAT, SYMPOSIUM.... 76

INDEX—*Continued*

F

Page

FACE AND JAW, INJURIES OF—Robert G. Langston 168
FAMILY WELFARE BUREAU—The Unmarried Mother 249
FOWLER, W. J.—A Case of Psychomotor Epilepsy 66
—Tetanus—A Case Report 236
FROST, A. C., and FROST, A. C. GARDNER—Review of 422 Cases of Sterility in Private Practice 103

G

GANSHORN, JOHN A.—Acute Pancreatitis 12
GASTROSCOPY, MODERN, and GASTRIC DISEASE—Roger Wilson 272
GEORGE WASHINGTON, UNIVERSITY SCHOOL OF MEDICINE—Post Graduate Course 52
GRAUER, A. E.—The Direction in Which We Are Going 224

H

HARDYMENT, A. F.—Recent advances in Administration of Electrolytes 60
HARRISON, BEDE J.—Medicine and Some Orthodoxies (Osler Lecture) 197
HARRISON, ELLIOTT—Surgery for Non-Tuberculous Chest Disease 121
HEART AND GREAT VESSELS, SURGICAL CONDITIONS OF—Ross Robertson 130
HUGGARD, ROY—Vagotomy 211
HUNT, LEIGH—A Changed Concept of Pelvic Inflammation 109

I

INCOME TAX RETURNS, DOMINION, BY MEMBERS OF THE MEDICAL PROFESSION 99
INTERVERTEBRAL DISCS, LUMBAR AND SACRAL—J. Gordon McPhee 348

J

JACKSON, PAUL P., and APPLEBY, L. H.—Case of Unusual Mesenteric Tumour 20
JAMES, E. S.—Agranulocytic Angina Treated with Pyridoxine Hydrochloride 58
—A Case of Obstructive Jaundice 175
JAUNDICE, A CASE OF OBSTRUCTIVE—E. S. James 175

K

KELLY, A. D.—Refugee Physicians 328
KERNICTERUS—H. Baker 239

L

LANGSTON, ROBERT G.—Injuries of the Face and Jaw 168
LEESON, L. H.—Recent Advances in Otolaryngology 78
LINDSAY, J. R.—Chemotherapy in Infections of the Ears and Paranasal Sinuses 35
Eustachian Tube Function and Its Relation to Deafness 160

M

MANUSCRIPTS FOR PUBLICATION, PREPARATION OF—D. E. H. Cleveland 137
MEDICAL EDUCATION, PROBLEMS AND TRENDS IN—Edward L. Turner 29
MEDICINE AND SOME ORTHODOXIES—Bede J. Harrison 197
MENINGITIS, PROGRESS IN THE TREATMENT OF—N. Chivers and K. Vickers 44
MESENTERIC TUMOUR, CASE OF—Paul P. Jackson and L. H. Appleby 20
MURRAY, STEWART—Acute Anterior Poliomyelitis 221

Mc

MACDERMOT, J. H.—Chiropody, An Auxiliary to Medical Practice 296
McCLURE, ROY D.—Chemotherapy in Surgery 267
—The Treatment of Burns 270
McLEAN, JOHN A.—Highlights of Ophthalmology 76
McLEAN, T. K.—Treatment of an Unusual Case of Spontaneous Pneumothorax 176
McPHEE, J. GORDON—Lumbar and Sacral Intervertebral Discs 348

N

NATIONAL FILM BOARD 75
NEWBORN, DISEASES OF, ASPHYXIA, ATELECTASIS, ERYTHROBLASTOSIS—Clement A. Smith 311
NEWBORN, DISEASES OF, DIARRHEA, PREMATURITY—Clement A. Smith 316
NEWBORN INFANTS, PHYSIOLOGICAL PECULIARITIES OF—Clement A. Smith 307
NEWS AND NOTES 22, 47, 69, 115, 139, 181, 214, 244, 285, 323, 356

INDEX—*Continued*

Page

OBITUARIES—
- BLACKWOOD, BERTIE ... 243
- GRAHAM, WILFRED L. ... 180
- GRANT, JAMES F. ... 138
- MacEWAN, S. C. ... 243
- MOONEY, WILBUR CRAIG ... 19
- SAUNDERS, THOMAS FISON ... **185**
- SCATCHARD, WALTER ... 180
- WALTON, R. A. ... 43

OBSTETRICS, MODERN TRENDS IN—N. W. Philpott ... 88
OCULAR FINDINGS IN IMPORTANT NEUROLOGICAL CONDITIONS—A. J. Elliot ... 340
OCULAR INJURIES IN GENERAL PRACTICE, TREATMENT OF—A. J. Elliot ... 333
OPHTHALMIC INDICATIONS OF SYSTEMIC DISEASE—A. J. Elliot ... 336
OPHTHALMOLOGY, HIGHLIGHTS OF—John A. McLean ... 76
—A. R. Anthony ... 81
OREGON ACADEMY OF OPHTHALMOLOGY & OTOLARYNGOLOGY—
- Post Graduate Course ... 102

OSLER LECTURE—Medicine and Some Orthodoxies—Bede J. Harrison ... 197
OTOLARYNGOLOGY, RECENT ADVANCEMENTS IN—L. H. Leeson ... 78

P

PAEDIATRICS, SYMPOSIUM ON RECENT ADVANCES ... 53
PAEDIATRIC DISEASE, A MODERN RE-EMPHASIS OF THE ROLE OF INFECTION IN—R. A. Wilson ... 53
PAEDIATRICS, NEO-NATAL, RECENT ADVANCES IN—Harold Stockton ... 55
PANCREATITIS, ACUTE—John A. Ganshorn ... 12
PELVIC INFLAMMATION, A CHANGED CONCEPT—Leigh Hunt ... 109
PHILPOTT, N. W.—Modern Trends in Obstetrics ... 88
PHYSIOTHERAPISTS & MASSAGE PRACTITIONERS ACT ... 213
PNEUMOTHORAX, SPONTANEOUS, TREATMENT OF AN UNUSUAL CASE OF—T. K. McLean ... 176
POLIOMYELITIS, ACUTE ANTERIOR—Stewart Murray ... 221
POW, C. G.—Polyposis of the Colon ... 178
PROVINCIAL BOARD OF HEALTH DIVISION OF V. D. CONTROL—
- Recent Developments in Venereal Disease Treatment ... 68, 93
- Cardiovascular Syphilis ... 210,263

R

RADIOACTIVE ISOTOPES IN BIOLOGY AND MEDICINE, THE USE OF—Simeon T. Cantril ... 152
RED EYE, ACUTE, DIFFERENTIAL DIAGNOSIS AND TREATMENT OF—A. J. Elliot 344
REFUGEE PHYSICIANS—A. D. Kelly ... 328
ROBERTSON, ROSS—Surgical Conditions of Heart and Great Vessels ... 130

S

ST. PAUL'S HOSPITAL—Case Reports ... 20
SAXTON, G. D.—Some Observations on Streptomycin ... 63
—Surgical Treatment of Pulmonary Tuberculosis ... 127
SMITH, CLEMENT A.—The Causes of Abdominal Pain in Infants and Children ... 302
—Physiological Peculiarities of Newborn Infants ... 307
—Diseases of the Newborn; Asphyxia, Atelectasis, Erythroblastosis ... 311
—Diseases of the Newborn; Diarrhea, Prematurity ... 316
STERILITY IN THE MALE—John Balfour ... 112
STERILITY IN PRIVATE PRACTICE—A. C. Frost and A. C. Gardner Frost ... 103
STREPTOMYCIN IN TUBERCULOSIS, SOME OBSERVATIONS ON—G. D. Saxton ... 63
STOCKTON, HAROLD—Recent Advances in Neo-Natal Paediatrics ... 55
STURGIS, CYRUS C.—Discussion of some Aspects of Leukemia, Infectious Mononucleosis and Agranulocytosis ... 277
SURGERY OR PROPYL THIOURACIL—Lyon H. Appleby ... 135

T

TETANUS—A Case Report—W. J. Fowler ... 236
THORACIC SURGERY—Symposium on ... 121
TUBERCULOSIS, PULMONARY, SURGICAL TREATMENT OF—G. D. Saxton ... 127
TURNER, EDWARD L.—Problems and Trends in Medical Education ... 29

V

VAGOTOMY—Lyon H. Appleby ... 84
VAGOTOMY—Roy Huggard ... 211
VANCOUVER GENERAL HOSPITAL—
- Case Reports ... 12, 44, 63, 66, 175, 176, 178, 236, 239, 272, 348

VANCOUVER MEDICAL ASSOCIATION—
- Annual Reports (1946-1947) ... 187
- History of—Dr. G. E. Kidd ... 5, 86, 101, 148, 195, 233, 264, 289
- Library ... 4, 28, 51, 74, 120, 144, 184, 218, 248, 289, 332
- New Members ... 29, 53
- Summer School ... 145, 229

VICKERS, K., and CHIVERS, N.—Progress in the Treatment of Meningitis ... 44
VICTORIA MEDICAL SOCIETY ... 11

W

WILSON, R. A.—A Modern Re-Emphasis of the Role of Infection in Paediatric Disease 53
WILSON, ROGER—Modern Gastroscopy and Gastric Disease ... 272

UNIVERSITY OF BRITISH COLUMBIA

Constant Carefulness

Only an understanding professional skill could maintain the confidence of the Medical Profession which we enjoy.

Phone MArine 4161

Leslie G. Henderson

Gibb G. Henderson

OPEN ALL NIGHT

GEORGIA PHARMACY
LIMITED

W. GEORGIA 777 STREET

Center & Hanna Ltd.

ESTABLISHED 1893

VANCOUVER, B. C.

North Vancouver, B. C.

Powell River, B. C.

Hollywood Sanitarium

Co. Limited

NEW WESTMINSTER, B. C.

★

For the treatment of

NEUROPSYCHIATRIC DISORDERS

★

Reference—B. C. Medical Association

★

For information apply to

MEDICAL SUPERINTENDENT, NEW WESTMINSTER, B. C.
NEW WESTMINSTER 288

or 721 MEDICAL-DENTAL BUILDING, VANCOUVER, B. C.

PACIFIC 7823 PACIFIC 8036

versity of British Columbia Librar
DUE DATE
SERIALS

670816

UNIVERSITY OF B.C. LIBRARY
3 9424 04406 382 1

~~216824~~

W1
VA625
V. 23.

WOODWARD LIBRARY
UNIVERSITY OF BRITISH COLUMBIA
VANCOUVER 8, CANADA