

**CELL AND MOLECULAR BIOLOGY IN HEREDITARY GINGIVAL
FIBROMATOSIS**

by

ANDREA CSISZAR

B.Sc., University of British Columbia, 1999
D.M.D., University of British Columbia, 2003

A THESIS SUBMITTED IN PARTIAL FULFILLMENT OF THE
REQUIREMENTS FOR THE DEGREE OF

MASTER OF SCIENCE

in

THE FACULTY OF GRADUATE STUDIES

(Dental Science)

THE UNIVERSITY OF BRITISH COLUMBIA

August 2006

© Andrea Csiszar, 2006

ABSTRACT

Gingival overgrowth, a potential side effect of medications i.e. nifedipine, cyclosporine, is also a characteristic feature of hereditary gingival fibromatosis (HGF). Autosomal dominant, non-syndromic HGF, the most common variant, has been localized to chromosomes 2p21-p22 (HGF1) (Hart *et al.*, 1998; Hart *et al.*, 2000; Hart *et al.*, 2002; Xiao *et al.*, 2000), 5q13-q22 (HGF2) (Xiao *et al.*, 2001) and 2p22.3-p23.3 (HGF3) (Ye *et al.*, 2005), suggesting genetic heterogeneity. Interestingly, one of these mutations results in constitutive activation of the signaling molecule SOS-1, which is a key regulator of cell function and gene expression. Clinical observations suggest that HGF starts at the interdental papilla area from where it expands to other areas of gingiva by a process that may resemble gingival wound healing. Since the molecular changes in HGF are largely unknown, we compared the expression of cell surface ($\alpha\text{v}\beta 6$ integrin), intracellular (SOS-1 and CK19) and extracellular matrix molecules (procollagen, FN-EDA, FN-EDB, tenascin-C, decorin, biglycan, fibromodulin, lumican) and growth factors (TGF- β and CTGF) involved in wound healing, in healthy and HGF marginal gingiva by immunohistochemical staining. We also analyzed the localization of these molecules in healthy interdental papilla. Results showed that the molecular phenotype of healthy marginal gingiva differs from that of healthy interdental papilla. Therefore, we compared the expression of target molecules in the same tissue locations (marginal gingiva) in healthy and HGF subjects. Expression of CK19 and $\alpha\text{v}\beta 6$ integrin was induced by epithelial cells in HGF samples, but they were not in healthy marginal gingiva. Furthermore, epithelial cells in HGF showed increased expression of biglycan, fibromodulin, lumican, TGF- $\beta_{1,2,3}$, CTGF and SOS-1 compared to healthy tissue.

Expression of biglycan, lumican, procollagen, FN-EDB and tenascin-C were also upregulated in the extracellular matrix in HGF. Compared to healthy tissues, cell associated staining for biglycan, fibromodulin, lumican, procollagen, FN-EDB, TGF- $\beta_{1,2,3}$, CTGF and SOS-1 was increased in HGF. The latter three molecules showed also spatiotemporally increased expression in gingival experimental wounds. The repertoire of molecules that are expressed in HGF in marginal gingiva is different from healthy marginal gingiva, but shows similarities to gingival wounds and healthy interdental papilla.

TABLE OF CONTENTS

Abstract	ii
Table of Contents	iv
List of Tables	vi
List of Figures	viii
Abbreviations	xv
Acknowledgements	xvi
1 Introduction	1
2 Review of the Literature	3
2.1 Clinical presentation and prevalence of HGF	3
2.2 Histological characteristics of HGF	5
2.3 Genetic characteristics of HGF	7
2.4 Son of sevenless 1 gene mutation and HGF	13
2.5 Pathogenesis of HGF	18
2.5.1 Phenotypically different fibroblast subpopulations	18
2.5.2 Proliferation of gingival fibroblasts	19
2.5.3 C-myc	20
2.5.4 Extracellular matrix molecules	21
2.5.5 Transforming Growth Factor- β and its receptors	22
2.5.6 Matrix metalloproteinases and tissue inhibitors of matrix metalloproteinases	24
2.5.7 Collagen phagocytosis	26
2.5.8 Fatty acid synthesis	26
2.5.9 Summary	27
2.6 HGF versus drug induced gingival overgrowth	27
2.7 Treatment of hereditary gingival fibromatosis	31
3 Aim of the Study	33

4	Materials and Methods	35
4.1	Gingival samples	35
4.2	Immunohistochemical staining	41
5	Results	44
5.1	Comparison of healthy marginal gingiva and interdental papilla	44
5.1.1	Characterization of the epithelium	45
5.1.2	Characterization of the connective tissue	48
5.1.3	Cell associated staining of target molecules in marginal gingiva and papilla	51
5.2	Comparison of marginal gingiva in health versus HGF	58
5.2.1	Characterization of the epithelium in health and HGF	59
5.2.2	Characterization of the connective tissue in health and HGF.....	62
5.2.3	Cell associated staining of target molecules in healthy and HGF marginal gingiva	65
5.3	Wound healing in palatal attached gingiva	71
6	Discussion	80
6.1	Comparative analysis of marginal gingiva and interdental papilla in health	80
6.2	Comparison of marginal gingiva in health and HGF	86
6.3	Comparison of HGF marginal gingiva and palatal attached gingival wounds	92
7	Conclusion and Future Directions	97
7.1	Conclusions	97
7.2	Future Directions	97
	Bibliography	99

LIST OF TABLES

Table 1	Genetic basis of hereditary gingival fibromatosis	12
Table 2	Patient characteristics	37
Table 3	Specifics of patient characteristics with HGF	38
Table 4	Specifics of control patient characteristics	39
Table 5	Antibodies used and their dilutions	43
Table 6	Relative immunostaining intensity in the epithelium of healthy marginal gingiva and healthy papilla	47
Table 7	Relative immunostaining intensity in the connective tissue extracellular matrix in healthy marginal gingiva and healthy papilla	50
Table 8	Relative staining intensity of fibroblasts and blood vessels in healthy marginal gingiva and interdental papilla	52
Table 9	Summary of differences between healthy and HGF marginal epithelium	61
Table 10	Summary of differences between healthy and HGF marginal connective tissue	64
Table 11	Relative staining intensity of fibroblasts and blood vessels in health and HGF	66

Table 12	Summary of expression of molecules of interest in the interdental papilla relative to marginal gingiva in health	85
Table 13	Summary of expression of molecules of interest in HGF marginal gingiva relative to healthy marginal gingiva	91
Table 14	Major differences in HGF and palatal gingival wounds compared to healthy marginal gingiva	94

LIST OF FIGURES

- Figure 1** Structure of wild type and mutant SOS-1 present in HGF1 (A) and its function in activation of Ras and Rac pathways (B). Figure (A) is a modification of that presented by Hart (2002). DH (Dbl homology) or otherwise known as RhoGEF, is a guanine nucleotide exchange factor for the Rho-Rac/cdc42-like GTPase region, while PH is a pleckstrin homology domain. RasGEFN and RasGEF are guanine nucleotide exchange factors for Ras-like GTPase, the former being an N-terminal motif. RasGEF catalytic domains are also referred to as CDC25. PRGB, the proline rich Grbs-binding domain, contains four proline-rich SH3 binding sites (P) and five phosphorylated serine residues (S). In HGF1, there is a single cytosine insertion at codon 1083 (proline) (*) in exon 21 that results in a frame shift mutation and an early termination of the protein. Approximately 20% of the SOS-1 gene is deleted, including domains responsible for maintaining the protein in a down-regulated state. The mutant protein also has a 22-amino acid missense addition at the COOH terminal (diamond pattern). Figure (B) illustrates the role of SOS-1 in growth factor signaling and cytoskeletal organization via Ras and Rac, respectively. SOS-Grb2 and SOS-E3b1-Eps8 complexes, as well as Ras and Rac each of which are bound to GDP (inactive state), predominate in the cytoplasm of resting cells. Binding of a ligand such as epidermal growth factor, fibroblast growth factor, insulin, platelet derived growth factor or integrins to receptor tyrosine kinase (RTK), results in dimerization of RTK and phosphorylation of tyrosine residues on the receptor. The SH2 domain on Grb2 binds to these phosphorylated residues, activating SOS-1, which is bound to Grb2. In turn, this causes Ras to release GDP (inactive) in exchange for GTP (active). SOS-E3b1-Eps8 complex also moves toward actin filaments, which then activate Rac17

Figure 2	Clinical appearance of gingiva in health (A) versus hereditary gingival fibromatosis (B). Schematic representations are provided of the locations where biopsy samples were obtained from the marginal gingiva (A and B) and interdental papilla (A) in both health (A) and disease (B)40
Figure 3	Hematoxylin & Eosin staining of the marginal gingiva (A and B) and interdental papilla (C and D) from healthy tissues (A and C) and hereditary gingival fibromatosis (B and D). In hereditary gingival fibromatosis, epithelial rete ridges are elongated in the marginal gingiva (B) and the interdental papilla (D). E = epithelium; CT = connective tissue53
Figure 4	Immunostaining of cytokeratin 19 (CK19; A and B) and $\alpha\text{v}\beta 6$ integrin (C and D) in healthy marginal gingiva (A and C) and interdental papilla (B and D). Healthy marginal gingiva does not express CK19 (A) or $\alpha\text{v}\beta 6$ integrin (C); however, in healthy papilla, CK19 (B) and $\alpha\text{v}\beta 6$ integrin (D) are expressed in epithelial basal and suprabasal cells. For both CK19 (B) and $\alpha\text{v}\beta 6$ integrin (D), strongest expression is at tips of rete ridges. E = epithelium; CT = connective tissue. Bar 100 μm54
Figure 5	Immunolocalization of decorin (A and B), biglycan (C and D), fibromodulin (E and F) and lumican (G and H) in healthy marginal gingiva (A, C, E and G) and interdental papilla (B, D, F and H). There is stronger expression of biglycan, fibromodulin and lumican in the epithelium of the papilla (D, F and H), compared to marginal gingiva (C, E and G). Staining intensity for decorin, biglycan and fibromodulin is stronger in the papilla (B, D and F). Lumican is more strongly expressed in the epithelium of the papilla (H), but the connective tissue of the marginal gingiva (G). Blood vessels in the papilla are strongly positive for biglycan (D). E = epithelium; CT = connective tissue. Bar 100 μm55

Figure 6 Immunohistochemical staining of procollagen (A and B), fibronectin-EDA (FN-EDA; C and D), fibronectin-EDB (FN-EDB; E and F) and tenascin-C (G and H) in healthy marginal gingiva (A, C, E and G) and healthy papilla (B, D, F and H). Inserts in E and F show higher magnification from connective tissue. Expression of procollagen, FN-EDA, FN-EDB and Tenascin-C is stronger in the connective tissue of the interdental papilla (B, D, F and H) than in the marginal gingiva (A, C, E and G). Fibroblasts in the papilla stained stronger for procollagen and FN-EDA (B and D) than in the marginal gingiva (A and B). Epithelial, connective tissue or cell associated staining with FN-EDB is not observed in the marginal gingiva (E). However, fibroblasts and blood vessels with immunoreactivity to FN-EDB are present in the papilla (F insert). Tenascin-C is localized to the basement membrane zone in the marginal gingiva (G), but with the exception of a thin region between the basement membrane zone and deep connective tissue, it is expressed at all levels of the papillary connective tissue (H). E = epithelium; CT = connective tissue. Bar 100 μ m56

Figure 7 Localization of TGF- β (A-F), connective tissue growth factor (CTGF; G-L) and SOS-1 (M-R) in healthy marginal gingiva (A, B, E, G, I, J, M, O and P) and interdental papilla (C, D, F, H, K, L, N, Q and R). There are two different patterns of TGF- β expression that can be found in the epithelium of marginal gingiva (A and B) and interdental papilla (C and D). TGF- β may be expressed around basal cells only, or conversely in the cell membranes facing the basement membrane and suprabasal layers, with scant expression in other areas of basal cells. However, the overall staining intensity is stronger in the papilla (C and D). The papilla also has relatively more fibroblasts and blood vessels with immunoreactivity to TGF- β (F). Expression of CTGF is stronger in basal cells of the marginal gingiva (G and I); suprabasal staining is also evident in the papilla (H and K). Compared to marginal gingiva (J), staining intensity of fibroblasts for

CTGF is stronger in the papilla (L). SOS-1 expression is limited to basal cells in marginal gingiva (M and O). All epithelial layers express SOS-1 in the papilla (N and Q). Cell associated staining with SOS-1 is stronger in the papilla (R) than the marginal gingiva (P). E = epithelium; CT = connective tissue. Bar 100µm57

Figure 8 Expression of cytokeratin 19 (CK19; A-C) and $\alpha\beta 6$ integrin (D and E) in marginal gingiva in health (A and D) and hereditary gingival fibromatosis (B, C and E). Insert in E shows a higher magnification of a rete ridge and connective tissue. CK19 is expressed in all HGF samples (B and C), although in some only isolated basal cells are positive (B). In HGF, $\alpha\beta 6$ integrin shows localized expression notably at tips of rete pegs (E). None of the healthy marginal samples had CK19 or $\alpha\beta 6$ integrin expression (A and D). E = epithelium; CT = connective tissue. Bar 100µm67

Figure 9 Localization of decorin (A and B), biglycan (C and D), fibromodulin (E and F) and lumican (G and H) in marginal gingiva in health (A, C, E and G) and hereditary gingival fibromatosis (B, D, F and H). Inserts in C and D show a higher magnification from connective tissue. Epithelial expression of biglycan, fibromodulin and lumican is stronger in HGF (D, F and H) than in health (C, E and G). Staining intensity for biglycan and lumican was also stronger in connective tissues in HGF (D and H). Blood vessels and fibroblasts stained stronger for fibromodulin and lumican in HGF (F and H). E = epithelium; CT = connective tissue. Bar 100µm68

Figure 10 Immunostaining of procollagen (A and B), fibronectin-EDB (FN-EDB; C and D) and tenascin-C (E and F) in marginal gingiva in health (A, C and E) and hereditary gingival fibromatosis (B, D and F). Inserts in C and D show a higher magnification from connective tissue. There are relatively more fibroblasts with immunoreactivity to procollagen in HGF (B) than

health (A). Although FN-EDB is not evident in healthy marginal tissues (C), it is strongly expressed in the basement membrane zone and connective tissue in HGF (D). Fibroblasts and blood vessels with immunoreactivity to FN-EDB (D insert) are abundant in HGF. Staining of collagen fibers with tenascin-C spans the entire connective tissue in HGF (F). E = epithelium; CT = connective tissue. Bar 100µm.....69

Figure 11 Immunohistochemical staining of TGF-β (A and B), CTGF (C and D) and SOS-1 (E and F) in marginal gingiva in health (A, C and E) and hereditary gingival fibromatosis (B, D and F). Inserts in A-F show higher magnification from connective tissue. All HGF samples are homogeneous for the TGF-β staining pattern displayed (B) and expression is stronger than that in healthy marginal gingiva (A). CTGF and SOS-1 are more strongly expressed in the suprabasal layers in HGF (D and F respectively) than in health (C and E respectively). Expression of TGF-β, CTGF and SOS-1 in fibroblasts and blood vessels is stronger in HGF (B, D and F inserts) than health (A, C and E inserts). There were no fibroblasts positive for TGF-β in health (A insert). E = epithelium; CT = connective tissue. Bar 100µm70

Figure 12 Baseline palatal gingiva - Day 0 (Control). Expression pattern of TGF-β (A and D), CTGF (B and E) and SOS-1 (C and F) in non-wounded palatal attached gingiva is similar to healthy marginal gingiva. D, E and F: Arrowheads indicate staining at the basal cell membrane facing the basement membrane. A, B and C: Arrows indicate blood vessels. E = epithelium; CT = connective tissue. Bar 100µm74

Figure 13 Expression pattern of TGF-β (A, D and G), CTGF (B, E and H) and SOS-1 (C, F and I) in palatal attached gingiva 3 days after wounding. A-F: Arrows indicate the wound edge. E and F: Arrowheads indicate localization of strong immunoreactivity at the epithelial cells. TGF-β (A

and D arrows) and SOS-1 (C and F arrows) are expressed at the migrating epithelial front and at the border of the connective tissue and fibrin clot (G and I, respectively). CTGF expression is somewhat upregulated in the connective tissue of the wound margins (B and E arrows). E = epithelium; CT = connective tissue; FC = fibrin clot. Bar 100 μ m75

Figure 14 Localization of TGF- β (A, D and G), CTGF (B, E and H) and SOS-1 (C, F and I) in palatal attached gingiva on day 7 post wounding. A-C: Arrows indicate the wound edge. A-F: Arrowheads indicate staining at basal epithelial cells. All three molecules are expressed in the cell membranes at the basal cells (A-F arrowheads). There is strong expression of TGF- β (G) and SOS-1 (I) at the interface between the connective tissue and granulation tissue. E = epithelium; CT = connective tissue; GT = granulation tissue. Bar 100 μ m76

Figure 15 Expression pattern of TGF- β (A, D, G and J), CTGF (B, E, H and K) and SOS-1 (C, F, I and L) in palatal attached gingiva 14 days post wounding. A-C: Arrows indicate the wound edge. TGF- β expression is nearly absent from the wound epithelium (A) and wound connective tissue (D). There is increased expression of CTGF in the wound connective tissue (E). Cell membranes facing the basement membrane are stained with CTGF (E) and SOS-1 (F), but not TGF- β (A). E = epithelium; CT = connective tissue; WCT = wound connective tissue. Bar 100 μ m77

Figure 16 Expression pattern of TGF- β (A, D, G and J), CTGF (B, E, H and K) and SOS-1 (C, F, I and L) in palatal gingiva 28 days after wounding. A, C, D and F: Arrowheads indicate strong staining at the basal cells. Expression of TGF- β (A and D) and SOS-1 (C and F) is increased in the cell membranes facing the basement membrane in the wound epithelium. CTGF (K) and SOS-1 (L) expression is abundant in fibroblasts of the

wound connective tissue. E = epithelium; CT = connective tissue; WCT = wound connective tissue. Bar 100 μ m78

Figure 17 Localization of TGF- β (A, D, G and J), CTGF (B, E, H and K) and SOS-1 (C, F, I and L) in palatal gingiva 60 days post wounding. G-I: Arrows indicate blood vessels. D and F: Arrowheads indicate strong staining at basal cells. Expression of TGF- β (A) and SOS-1 (C) are normalized in the epithelium. Wound connective tissue had an abundance of blood vessels and fibroblasts immunoreactive for CTGF (E, H and K) and SOS-1 (F, I and L). E = epithelium; CT = connective tissue; WCT = wound connective tissue. Bar 100 μ m79

Figure 18. Summary of wound healing events in palatal attached gingiva. This is a relative graph with a non-linear scale that does not compare levels of molecules with respect to one another, but rather each molecule to itself over time. This graph diagrammatically demonstrates the general trends in TGF- β , CTGF and SOS-1 in wound healing through time. SOS-1 is increased early in wound healing and remains elevated even at 60 days post wounding. On the other hand, there is a switch from TGF- β expression in early wound healing, to CTGF expression in late wound healing96

ABBREVIATIONS

BV	blood vessel
CK	cytokeratin
CTGF	connective tissue growth factor
DCT	deep connective tissue
DIGO	drug induced gingival overgrowth
ECM	extracellular matrix
EGF	epidermal growth factor
EGFr	epidermal growth factor receptor
ELISA	enzyme-linked immunosorbent assay
FBL	fibroblast
HGF	hereditary gingival fibromatosis
MAPK	mitogen activated protein kinase
PCNA	proliferating cell nuclear antigen
PDGF	platelet derived growth factor
RT-PCR	reverse transcriptase polymerase chain reaction
RTK	receptor tyrosine kinase
SB	stratum basale
SG	stratum granulosum
SS	stratum spinosum
SOS-1	son-of-sevenless-1
TGF- β	transforming growth factor $-\beta$

ACKNOWLEDGEMENTS

I would like to thank Dr. Lari Hakkinen for the countless hours of guidance and expertise that he has provided throughout the course of my studies. Special thanks to Mr. Cristian Sperantia for expert technical assistance and Dr. John Matthews from the University of Birmingham, U.K. and Dr. Hannu Larjava and Dr. Collin Wiebe from the University of British Columbia, Canada, for donating biopsy samples from patients with hereditary gingival fibromatosis. Both hereditary gingival fibromatosis and wound healing components of this study were supported by a grant from Canadian Institute for Health Research (CIHR).

1 INTRODUCTION

Gingival fibromatosis, otherwise known as gingival hyperplasia or gingival overgrowth, may occur as a result of systemic medications, systemic diseases or genetics. Medications such as cyclosporin A, phenytoin and nifedipine (Hassell and Hefti, 1991) are the most common cause of gingival overgrowth. Cyclosporin A is used for the treatment of organ transplants and autoimmune diseases, phenytoin for seizure disorders, and nifedipine for angina and hypertension. The prevalence of gingival overgrowth ranges from 8-70% with cyclosporine A (Seymour and Heasman, 1988), 10-50% with phenytoin (Kataoka *et al.*, 2005; Nishikawa *et al.*, 1996) and 6.4%-44% with nifedipine (Ellis *et al.*, 1999; Nery *et al.*, 1995). Genetic polymorphisms may be the reason for differential responses to such medications. Both genetic and phenotypic polymorphisms have been identified in xenobiotic metabolizing enzymes, which predispose some patients to the effects of certain medications (Daly *et al.*, 1993). Gingival overgrowth can also be a manifestation of neurofibromatosis I, leukemic infiltrates, Hodgkin's lymphoma, Sweet-like syndrome or Schinzel-Giedion syndrome (Doufexi *et al.*, 2005). When the overgrowth has a genetic origin, the disorder is referred to as hereditary gingival fibromatosis (HGF), a term that is synonymous with idiopathic gingival overgrowth or hereditary gingival overgrowth. The prevalence of HGF is 1 in 750,000 people (Fletcher, 1966). Although genetic factors appear to play a significant role in many types of gingival fibromatosis, the underlying genes responsible for these disorders are unknown.

HGF can occur as an isolated disease or as part of a syndrome. Both autosomal dominant and recessive forms of this disorder have been previously described; however, its incidence and severity depend on the penetrance of the mutated gene. The autosomal

dominant form may be localized to chromosome 2p21-p22 (HGF1) (Hart *et al.*, 1998), chromosome 5q13-q22 (HGF2) (Xiao *et al.*, 2001) or chromosome 2p22.3-p23.3 (HGF3) (Ye *et al.*, 2005). A mutation in the Son of Sevenless 1 (SOS-1) gene may be the underlying etiology for HGF1.

Clinically, gingival overgrowth in HGF coincides with the eruption of the permanent or deciduous dentition. Its evolution is similar to that of drug induced gingival overgrowth, where early changes involve enlargement of the interdental papilla; the marginal and attached gingiva may also become involved with disease progression (Seymour *et al.*, 1996). To our knowledge, there have been no clinical studies that delineated the precise anatomic origin for gingival overgrowth in HGF. Histologically, HGF resembles drug induced gingival overgrowth. The epithelium is comprised of elongated rete pegs and collagen production by fibroblasts is upregulated in the connective tissue. However, the precise mechanism underlying the disease is unknown.

2 Review of the Literature

2.1 Clinical presentation and prevalence of HGF

HGF is a rare condition, with a prevalence of 1 in 750,000 people (Fletcher, 1966). Males and females are affected equally (Kelekis-Cholakis *et al.*, 2002). Its characteristic features include gingival enlargement that in severe cases may cover the crowns of teeth. Unlike medication induced gingival overgrowth, that which occurs in HGF is not influenced by the presence of plaque. HGF can occur as an isolated disorder or as a component of a syndrome (Gorlin, 1990). According to Hart (Hart *et al.*, 1998), the most common syndromic forms occur with hypertrichosis (Horning *et al.*, 1985), epilepsy (Ramon *et al.*, 1967) and mental retardation (Araiche and Brode, 1959). Other syndromes associated with gingival fibromatosis include sensorineural hearing loss, juvenile hyaline fibromatosis; Rutherford syndrome (corneal dystrophy); Zimmerman-Laband syndrome (ear, nose, bone and nail defects); Cross syndrome (microphthalmia, mental retardation, athetosis and hypopigmentation); Ramon syndrome (cherubism, hypertrichosis, mental and somatic retardation and epilepsy); and growth hormone deficiency (Gorlin, 1990; Hart *et al.*, 1998; Lynch, 1994). HGF has also been associated with hearing loss and supernumerary teeth (Wynne *et al.*, 1995), histopathologic premalignancy characterized with epithelial dysplasia (Redman *et al.*, 1985) and generalized aggressive periodontitis (Casavecchia *et al.*, 2004). It is not known whether the coexistence of HGF and generalized aggressive periodontitis represents a new syndromic form of the disease. Although non-syndromic forms of HGF can be associated with a mutation in the SOS-1 gene (Hart *et al.*, 2002), mutation in other genes may also be an underlying etiology (Xiao *et al.*, 2001) (Table 1).

Hereditary gingival fibromatosis is characterized by a slowly progressive, benign, localized or generalized enlargement of maxillary and/or mandibular keratinized gingiva. Enlarged gingiva is non-hemorrhagic and consists of dense and resilient fibrous tissue that feels firm and nodular on palpation; exaggerated stippling may be present (Kelekis-Cholakis *et al.*, 2002). Although the alveolar bone is usually unaffected, gingival excess results in pseudopocketing and a compromised periodontal situation due to difficulties in performing daily oral hygiene. The gingival tissues may be normal in color or erythematous if they are inflamed.

Gingival enlargement is classified on the basis of the degree of overgrowth (Bokenkamp *et al.*, 1994): grade 0 (no signs of gingival enlargement); grade I (enlargement of the interdental papilla only); grade II (enlargement of the papilla and marginal gingiva); grade III (enlargement covering three quarters or more of the crown). Localized forms of gingival overgrowth are more nodular and generally affect the maxillary tuberosities and the labial gingiva around the mandibular molars (Kelekis-Cholakis *et al.*, 2002). However, the symmetric generalized form of the disorder that affects both the labial, lingual and palatal gingiva, is the most common form (Baptista, 2002).

The onset of gingival hyperplasia usually coincides with the eruption of the permanent incisors (approximately age 10), or at times, with the eruption of the primary dentition. It can also be present at birth; however, this occurs very rarely (Anderson *et al.*, 1969). Since gingival overgrowth has not been reported in edentulous HGF patients or in newborns since the initial report by Anderson (Anderson *et al.*, 1969), it is likely that the presence of dentition may be necessary for overgrowth to develop. To date, there are no

studies that describe the precise anatomic origin e.g. interdental papilla versus marginal gingiva, of the overgrowth. Gingival overgrowth may cover teeth to various degrees, resulting in functional and esthetic concerns. Excess fibrous tissue often creates diastemas, may impede or delay tooth eruption (Shafer, 1983a) and may create changes in one's facial appearance as a result of lip protrusion. Severe hyperplasia can result in crowding of the tongue, speech impediments, difficulty with mastication and even prevent normal closure of lips (Lynch, 1994).

2.2 Histological characteristics of HGF

The precise cellular mechanisms in HGF are currently unknown; however, reports claim a difference exists between the epithelium and connective tissues of healthy patients versus those with HGF. Histologically, HGF is characterized by moderate hyperplasia of a dense, hyperkeratotic epithelium with elongated rete pegs (Doufexi *et al.*, 2005; Lindhe, 2003). The mean height of rete pegs are greater in HGF than in health; however, the number of rete pegs and their mean area are comparable between health and disease (Araujo *et al.*, 2003). In this immunohistological study of non-inflamed healthy and HGF gingival biopsies, epidermal growth factor (EGF) and its receptor (EGFr) were expressed with a higher frequency on immunostaining at the tips of epithelial rete pegs in HGF than healthy samples. In addition, epithelial cell proliferation, as measured by proliferating cell nuclear antigen (PCNA) immunostaining, was positively correlated with EGF or EGFr localization in the tips of rete pegs in HGF tissues (Araujo *et al.*, 2003). The authors hypothesized that over-expression of EGF or EGFr at the tips of rete pegs in HGF may have a stimulatory effect on epithelial cell proliferation, resulting in deep rete pegs that extend into the underlying stroma. However, the fact that EGF and EGFr expression

is higher in health than HGF when all epithelial layers are taken into account, yet their localization is not associated with epithelial cell proliferation remains a mystery. Epithelial hyperplasia has also been reported as a consequence of acanthosis (Farrer-Brown *et al.*, 1972; Raeste *et al.*, 1978); however, this was only found in areas of chronic inflammation in HGF.

Connective tissues in HGF are abundant in collagen, but have relatively few fibroblasts and scarce blood vessels (Baptista, 2002; Doufexi *et al.*, 2005; Hart *et al.*, 2000). However, neurovascular bundles were well represented in a 13-year-old girl with HGF (Kelekis-Cholakis *et al.*, 2002). The high ratio of collagen bundles to fibroblasts seen in HGF resemble those seen in keloids (Coletta *et al.*, 1999; McCulloch and Knowles, 1993; Ramon *et al.*, 1967; Tipton *et al.*, 1997). Enlarged fibroblasts may alternate with finer collagen fibrils, resulting in collagen bundles speckled with small, dark fusiform nuclei of fibroblastic cells with scanty cytoplasm (Kelekis-Cholakis *et al.*, 2002). Dense collagen bundles may alternate with finer collagen fibrils (Kelekis-Cholakis *et al.*, 2002). The orientation of collagen bundles may be parallel to one another, reaching the subepithelial connective tissue (Casavecchia *et al.*, 2004), as well as in multiple directions (Kelekis-Cholakis *et al.*, 2002). Although a rare finding, small osseous calcifications may also be present in the connective tissue (Gunhan *et al.*, 1995). Local accumulation of inflammatory cells can be found in cases where pseudopocketing resulted in plaque accumulation and consequently inflammation (Shafer, 1983a).

Gingiva in both HGF and DIGO can be characterized as fibroepithelial in nature. They share the common characteristics of elongated rete pegs, parakeratinized epithelium and

connective tissues laden with increased extracellular matrix (Wright, 2001). As a result of the inconsistencies in the literature about the cellular and molecular mechanisms of HGF, histomorphometric analysis can only be used as an adjunct in the diagnosis of this condition. Although histology can at times differentiate this condition from other genetically determined gingival enlargements, in general, histological features are non-specific and a definitive diagnosis is based on history and clinical examination.

2.3 Genetic characteristics of HGF

Large cohorts with HGF have been extensively studied in an effort to determine the genetic basis of the disease. HGF can occur as an isolated disorder (Bozzo *et al.*, 1994) or it may be part of a syndrome (Wynne *et al.*, 1995). The mode of inheritance for HGF is thought to be autosomal dominant; however, autosomal recessive patterns have also been described (Singer *et al.*, 1993). At least three distinct loci appear to be responsible for the autosomal dominant variant, highlighting the genetic heterogeneity of this disorder (Table 1). A locus has been mapped to a region on chromosome 2 (Hart *et al.*, 1998; Xiao *et al.*, 2000); however, at least two genetically distinct loci appear to be responsible for this type of HGF. These were found to be 2p21 (Fryns, 1996; Hart *et al.*, 1998) and 2p13 (Shashi *et al.*, 1999). While HGF1 or GINGF1 has been localized to chromosome 2p21-p22, an area that codes for a guanine nucleotide-exchange factor (SOS-1) (Hart *et al.*, 1998; Hart *et al.*, 2002), a second gene, HGF2 or GINGF2, has been identified on chromosome 5q13-q22 (Xiao *et al.*, 2001). Recently, a novel locus for autosomal dominant HGF, called HGF3 or GINGF3, was mapped to chromosome 2p22.3-p23.3; however, the SOS-1 gene was genetically excluded outside this critical area (Ye *et al.*, 2005).

In a study conducted by Hart (Hart *et al.*, 1998), a three-generation Brazilian family segregating for HGF was used to demonstrate an underlying genetic basis for the disorder. Twelve of the 32 identified family members were affected with HGF. Hearing loss, epilepsy, hypertrichosis, mental retardation or other syndromes were not associated with any of the cases. Gingival fibromatosis was observed in all generations, included male-to-male transmission and affected both genders equally. HGF was found to segregate as a highly penetrant autosomal dominant trait in this family. Using a genome-wide search strategy, HGF phenotype was genetically linked to polymorphic markers in the 37-cM genetic region of chromosome 2p21-p22 bounded by the loci D2S1788 and D2S441. On the basis of the prior study (Hart *et al.*, 1998), and those conducted by Fryns (1996) and Xiao (2000), it is thought that a common gene locus on chromosome 2p is at least partially involved in HGF. In his studies of an individual with HGF and mental retardation, Fryns found a partial duplication of chromosome 2p13-p21, a region that contains the HGF candidate region identified by Hart (1998). On the other hand, Xiao (2000) studied four Chinese families with HGF with an autosomal dominant pattern of inheritance. Affected family members were not exposed to medications with a known association to gingival overgrowth, nor did they display signs of deafness, hypertrichosis or distinctive faces. By employing genomic DNA analysis, a dominant HGF locus was mapped to a region defined by D2S352 and D2S2163. This locus, which was at an 8.7-cM region on 2p21, overlapped the HGF1 locus region reported by Hart (Hart *et al.*, 1998), suggesting a common HGF gene between the present Chinese and the Brazilian families. However, in contrast to the Brazilian family where recombination suppression was found between D2S1788 and D2S441 (Hart *et al.*, 1998), the present study did not support this finding.

To determine the generality of the gene locus for HGF that has been previously localized to chromosome 2p21-p22 (Hart *et al.*, 1998), Hart (2000) examined 34 members (15 males, 19 females) of another Brazilian family with autosomal dominant HGF, of whom 17 were affected (7 males, 10 females). To determine the genetic heterogeneity for HGF, linkage was tested with 9 DNA-markers. Although in the previous study (Hart *et al.*, 1998) evidence favored linkage of HGF with polymorphic markers, the current family showed evidence against such linkage (Hart *et al.*, 2000). This heterogeneity was found to be statistically significant. Therefore, at least two genetically distinct loci can be implicated in the development of autosomal-dominant HGF.

In a subsequent study, Hart (2002) attempted to identify the gene for HGF1 by correlating clinical examinations with blood analysis in 80 members of a multigenerational Brazilian family (n=92). Thirty-eight individuals were diagnosed with isolated, non-syndromic HGF, while 40 were unaffected. A fraction of this cohort comprised the original study group (Hart *et al.*, 1998) in which HGF1 was linked to chromosome 2p21. In the present study, HGF1 was refined to a candidate interval of approximately 2.3 Mb on chromosome 2p21-p22. Upon sequencing the 16 genes found in this region, a mutation in the *Son of sevenless-1* (SOS-1) gene was identified in affected family members. It is believed that an insertion mutation, namely the interposition of a cytosine between nucleotides 126,142 and 126,143 in codon 1083 of the SOS-1 gene, causes HGF1. This insertion mutation produces a frameshift and thus an early stop codon, affecting the subsequent 22 amino acids. Early termination eliminates the proline-rich region containing the docking site for the SH3 domain of adaptor proteins Grb2 and E3b1 and the five MAP kinase phosphorylation sites that

under normal circumstances are found in the carboxyl-terminal region of SOS-1 (Figure 1). The mutated protein is composed of the original wild-type SOS-1 for the N-terminal amino acids that is fused to the new, shortened carboxyl terminus. Although a mutation in SOS-1 may cause HGF1, this disorder has also been linked to a region on chromosome 2 that does not involve the SOS-1 gene. Through the use of clinical examinations, genotyping and linkage analysis of a five generation Chinese family with autosomal dominant, non-syndromic HGF, Ye (Ye *et al.*, 2005) found a novel locus for HGF, called HGF3 (GINGF3) that was mapped to chromosome 2p22.3-p23.3. However, the SOS-1 gene was genetically excluded outside the critical interval (Ye *et al.*, 2005).

HGF has also been linked to a different chromosome, as was the case in a four-generation Chinese family (n=20) with isolated autosomal dominant variant of the disorder (Xiao *et al.*, 2001). Apart from gingival manifestations that surfaced one year after birth (n=10), participants were otherwise mentally and systemically healthy and were not exposed to medications associated with gingival overgrowth. Twenty family members were genotyped, and linkage and haplotype analyses were conducted thereafter. Compared to participants from the author's previous study (Xiao *et al.*, 2000), the present cohort did not show linkage with 2p21, indicating that yet another gene may be involved in HGF. Using genomic analyses, a new locus, HGF2 (GINGF2), was localized to chromosome 5q13-q22 defined by D5S1491 and D5S1453. Because this newly defined region for HGF2 (5q13-q22) contains calcium/calmodulin dependent protein kinase IV (CAMK4) it can be hypothesized that this gene is also important in the pathogenesis of drug induced gingival overgrowth. HGF, as well as nifedipine and cyclosporin induced gingival overgrowth, are phenotypically similar. According to Kasahara (1999), cyclosporin A

can increase the phosphorylation and the activity of this kinase. CAMK4 may be another important signaling molecule that links HGF to drug induced gingival overgrowth.

Linkage to both HGF1 and HGF2 loci have been examined, but excluded in an Italian family (7 affected; 6 unaffected) with three-generations of HGF (Research Letter, 2002). Gingival hyperplasia was ubiquitous, synophris (confluent eyebrows) was more prevalent in males and hypertrichosis was present in only 2 males. Certain characteristics may have variable expression in autosomal dominant conditions. For example, hypertrichosis was less marked amongst females in the present study. Since synophris and hypertrichosis were absent in unaffected members, HGF with hypertrichosis was a likely diagnosis. Since hypertrichosis was not evident in HGF-1 and HGF-2 linked families studied by Xiao (Xiao *et al.*, 2000) and Hart (Hart *et al.*, 2002), isolated gingival hyperplasia and HGF associated with hypertrichosis may be genetically distinct entities. Exclusion of linkage to HGF1 and HGF2 in this family implies that the HGF is more genetically heterogeneous than previously believed.

Table 1. Genetic basis of hereditary gingival fibromatosis.

Type	Mode of Inheritance	Genetics	Locus	Mutation	Reference
Isolated	AD	2p21-p22	HGF1	SOS-1	(Hart <i>et al.</i> , 1998; Hart <i>et al.</i> , 2000; Hart <i>et al.</i> , 2002; Shashi <i>et al.</i> , 1999; Xiao <i>et al.</i> , 2000)
Isolated	AD	2p22.3-p23.3	HGF3	Unidentified	(Ye <i>et al.</i> , 2005)
Isolated	AD	5q13-q22	HGF2	Unidentified	(Xiao <i>et al.</i> , 2001)
Syndromic	AR	8	-	-	(Ramon <i>et al.</i> , 1967)
Syndromic	-	2p13-p21	-	Partial duplication	(Fryns, 1996; Shashi <i>et al.</i> , 1999)
Syndromic	AR	-	-	-	(Goldblatt and Singer, 1992; Singer <i>et al.</i> , 1993)
Isolated	AD	-	-	-	(Bozzo <i>et al.</i> , 1994)
Syndromic	AR	-	-	Unidentified	(Singer <i>et al.</i> , 1993)
Syndromic	-	7q	-	Interstitial deletion	(Morey and Higgins, 1990)
Syndromic	De novo	14q22-q32	-	Duplication	(Rivera <i>et al.</i> , 1992)
Syndromic	XL AD/AR	Xq24-q27.1	-	-	(Macias-Flores <i>et al.</i> , 1984)

AD = autosomal dominant

AR = autosomal recessive

XL = X-linked

2.4 Son-of-Sevenless One Gene Mutation and HGF

Son of sevenless (SOS-1) protein is a bifunctional guanine nucleotide exchange factor (GEF) for Ras and Rac, that in humans has functional domains including SH3-binding sites and mitogen-activated protein (MAP) kinase phosphorylation sites (Hart *et al.*, 2002) (Figure 1). SOS-1 is involved in growth factor signaling via Ras and cytoskeletal organization via Rac. Whether this protein will function as a Ras or Rac exchange factor is dictated by its COOH terminal region that contains SH3 domains (Nimnual and Barsagi, 2002). SOS-Grb2 complexes have an exchange activity only toward Ras, while SOS-E3b1-Eps8 complexes are specific for Rac (Innocenti *et al.*, 2002). In resting cells, the former are much more abundant than the latter (Innocenti *et al.*, 2002). The preferential binding of SOS with Grb2 may be attributed to a more stable complex or to the fact that Grb2 molecules may be more readily available.

SOS mediates coupling of receptor tyrosine kinase to Ras activation (Corbalan-Garcia *et al.*, 1996), which is then involved in signal transduction. Signal transduction commences when a ligand binds to a cell-surface tyrosine kinase receptor resulting in phosphorylation of the receptor's cytoplasmic domain. Phosphorylation results in recruitment of adapter proteins, Grb2 and Shc, which in turn bind SOS-1 to the membrane receptor (Trackman and Kantarci, 2004). SOS activates Ras indirectly by facilitating the exchange of GTP for GDP on Ras (Shapiro, 2002). When bound to GDP Ras is inactive; however, binding to GTP leads to its activation and hence stimulation of downstream phosphatidylinositol-3 kinase, MAP kinase family and *Rho*-proteins. These molecules control transcription factors and co-activators that regulate gene expression for proliferation and differentiation in different cell types (Shapiro, 2002).

Rac plays a central role in cytoskeletal organization e.g. actin remodeling. Rac activation corresponds with over expression of the DH (homology to Db1) domain of SOS (Nimnual *et al.*, 1998), as well as a complex formed between SOS-E3b1-Eps8 (Scita *et al.*, 1999), both of which result in an increased rate of guanine nucleotide exchange. However, Eps8 is believed to be directly responsible for the SOS-dependent activation of Rac (Nimnual and Bar-Sagi, 2002). As a result of the direct interaction found between Eps8 and F-actin in vivo and in vitro (Nimnual and Bar-Sagi, 2002), it is thought that localization of SOS-E3b1-Eps8 to areas of active actin remodeling may localize Rac activation to areas of actin cytoskeleton network (Nimnual and Bar-Sagi, 2002). Hence, cells have two major signaling pathways, Rac and Ras, which are both regulated by SOS-1 and can function together.

Genetic linkage studies in humans localized a gene for HGF1 to a genetic interval containing the SOS-1 gene locus (Hart *et al.*, 2002). These individuals have a single-cytosine insertion in exon 21 of the SOS-1 gene, leading to a frame shift mutation and an early termination of the protein. This mutation results in ~20% of the SOS-1 gene being deleted, including domains that are responsible for maintaining the protein in a down-regulated state; thus, the shortened protein is thought to have enhanced activity (Hart *et al.*, 2002) (Figure 1). This frameshift in the SOS-1 protein is the first report of a genetic mutation for non-syndromic HGF. Evidence to support the conclusion that a mutation in SOS-1 is responsible for HGF1 includes: cosegregation between this nucleotide change and the HGF phenotype in the family studied, but not in 208 control chromosomes from healthy patients (Hart *et al.*, 2002); SOS-1 is expressed in gingiva (Hart *et al.*, 2002), the tissues that are affected by the disorder; wild-type SOS-1 is maintained in a down-

regulated state (Hart *et al.*, 2002). Because the truncation of SOS-1 protein is a germline mutation, all cells in an affected person contain the mutation (Trackman and Kantarci, 2004). However, to date it is unknown why this mutation manifests solely in the gingiva in the form of overgrowth.

Mutation or truncation of the SOS-1 protein has been demonstrated to result in a gain of function in not only humans, but also in *Drosophila melanogaster* (McCollam *et al.*, 1995) and mice (Sibilia *et al.*, 2000). SOS-1 knockout mouse constructs have provided a more thorough understanding of the role of this gene. Homozygous null (SOS-1^{-/-}) mouse embryos die mid-gestation (Qian *et al.*, 2000; Wang *et al.*, 1997) as a result of cardiovascular defects (Wang *et al.*, 1997) or secondarily to placental malformation (Qian *et al.*, 2000). SOS-1^{-/-} embryos had inadequate labyrinth development, which prevented the transition from a yolk sac to placental dependent nutrition, ultimately leading to mid-term lethality (Qian *et al.*, 2000). Differences in the cause of fatality may be attributed to various exons used for SOS-1 disruption, environmental differences or variability in backgrounds of strains used. To further characterize signaling and growth properties of SOS^{-/-} fetuses, Qian also infected cell lines (-/-, -/+, +/+) with retroviruses expressing protein tyrosine kinases (v-Sre or EGFr). Only the -/- cell line was resistant to activation by these tryrosine kinases, implying that SOS-1 is necessary to carry out this function (Qian *et al.*, 2000).

Fibroblasts of SOS-1^{-/-} embryos have reduced MAPK activation in response to EGF; however, a heterozygous mutation in SOS-1 (SOS-1^{+/-}) dominantly enhances the phenotype of a weak allele of the EGFr allele (Wang *et al.*, 1997). EGFr is required for

skin development and is implicated in epithelial tumor formation (Sibilia *et al.*, 2000). A transgenic mouse construct of a similar SOS-1 mutation, as is found in HGF1, or carboxyl terminal deletion called SOS-F, when expressed in the epithelium under the control of cytokeratin-5 promoter, induces skin-tumor development, multiple papillomas and hypertrophic skin (Sibilia *et al.*, 2000). Tumor formation is however inhibited in a null EGFr background (Wang *et al.*, 1997). The fact that HGF can be caused by mutations in an oncogene SOS-1 demonstrates that genes involved in the Ras gene signal pathway or have an effect in cell growth control or cell cycle are attractive candidates to cause HGF (Ye *et al.*, 2005).

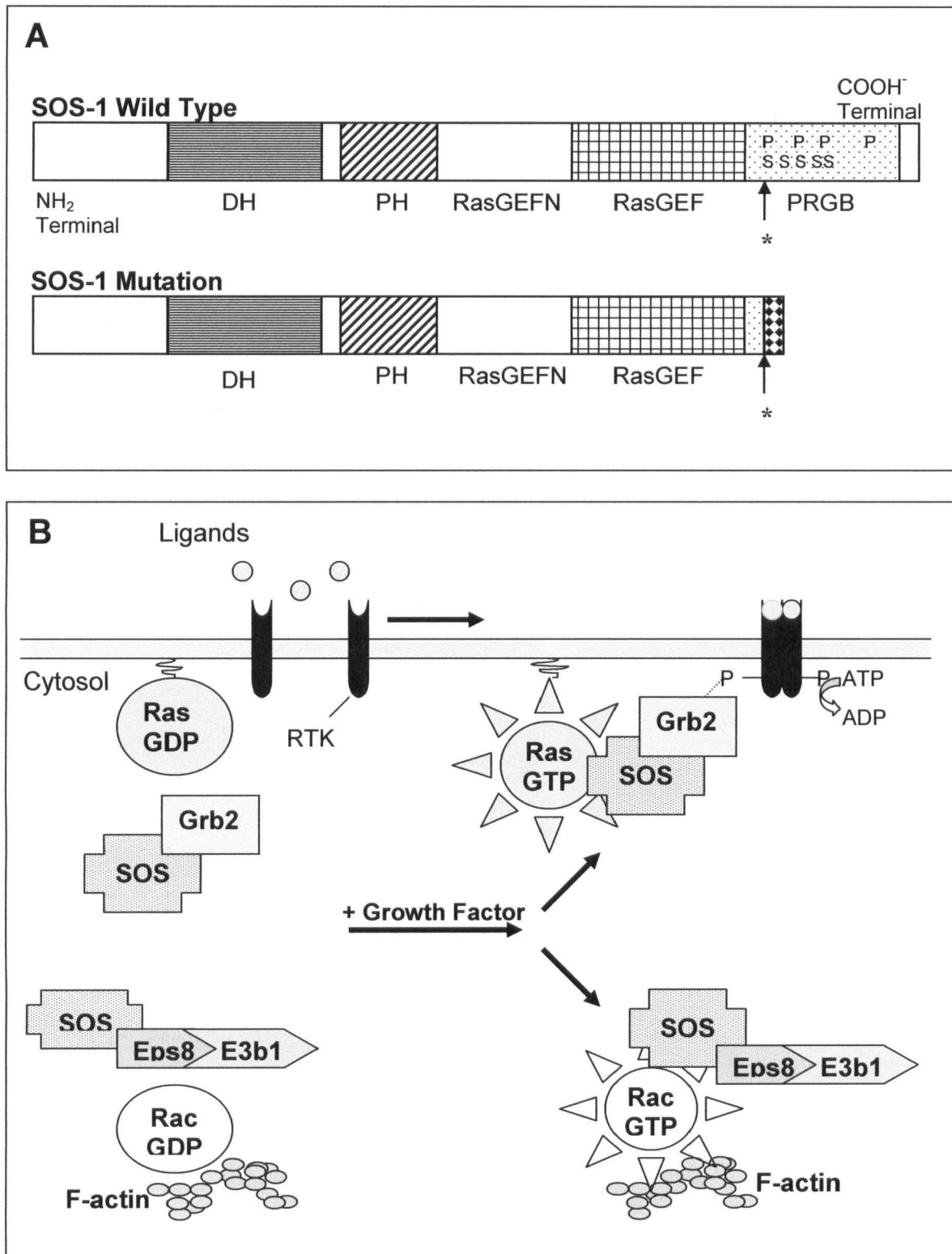


Figure 1. Structure of wild type and mutant SOS-1 present in HGF1 (A) and its function in activation of Ras and Rac pathways (B).

2.5 Pathogenesis of HGF

The precise pathogenic mechanism underlying HGF has not been clearly delineated. It may be variable as a result of genetic heterogeneity. In cases where a SOS-1 gene mutation is thought to play a role in disease initiation, the mutation itself may have a unique effect on the cellular biology of connective tissues.

2.5.1 Phenotypically different fibroblast subpopulations

Fibroblasts are the most common cell in connective tissue. They produce collagen, elastin, matrix metalloproteinases (MMP; collagenase, gelatinase, stromelysin, matrilysin), glycoproteins and proteoglycans (Birkedal-Hansen, 1988). Phenotypically and functionally distinct fibroblast subpopulations may coexist within and between individuals (Hakkinen and Larjava, 1992; Hassell, 1993). Studies have found that when counted manually under magnification, fibroblast density is less within connective tissues of HGF than DIGO; however, the importance of this finding is questionable as both active and latent fibroblasts were measured (Wright, 2001). Predominance of certain “active” fibroblast subpopulations may explain the susceptibility of certain individuals to gingival overgrowth. The correlation between onset of HGF and tooth eruption implies that selection or activation of fibroblasts as a result of trauma or inflammatory cells may initiate gingival overgrowth (Shirasuna *et al.*, 1988). Although inflammation may be transient, in vitro studies have suggested that fibroblasts from fibrotic tissues could remain activated even in the absence of continuous stimulation (Duncan and Berman, 1987; Hassell *et al.*, 1976; Tipton *et al.*, 2004). Therefore, it is possible that gingival fibroblasts in HGF could remain active long after tooth eruption, contributing to excess

ECM production. This process is similar to wound healing, although in HGF this process would be continuously turned on.

2.5.2 Proliferation of gingival fibroblasts

Gingival fibroblasts in HGF proliferate at higher rates (Coletta *et al.*, 1998; Tipton *et al.*, 1997) and produce greater amounts of TGF- β_1 and TGF- β_2 than normal human gingival fibroblasts (Tipton and Dabbous, 1998; Wright, 2001). These results are contrary to another study that found slower fibroblast proliferation rates in non-syndromic gingival fibromatosis than in healthy controls (Shirasuna *et al.*, 1988). Such variability may be attributed to differences in culturing technique, genetic heterogeneity, examining fibroblasts from different sources of biopsy materials or various cell behaviors in the different types of fibrosis.

Autocrine stimulation by TGF- β is linked to excess collagen production in HGF, but it does not affect fibroblast proliferation rates; hence, autocrine stimulation by other growth factors or greater basal collagen production may also be involved (Tipton and Dabbous, 1998). This is in contrast to another study that using BrdU labeling, PCNA indexes and cytometric analysis demonstrated that neutralizing antibodies to TGF- β_1 abolish the mitogenic effect of TGF- β_1 induced HGF fibroblast proliferation (de Andrade *et al.*, 2001). Reduction in TGF- β_1 was positively correlated with the percentage of cells in G₁ phase of the cell cycle, signifying that TGF- β_1 may mediate G₁/S transition of HGF fibroblasts and, therefore, account for the growth stimulation of cells in HGF (de Andrade *et al.*, 2001). Differences in reported function and proliferation of HGF

fibroblasts may be a result of genetic heterogeneity of HGF, inter-individual differences or phenotypic differences among fibroblasts.

2.5.3 C-myc

C-myc, a nuclear proto-oncogene, is important in cell proliferation and differentiation (Freytag, 1988). Increased expression of c-myc has been associated with deregulated cell growth in neoplastic cells and it is also an important element in responding to growth factors and gene transcription (Trojanowska *et al.*, 1988). C-myc is expressed by proliferating cells throughout the cell cycle, confirming its role in initiation and maintenance of cell proliferation (Tipton *et al.*, 2004).

Immunohistochemical examination revealed c-myc and bcl-2 expression in basal and suprabasal cell layers of nifedipine and phenytoin induced hyperplastic gingival epithelia, but not in healthy tissues (Saito *et al.*, 2000). Synergistic over-expression of oncoproteins may be related to the pathogenesis of nifedipine and phenytoin DIGO (Saito *et al.*, 2000). Studies have also examined the relationship between HGF fibroblast proliferation, as measured by assessing BrdU incorporation into cellular DNA via ELISA, and c-myc expression using quantitative PCR (Tipton *et al.*, 2004). C-myc mRNA levels were higher in quiescent HGF fibroblasts than control fibroblasts, indicating that some cells were proliferating in HGF. Gene amplification or chromosomal translocation may be possible mechanisms by which c-myc expression is stimulated in HGF fibroblasts (Tipton *et al.*, 2004). Elevated c-myc expression in HGF may be responsible for increased fibroblast proliferation rates and predominance of activated fibroblast phenotypes (Tipton *et al.*, 2004).

2.5.4 Extracellular matrix molecules

Accumulation of excess ECM molecules can be a result of increased production or conversely decreased breakdown. There is less support favoring the latter process, as gingival connective tissues in HGF have dense collagen fibers and there is a 2.2-fold increase in collagen synthesis by HGF fibroblasts compared to controls (Shirasuna *et al.*, 1988). Type I collagen and fibronectin production as measured by ELISA, was also found to be statistically greater in HGF than sex/race-matched healthy controls (Tipton *et al.*, 1997); however, due to the small sample size, limited fibroblast strains and in vitro design, caution is warranted when interpreting results of this study. Increased collagen synthesis has also been demonstrated in DIGO and scleroderma (Duncan and Berman, 1987; Hassell *et al.*, 1976). TGF- β can increase ECM synthesis by stimulating fibroblasts or conversely, it can inhibit its breakdown by inhibiting matrix metalloproteinase-1 (MMP-1) and increasing expression of tissue inhibitors of matrix metalloproteinases (TIMP) (Edwards *et al.*, 1987). Fibroblasts can activate autocrine pathways in response to tissue injury, which then leads to a proliferative response.

Treating normal human fibroblasts with neutralizing antibodies to TGF- β isoforms does not have a significant effect on fibronectin and collagen production (Tipton and Dabbous, 1998); hence, ECM production by control fibroblasts is not under significant autocrine control. However, blocking TGF- β isoforms with anti-TGF- β antibodies in HGF reduces fibronectin production to control values, suggesting that in HGF autocrine stimulation by TGF- β contributes to increased ECM production (Tipton and Dabbous, 1998). All three TGF- β isoforms are necessary for maximal fibronectin production (Tipton and Dabbous, 1998). Fibronectin, a fibroblast chemoattractant, promotes

fibroblast attachment to ECM components (Tipton *et al.*, 2004). Hence, an increase in fibronectin may promote gingival overgrowth by contributing to the bulk of tissue or via its effects on fibroblasts (Tipton *et al.*, 1997).

In vitro, cells in HGF have a higher rate of proliferation and produce more type I collagen and heat shock protein (Hsp) 47, its molecular chaperone, than control tissues (Martelli-Junior *et al.*, 2003). Heat shock proteins are highly conserved stress proteins. They facilitate protein folding and hence prevent aggregation and targeting of poorly folded proteins to degradative pathways. For example, binding of Hsp47 to type I procollagen prevents its premature folding, aggregation and degradation (Jain *et al.*, 1994; Satoh *et al.*, 1996). Using RT-PCR, ELISA, Western blot and enzymographies, HGF fibroblasts were found to have elevated TGF- β_1 and IL-6 production, which enhanced levels of type I collagen and Hsp47 mRNA and protein levels, and decreased MMP-1 and MMP-2 (Martelli-Junior *et al.*, 2003). The authors hypothesized that co-regulators of collagen and Hsp47 may be necessary in HGF gingival overgrowth because Hsp47 may be involved in processing type I procollagen, resulting in collagen accumulation. However, this study did not assess TIMP levels, which are also crucial in the balance between collagen degradation and production. Although studies have examined production of type I collagen, fibronectin and Hsp, information is lacking about other ECM molecules.

2.5.5 Transforming Growth Factor- β and its receptors

The transforming growth factor beta (TGF- β) family is a group of cytokines with an important role in wound healing, tissue regeneration and stimulating fibroblast proliferation and production of ECM molecules (Tipton and Dabbous, 1998). There are

five isoforms of TGF- β , designated TGF- β_1 through TGF- β_5 ; however, only TGF- β_1 , TGF- β_2 and TGF- β_3 are expressed in mammals (Govinden and Bhoola, 2003). The effects of these cytokines are mediated through three different classes of TGF- β cell surface receptors (I,II, III) (Massague, 1992; Wright, 2001). TGF- β is produced predominantly by gingival inflammatory cells, endothelial cells, mast cells, epithelial cells and fibroblasts (Wright, 2001). The effects of TGF- β can be exerted in an autocrine or a paracrine fashion (Sporn and Roberts, 1990). Autocrine stimulation by this cytokine is influenced by the amount of TGF- β produced, as well as their level of receptor expression (Tipton and Dabbous, 1998). Most TGF- β is produced in a latent form that must subsequently be activated by the cells. Thus, the presence or absence of the mechanisms that activate TGF- β play a large role in the regulation of TGF- β function. Furthermore, certain ECM molecules, including the small leucine-rich proteoglycans decorin, biglycan and fibromodulin, can inhibit TGF- β activity.

All three isoforms of TGF- β can be found in wounds; however, TGF- β_1 comprises the majority of this expression (O'Leary *et al.*, 2002). TGF- β_1 induces scarring, stimulates ECM production and enhances fibroblast proliferation by increasing the G₁/S transition, DNA synthesis and shortening the G₁ phase of the cell cycle (Kim *et al.*, 1998). TGF- β_2 serves as a compensatory mechanism aimed at counteracting the effects of TGF- β_1 over-expression. TGF- β_3 moderates the effects of TGF- β_1 and TGF- β_2 , possibly inhibiting fibrosis and scarring (Shah *et al.*, 1995).

HGF fibroblast strains produce increased levels of TGF- β_1 and TGF- β_2 , which is coupled to a stimulatory response that results in increased ECM formation (Tipton *et al.*, 1997;

Tipton and Dabbous, 1998; Tipton *et al.*, 2004; Trackman and Kantarci, 2004). A recent immunohistochemical study has also reported a significant proportional increase in TGF- β_1 and TGF- β_3 expression in both DIGO and HGF, but a decrease in TGF- β_2 expression in HGF tissues (Wright, 2001). Variability in TGF- β_2 levels may reflect increased secretion by HGF fibroblasts in vitro or culturing of fibroblast strains present in lower proportions in the gingiva. Although TGF- β receptor I and II positive cells were detected in equal numbers in DIGO, HGF and controls, the proportion of receptor-positive cells were significantly increased in DIGO and HGF (Wright, 2001). Thus, increased levels of TGF- β_1 may override the “antifibrosis” effects of the decreased TGF- β_2 and maintenance of TGF- β_3 expression in HGF (Wright, 2001). TGF- β_1 was also the predominant isoform secreted in both health and disease; the amount produced being ten times greater than TGF- β_2 (Roberts, 1984; Tipton and Dabbous, 1998). Using quantitative PCR, similar levels of TGF- β mRNA expression was found by control and HGF fibroblasts (Tipton and Dabbous, 1998). Therefore, increased protein production by HGF fibroblasts is likely a result of post-transcriptional differences between control and HGF fibroblasts. Interestingly, the fibrotic effect of TGF- β appears to depend on its property to induce autocrine expression of CTGF (Blom *et al.*, 2002). However, nothing is known about expression of CTGF in HGF.

2.5.6 Matrix metalloproteinases and tissue inhibitors of matrix metalloproteinases

Decreased collagen degradation may result from an increase in the proportion of tissue inhibitors of matrix metalloproteinases (TIMP) relative to matrix metalloproteinases (MMP). MMPs are a family of zinc dependent peptidases responsible for ECM degradation during tissue remodeling (Johnson *et al.*, 1998). They are classified based on

their substrate specificity as collagenases (MMP-1, -8, -13), gelatinases (MMP-2, -9), stromelysins (MMP-3, -10, -12) or membrane-type MMPs (MT-MMPs) (Coletta *et al.*, 1999). While MMP-1 plays a role in interstitial collagen degradation, MMP-2 affects type IV collagen, but can also act on type I collagen in vitro (Aimes and Quigley, 1995). Although TIMPs (TIMP-1, -2, -3, -4) inhibit MMPs, the gene expressions of both may be regulated by TGF- β_1 (Overall *et al.*, 1991). A high ratio of TIMP to MMP-1 may result in excess collagen accumulation seen in HGF and DIGO.

TGF- β_1 stimulates fibroblasts to upregulate type I collagen, MMP-2 and possibly TIMP-1, while downregulating MMP-1 expression (Fujiwara *et al.*, 2005; Ma *et al.*, 1999; Overall *et al.*, 1989; Overall *et al.*, 1991). In an in vitro study, ELISA was used to demonstrate that TGF- β_1 levels are 1.3-2.5 fold greater in HGF than health (Coletta *et al.*, 1999). According to RT-PCR and enzymography, cells in HGF express and produce significantly less MMP-1 and MMP-2 and similar levels of TIMP-1 and TIMP-2 compared to controls (Coletta *et al.*, 1999). Furthermore neutralizing TGF- β_1 with antibodies against TGF- β_1 results in decreased production of MMP-2 and slightly increased production of MMP-1 (Coletta *et al.*, 1999). The latter may be regarded as a sign of autocrine stimulation by TGF- β_1 . In health, ECM turnover is regulated by the delicate balance between MMP's and TIMP's; thus, it is possible that a genetic defect in HGF may disrupt this balance, resulting in ECM accumulation. The ratio of MMP-1 to TIMP-1 could be the basis for fibrosis in gingival overgrowth.

2.5.7 Collagen phagocytosis

Collagen phagocytosis may also play a role in fibrosis. In an in vitro study, there was a dose-dependent decrease in the percentage of phagocytic cells in nifedipine treated fibroblasts compared to controls (McCulloch and Knowles, 1993). Although fibroblasts derived from healthy tissues had a wide range of collagen phagocytic activity, they had proportionally more phagocytic cells, as well as cell populations with high phagocytic activity than those obtained from fibrotic tissues (McCulloch and Knowles, 1993). Fibrotic lesions, especially in the absence of inflammation, are likely to arise from a reduction in the proportion of fibroblasts with phagocytic activity (McCulloch and Knowles, 1993). Whether fibrosis results from changes in the balance between MMPs and TIMPs or a decrease in the amount of fibroblasts with phagocytic activity warrants further investigation.

2.5.8 Fatty acid synthesis

Recently, a link has also been suggested between fatty acid synthesis (FAS) and HGF. Upregulated FAS activity has been found in tumor cells of the tongue (Krontiras *et al.*, 1999) and oral squamous cell carcinoma (Zhang *et al.*, 2005), suggesting a link between FAS and control of the cell cycle. Furthermore, fibroblast proliferation rates appear to be positively correlated with FAS production, which is in part modulated by testosterone levels (Almeida *et al.*, 2005). Inhibiting FAS, reduced fibroblast proliferation rates in health and HGF (Almeida *et al.*, 2005). The role of TGF- β_1 in modulating FAS is not yet known.

2.5.9 Summary

The pathogenesis of HGF has not been clearly delineated. Since this disease is genetically heterogeneous, numerous concurrent mechanisms may be involved. Nonetheless, the balance between collagen production and degradation is disrupted resulting in excess ECM accumulation, a process similar to excessive wound healing response leading to scar formation in skin. Interestingly, patients with HGF do not usually display fibrosis as excessive scar formation in skin, suggesting that unique molecular mechanisms or cells are involved in gingiva. Cell selection of certain fibroblast strains may be important in disease pathogenesis. HGF fibroblasts have a higher rate of proliferation and subsequent production of type I collagen and fibronectin (Tipton *et al.*, 1997). They also produce elevated levels of TGF- β_1 , an autocrine stimulator of ECM production; however, this does not affect rates of fibroblast proliferation (Wright, 2001). It is possible that fibroblasts in HGF are overstimulated by growth factors and cytokines, resulting in excess production of ECM molecules and hence fibrosis. Furthermore, MMP-1 and MMP-2 production and expression are also decreased as a consequence of elevated levels of TGF- β_1 (Coletta *et al.*, 1999). Phagocytic cells and FAS may also be important mediators of ECM accumulation, but warrant further investigations. Gingival overgrowth in HGF is most likely caused by a combination of reduced ECM degradation and increased fibroblast proliferation.

2.6 HGF versus drug induced gingival overgrowth

As in HGF, there is no clear consensus about the pathogenesis of DIGO. However, it seems likely that the homeostasis of collagen synthesis and degradation is disrupted (Kataoka *et al.*, 2005). Most medications associated with DIGO exert their

pharmaceutical effects by targeting the Ca^{++} signaling pathways and result in a severe accumulation of ECM in gingival connective tissues (Deliliers *et al.*, 1986; Yamasaki *et al.*, 1987). Some studies have also found increased fibroblast levels, but this may be attributed to the various degrees of gingival inflammation because production of inflammatory cytokines such as IL-1 β , can stimulate fibroblast proliferation and induce collagen synthesis (Kataoka *et al.*, 2005; Wright, 2001).

Platelet derived growth factor (PDGF), a cytokine that is upregulated during fibrosis and wound healing, does not appear to play a pivotal role in DIGO or HGF (Cochran and Wozney, 1999; Wright, 2006). PDGF is expressed by fibroblasts, macrophages and epithelial cells. In one study, culturing rat peritoneal macrophages and human blood monocytes with phenytoin, led to increased levels of PDGF-B mRNA, suggesting a potential link to gingival overgrowth (Dill *et al.*, 1993). Similar increases in PDGF-B have been reported by others in association with phenytoin therapy (Nares *et al.*, 1996). Since macrophages play an important part in gingival changes during inflammatory states, releasing PDGF-B was thought to be one possible mechanism through which inflammation can exacerbate at least phenytoin and cyclosporin induced gingival overgrowth (Seymour *et al.*, 1996). However, in a recent study that used RT-PCR and immunohistochemistry, levels of PDGF-B were significantly decreased in cyclosporine induced gingival overgrowth compared to HGF and health, suggesting that macrophages may not have a pivotal role in gingival overgrowth (Wright, 2006). The authors postulated that the high levels of TGF- β_1 seen in HGF and DIGO may regulate differences in PDGF and its receptor. Furthermore, the fact that increased levels of TGF-

β_1 do not affect fibroblasts similarly in HGF and DIGO, may reflect a genetic defect that predisposes patients with HGF to fibrosis (Wright, 2006).

TGF- β may be important in the pathogenesis of both DIGO and HGF. Increased fibroblast production of TGF- β_1 and an autocrine role in the pathogenesis of both types of overgrowth has been reported (Wright, 2001). Higher levels of TGF- β_1 seen in HGF compared to DIGO may reflect the severity of overgrowth in the former. Elevated TGF- β expression has been reported in patients with cyclosporine renal fibrosis (Pankewycz *et al.*, 1996; Saggi *et al.*, 2004) and in immunohistological studies of patients treated with phenytoin and nifedipine (Saito *et al.*, 1996). Expression of this growth factor is also increased in the gingival crevicular fluid of patients with phenytoin induced gingival overgrowth (Kuru *et al.*, 2004).

As in HGF, similar decreases are seen in MMP-1, MMP-2 and MMP-3 expression by human gingival fibroblasts treated with phenytoin, whereas TIMP-1 is induced in a dose and time dependent manner (Kato *et al.*, 2005). Cyclosporin stimulates TGF- β_1 expression, which in turn inhibits expression of MMP-1 and MMP-2 by human gingival fibroblasts; cyclosporine only has a small effect on TIMP-1 and TIMP-2 expression (Cotrim *et al.*, 2002; Hyland *et al.*, 2003). However, cyclosporine induced focal interstitial fibrosis in the rat is associated with increased TIMP-1 levels rather than decreased MMP expression (Duymelinck *et al.*, 1998). Using human versus animal constructs may account for differences between studies. In general, MMP-1 and MMP-2 levels appear to be reduced in both types of overgrowth, disturbing the balance between MMPs and TIMPs.

HGF and DIGO may not rely solely on the autocrine effects of TGF- β_1 (Coletta *et al.*, 1999). Drug induced and hereditary forms of gingival overgrowth may share another common molecular basis. The region at 5q13-q22 associated with HGF also encompasses the calcium/calmodulin dependent protein kinase IV (CAMK4), which is important in calcium regulation (Xiao *et al.*, 2001). Using RT-PCR, CAMK4 expression was also demonstrated in gingival tissues (Xiao *et al.*, 2001). Calcium is a secondary messenger, whose effects are mediated through its interaction with calmodulin and hence activation of CAMK. CAMK's are involved in cellular processes such as muscle contraction, neurotransmitter release, cell cycle control, and transcriptional regulation (Gardner *et al.*, 2000). In addition, a sodium/calcium exchanger gene (NCX1) and calmodulin (CALM2) also reside within chromosome 2p21 interval that cosegregates with HGF (Hart *et al.*, 1998). However, there are no studies that have analyzed the possibility of mutations to NCX1 and CALM2 in HGF. Since cyclosporine A, nifedipine and phenytoin are all calcium antagonists, they too are associated with calcium influx, leading to decreased oxygen consumption (Antman *et al.*, 1980).

All types of DIGO are similar clinically and prevail in the anterior sextants. Initially, there is a change in the shape and size of the interdental papillae, which continue to enlarge and coalesce with disease progression; the marginal gingiva may also become involved (Lindhe, 2003). It is unknown why DIGO begins at the interdental papillae. The role of dental plaque in the initiation of gingival enlargement has not been established; however, the presence of plaque is a risk factor for overgrowth in patients taking phenytoin or nifedipine (Brunet *et al.*, 2001; Majola *et al.*, 2000; Miranda *et al.*, 2001). It is currently unknown whether HGF originates in the papillae. Clinically there

are situations where only the papillae are affected (Flaitz and Coleman, 1995); however, in the majority of cases, the marginal gingiva also becomes involved (Kelekis-Cholakis *et al.*, 2002), suggesting a papillary origin. Thus, HGF may result as an expansion of papillary tissue as a result of a genetic defect. If this is the case, the gingival papilla must be predisposed to overgrowth in some way, for example, inherently different expressions of key molecules in the papilla compared to the marginal gingiva may be involved in this process.

Anatomically, the marginal gingiva is the tissue located at the junction of a tooth and spanning between the mesial and distal line angles; the interdental papilla is the tissue located in the interproximal areas. The latter is pyramidal in shape anteriorly and becomes flattened in the buccolingual direction in the posterior sextants (Lindhe, 2003). The gingiva obtains its final shape in conjunction with tooth eruption (Lindhe, 2003). Specifically, the shape of the papilla is determined by the contact points of adjacent teeth, the widths of proximal tooth surfaces, as well as the shape of the cementoenamel junction (Lindhe, 2003). To our knowledge, there are no studies that have examined the similarities and differences in the molecular composition of the marginal gingiva and interdental papilla.

2.7 Treatment of hereditary gingival fibromatosis

HGF cannot be cured; treatment is symptomatic and depends on the degree of severity. When enlargement is minimal, scaling/root planning and thorough home care may be sufficient to maintain good oral health (Baptista, 2002). However, as the amount of excess tissue increases, treatment is dictated by function and esthetics. In such cases,

therapy consists of surgical removal of hyperplastic gingiva by conventional external incision gingivectomy, internal bevel gingivectomy (Casavecchia *et al.*, 2004) or lasers (Miller and Truhe, 1993). If the volume of the overgrowth is extensive, pseudopockets can be eliminated using a repositioned flap (Lindhe, 2003). Using this surgical technique will avoid exposure of connective tissue that in such severe cases would normally occur with a gingivectomy.

Reports of recurrence rates vary in the literature; however, relapse is not rare. There have been several reports where tissues did not relapse 2 years (Ramer *et al.*, 1996), or even 3 years after therapy (Bittencourt *et al.*, 2000). Yet others have advocated full-mouth clearance, as gingival overgrowth did not recur in the absence of teeth (Kharbanda, 1993). However, in a case report of a 38-year-old female with HGF, (Baptista, 2002) tissues relapsed 20 months after therapy. Relapse was also noted after 3 years in a 13-year-old girl (Kelekis-Cholakis *et al.*, 2002). James (James, 1971) found that recurrence was decreased if surgical excision of the hyperplastic gingiva was delayed until the permanent dentition has fully erupted. Surgical management is recommended in severe cases, as the esthetic improvements and hence the psychological benefits that result from excising overgrown tissues outweigh the risk of recurrence (Bhavsar *et al.*, 1991).

HGF is a complicated disorder that is currently still under investigation. Due to its rare occurrence, it is a difficult subject to study. Currently, there have been no reports that have outlined the exact mechanism underlying the disorder and thus suggested treatments have been symptomatic.

3 Aim of the Study

The aim of the study was to determine the expression of certain ECM molecules, their receptors, cytokines and growth factors in HGF. These findings will be compared to healthy marginal gingiva and interdental papilla to determine the differences in expression of molecules between health and disease. Results from HGF tissues will also be compared to the expression of the same molecules in human gingival wounds found in previous studies in our laboratory. Comparing HGF biopsies to healthy tissues and gingival wounds will provide a better understanding of the underlying mechanisms of HGF.

We hypothesized: 1) The composition of the healthy papilla differs from that of the healthy marginal gingiva. Therefore, in case that HGF results from expansion of papillary tissue, HGF will display the molecular characteristics of gingival papilla. 2) The expression patterns of certain molecules in HGF resemble wound granulation tissue suggesting that processes involved in gingival wound healing are upregulated in HGF. Therefore, we compared marginal gingival samples from health, HGF and wounds and studied molecules whose expressions are regulated during wound healing and are responsible for ECM organization, production and cell proliferation. The expression pattern of $\alpha v\beta 6$ was determined in health and HGF, as it is a wound-specific epithelial integrin with a role in activation of latent TGF- β (Sheppard, 2005) and hence plays an important role in modulating tissue fibrosis and abnormal wound healing (Hakkinen *et al.*, 2004). TGF- β and CTGF were also examined, as both are growth factors that promote ECM production, a hallmark of HGF, DIGO and wound healing (Tipton and Dabbous, 1998; Uzel *et al.*, 2001; Wright, 2001). TGF- β also promotes CTGF

expression (Igarashi *et al.*, 1993). Localization of FN-EDA, FN-EDB, procollagen and tenascin-C, that are strongly upregulated in wound healing, was determined (Boykiw *et al.*, 1998; Hakkinen *et al.*, 1996; Hakkinen *et al.*, 2000a; Larjava *et al.*, 2002; Singh *et al.*, 2004; Soo *et al.*, 2000). Finally, we studied the expression of small leucine-rich proteoglycans decorin, biglycan, fibromodulin and lumican, as these molecules are important inhibitors of TGF- β activity in vitro and in vivo, modulate collagen deposition and may be involved in scar formation. We also studied the expression of SOS-1 in healthy gingiva and wound healing, as this molecule was found to be important in the pathogenesis of HGF1 (Hart *et al.*, 2002). Because HGF may be a form of spontaneous overhealing of wounds without the physical presence of a wound, SOS-1 expression may be similar to wound healing. Localization of CK19 expression was used as a marker for junctional/sulcular epithelium (Pritlove-Carson *et al.*, 1997). It is possible that processes involved in gingival wounds may be spontaneously upregulated in HGF and may provide novel targets to preventing gingival overgrowth.

4 Materials and Methods

4.1 Gingival samples

Human marginal and/or papillary gingival tissue samples were obtained from 10 individuals with hereditary gingival fibromatosis between the ages of 7-47 years (Tables 2 and 3; Figure 2B). Eight of these samples were donated by Dr. John Matthews from the University of Birmingham, U.K., one from Dr. Collin Wiebe from the University of British Columbia, Canada and one from Dr. Hannu Larjava from the University of British Columbia, Canada. Healthy tissue samples (control group) were also harvested from marginal and/or papillary gingiva from five healthy control patients between 25 and 65 years of age (Table 2; Figure 2A). The control group was comprised of patients who were undergoing crown lengthening surgery. Individuals in the control group were medically healthy, did not have periodontal disease in the surgical area, were non-smokers and were not taking any medications (Table 4). Informed consent to participate in this investigation was obtained from all subjects. All the procedures were in accordance with regulations set forth by the Office of Research Services, Behavioral Research Ethics Board, Biosafety and Animal Care, University of British Columbia.

After harvesting, biopsies were immersed in physiological saline for a maximum of one hour, until being embedded in optimal cutting temperature compound (Tissue-Tek[®], Miles Inc., Elkhart, IA, USA) and immediately frozen in liquid nitrogen. Tissue block samples were stored at -86°C until frozen sections were prepared. Using a cryostat, serial cross-sections (5µm) were prepared from each sample and placed onto 3-aminopropyltriethoxysilane (Fluka Chemie, Buchs, Switzerland) – coated slides, air dried and stored at -86°C until further use. Every tenth slide from each subject was stained

with hematoxylin and eosin and tissue morphological characteristics were analyzed using a Zeiss Axiolab E light microscope (Carl Zeiss Jena, Germany). Frozen sections were used for immunolocalization studies.

Wound samples previously obtained from two systemically healthy young adult subjects were also employed in the present experiment. Participants were non-smokers, did not take any medications, nor did they have a family history of gingival overgrowth. Full thickness biopsies measuring 10 mm long x 2 mm wide x 2 mm thick were harvested from the palatal masticatory mucosa. Incisions were made at least 3 mm away from the gingival margins of premolars. Samples (unwounded tissue) were rinsed with physiologic saline, embedded in Tissue-Tek O.C.T. (Sakura Finetek Inc, Torrance, CA), flash frozen in liquid nitrogen and stored at -86°C until further use. Palatal wounds were left to heal uncovered for 3, 7, 14, 28 or 60 days, at which time a 4 mm diameter punch biopsy was harvested from each wound. These tissue samples were prepared for histology and immunohistochemistry in a similar manner as control samples.

Table 2. Patient characteristics.

	Control N=5	Hereditary Gingival Fibromatosis N=10
Gender (male/female)	4/1	1/9
Age (years)	25-65	7-47
Severity of Overgrowth	-	Mild to severe
Number of Different Areas Examined ^{***}	14	15

*** Refer to Tables 3 and 4 for a detailed listing of patients who had >1 area examined per tissue biopsy.

Table 3. Specifics of patient characteristics with HGF.

Patient	Age	Gender	Medications	Severity of Overgrowth**	Number of Areas Examined per Biopsy***
1	28	Female	None	Generalized overgrowth with mild to severe localized involvement	1
2	44	Female	None	Mild/Moderate	1
3	34	Female	None	Moderate/Severe	1
4	45	Female	HRT, coproxamol, ibuprofen, ventolin	Very severe	1
5	47	Female	None	Mild	1
6	35	Female	None	Moderate	1
7	32	Female	Oral contraceptives	Moderate	1
8	30	Female	Oral contraceptives, Prozac	Mild	1
9	7	Male	None	Severe	1
10	15	Female	None	Moderate/Severe	6

** Severity of overgrowth graded according to coverage of clinical crown. Mild = $\leq 33\%$; Moderate = 34-50%; Severe = $> 50\%$.

*** Some patients had up to 6 different areas per biopsy immunostained for all molecules of interest and evaluated histologically.

Table 4. Specifics of control patient characteristics.

Patient	Age	Gender	Medications	Number of Areas Examined per Biopsy^{***}
1	47	Male	None	2
2	65	Female	None	4
3	57	Male	None	2
4	37	Male	None	3
5	25	Male	None	3

^{***} Some patients had up to 4 different areas per biopsy immunostained for all molecules of interest and evaluated histologically.

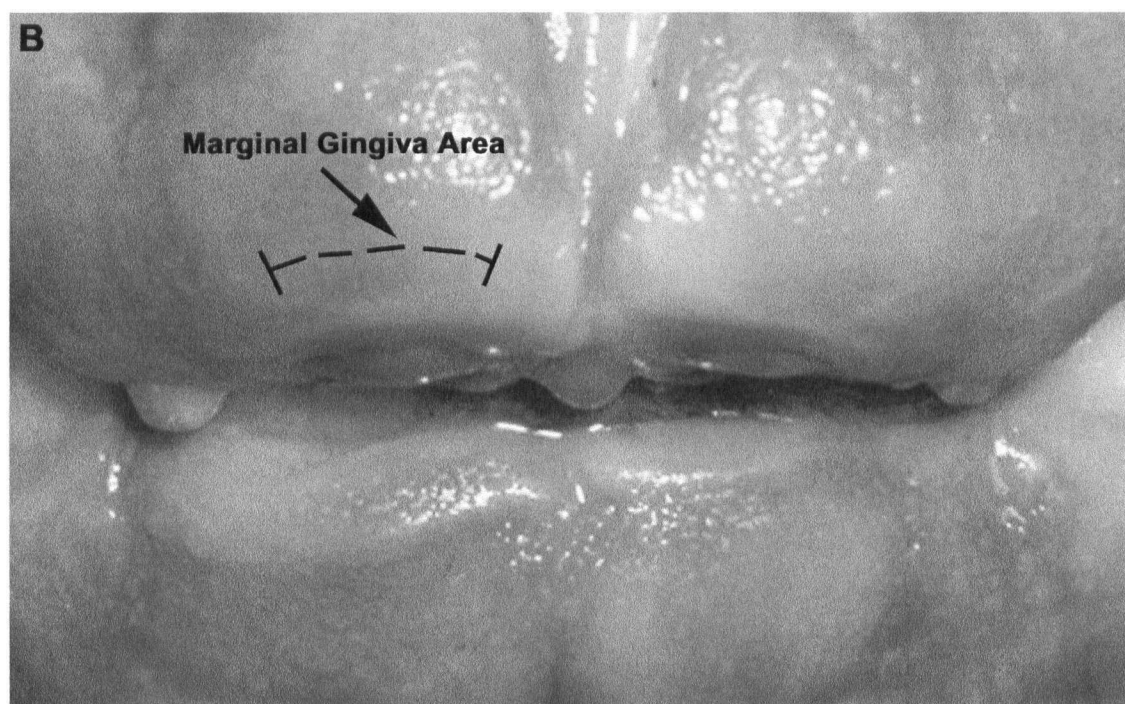
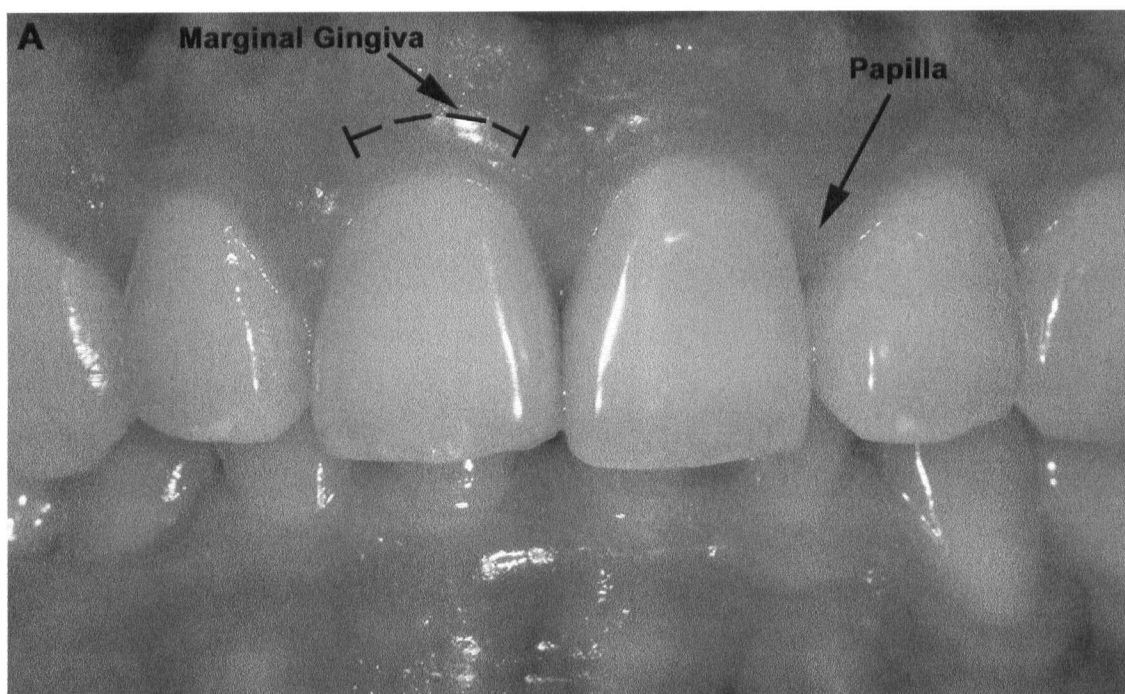


Figure 2. Clinical appearance of gingiva in health (A) versus hereditary gingival fibromatosis (B).

4.2 Immunohistochemical stainings

Frozen tissue samples were briefly thawed at room temperature prior to fixation with -20°C acetone for 5 minutes. After washing with phosphated buffered saline (PBS) containing 1mg/ml bovine serum albumin (BSA) and 0.01% Triton-X 100, sections were incubated with the appropriate normal blocking serum (Vectastain ABC Kit; Vector Laboratories Inc., Burlingame, CA, USA) at room temperature for 30 minutes to block nonspecific binding sites. Primary antibody diluted in PBS/BSA/Triton X-100 (Table 5) was then added and the samples were left in a humidified chamber at 4°C. After 12-18 hours of incubation, sections were washed with PBS/BSA/Triton X-100 and incubated with biotinylated anti-mouse, anti-rat or anti-rabbit secondary antibodies for one hour. Tissue sections were washed with PBS/BSA/Triton X-100, incubated with avidin and biotinylated horseradish peroxidase macromolecular complex (ABC) for 30 minutes (Vectastain Elite Kit, Vector Laboratories Inc.), washed again and reacted with a substrate for the enzyme (Vector® VIP Substrate Kit, Vector Laboratories Inc.) until suitable color development was obtained to localize the tissue antigen. Immersing tissue samples in distilled water halted the reaction. Reaction times for each antibody were standardized for all samples. Sections were left to air-dry and mounted using Vecta-Mount™ (Vector Laboratories Inc.). Negative control stainings were performed by omitting the primary antibody. No color reaction was observed in the negative control samples.

All slides were examined using an Axiolab E light microscope (Carl Zeiss Jena, Germany) with 10x, 20x, and 40x objective. The relative staining intensity was recorded by two independent calibrated examiners for each molecule at the different tissue

locations. The relative immunostaining intensity was scored as – (no immunoreactivity), + (slight, but visible staining intensity), ++ (moderate staining intensity), or +++ (very intense staining intensity). Representative sections were photographed using a Nikon Coolpix 995 digital camera attached to a Nikon Eclipse TS 100 microscope (Nikon, Richmond, BC, Canada) with 10x and 40x objectives. The hematoxylin and eosin stained sections were evaluated for signs of overt inflammation, as determined by the relative degree of inflammatory infiltrate in the connective tissues. Only sections with minimal inflammatory cell infiltrates were used for immunohistological analysis.

Table 5. Antibodies used and their dilutions.

Antibody	Dilution	Reference/Manufacturer
Anti-human CK16 (CBL 273)	1 : 100	Chemicon International Inc., Temecula, CA, USA
Cytokeratin 19 (A53B/A2)	1 : 800	Santa Cruz Biotechnology Inc., Santa Cruz, CA, USA
$\alpha\text{v}\beta 6$ integrin	1 : 10	Dr. Dean Sheppard, Lung Biology Center, UCSF, San Francisco, CA, USA; (Huang <i>et al.</i> , 1998)
Anti-Procollagen type I	1 : 10000	Chemicon International, Temecula, CA, USA
Anti-Decorin	1 : 100	Krusius and Ruoslahti, 1986
Anti-Biglycan (LF 106)	1 : 1000	(Fisher <i>et al.</i> , 1989)
Anti-Fibromodulin (human)	1 : 1,000	(Plaas and Wong-Palms, 1993)
Anti-Lumican (human)	1 : 500	(Grover <i>et al.</i> , 1995)
Anti-Fibronectin-EDA (1ST-9)	1 : 500	Accurate Chemical & Scientific Corp., Westbury, NY, USA
Anti-Fibronectin-EDB (BC-1)	1 : 200	Dr. Zardi, Istituto Nazionale per la Ricerca sul Cancro, Genova, Italy
Anti-Human Tenascin	1 : 400	Sigma BioSciences, St. Louis, MO, USA; (Weller <i>et al.</i> , 1991)
Anti-TGF $\beta_{1,2,3}$ (H-112)	1 : 200	Santa Cruz Biotechnology Inc., Santa Cruz, CA, USA; (Miller <i>et al.</i> , 1990)
CTGF	1 : 500	Biogen Inc., Mississauga, ON, Canada
SOS-1 (C-23)	1 : 800	Santa Cruz Biotechnology Inc., Santa Cruz, CA, USA; (Chardin <i>et al.</i> , 1993)

5 Results

Immunostaining was used to facilitate localization of different epithelial and connective tissue cells in healthy gingiva and HGF. A portion of biopsies obtained from healthy (Table 4) and HGF patients (Table 3) had up to six different areas immunostained for all molecules of interest. Each area was a different section from the same tissue sample. Various degrees of localized inflammation was observed in a subset of hematoxylin and eosin sections from healthy and HGF gingival samples; however, only tissue sections with minimal inflammatory cell infiltrates were used for immunohistochemical analysis.

5.1 Comparison of healthy marginal gingiva and interdental papilla

Healthy marginal gingiva contained epithelial rete ridges that were wide and of similar lengths (Figure 3A), while the interdental papilla had relatively longer rete ridges (Figure 3C). The connective tissue in the marginal gingiva had thick bundles of interlacing collagen fibers. This was in contrast to the connective tissue of the papilla, where collagen fibers bundles were thinner and oriented relatively parallel to one another. There were relatively more blood vessels in the interdental papilla, but similar number of fibroblasts as in the marginal gingiva. Although inflammation was absent from healthy marginal samples (Figure 3A), a proportion of biopsies obtained from the interdental papilla had a moderate inflammatory infiltrate (Figure 3C). However, only those samples with minimal inflammatory cell infiltrates were used for immunostaining.

5.1.1 Characterization of the epithelium

Several differences in the expression of target molecules were noted between the epithelium of healthy marginal gingiva and interdental papilla (Table 6). With the

exception of the occasional isolated basal cell, CK19 was never expressed in the epithelium of marginal gingiva (Figure 4). However, expression of CK19 was notably upregulated in the epithelium of the interdental papilla, being strongest in the basal cells (Figure 4). Expression of $\alpha v \beta 6$ integrin was lacking in the epithelium of the marginal gingiva (Figure 4). In the papilla, $\alpha v \beta 6$ integrin was expressed throughout the epithelium, with expression being strongest at the tips of rete ridges (Figure 4). In marginal gingiva, biglycan immunoreactivity was strongest in the basal cells, although weak immunoreactivity was also evident in the stratum spinosum (Figure 5). In the interdental papilla, biglycan expression was similar in basal cells, but was relatively stronger in the suprabasal layers (Figure 5). Fibromodulin was weakly expressed in the basal cells and some of the immediate suprabasal cell layers of the marginal gingival epithelium (Figure 5). Fibromodulin showed relatively stronger staining intensity in the basal cells of the interdental papilla (Figure 5). A weak staining pattern was also present in stratum spinosum, but not stratum granulosum. The marginal gingiva had relatively weak expression of lumican, with most being localized to the basal cells, but there was no immunoreactivity in stratum granulosum (Figure 5). This was in contrast to the interdental papilla, where lumican expression was stronger throughout, but especially prominent at tips of rete ridges (Figure 5). No expression of decorin, procollagen, fibronectin-EDA, fibronectin-EDB or tenascin-C was noted in the oral epithelium of the marginal gingiva or interdental papilla (Figure 5 and Figure 6).

There were two different patterns of immunostaining with TGF- $\beta_{1,2,3}$, both of which were found in the marginal gingiva and the interdental papilla (Figure 7). In some areas, localization was restricted to the area surrounding basal epithelial cells (Type A), while in

other areas there was strong expression of TGF- $\beta_{1,2,3}$ at the cell membrane facing the basement membrane (Figure 7). In the latter, there was also relatively strong immunoreactivity for TGF- $\beta_{1,2,3}$ in the stratum spinosum and stratum granulosum (Type B). Type A pattern of staining was present in 4 out of 7 marginal gingival samples and 5 out of 6 interdental papilla samples. Although both immunostaining patterns were found in marginal gingiva and papilla, the overall staining intensity was consistently stronger in the interdental papilla (Table 6). Patients could be homogenous or heterogenous for either staining pattern. CTGF expression was strongest by the basal cells of the marginal gingiva; however, there was weak expression by the immediate suprabasal cell layers (Figure 7). CTGF was also expressed by the basal cells of the interdental papilla, although staining intensity was weaker than in the marginal gingiva. Suprabasal staining, especially in the stratum granulosum, was also evident in the papilla (Figure 7). In the marginal gingiva, SOS-1 expression was localized to the basal cells; suprabasal cell layers were negative for SOS-1 (Figure 7). SOS-1 was expressed throughout the epithelium of the interdental papilla, with strongest immunoreactivity being localized at tips of rete ridges (Figure 7).

Table 6. Relative immunostaining intensity in the epithelium of healthy marginal gingiva and healthy papilla.

	Marginal Gingiva			Interdental Papilla		
	SG	SS	BC	SG	SS	BC
CK19	-	-	-	+	+	+++
Integrin $\alpha v \beta 6$	-	-	-	+	++	++/+++
Biglycan	-	+	++	++	++	++
Fibromodulin	-	-/+	+	-	-/++	+++
Lumican	-	+	++	++	++	+++
TGF$\beta_{1,2,3}$	-/++	-/++	+/+++BM	-/+++	-/+++	+/+++BM
CTGF	-	+	+++	++/+++	+	++
SOS-1	-	-	++	+/++	++	+++

BM: cell membrane facing basement membrane; BC: basal cells; SG: stratum granulosum; SS: stratum spinosum; LC: localized. The relative staining intensities are indicative of each molecule at different tissue locations, rather than between different molecules.

5.1.2 Characterization of the connective tissue

Healthy marginal gingiva and papilla have different localization of connective tissue extracellular matrix molecules (Table 7). No expression of CK19 or $\alpha v\beta 6$ integrin was noted in the oral connective tissue of the marginal gingiva or interdental papilla (Figure 4). In the marginal gingiva, decorin was localized on collagen fiber bundles and showed the most intense staining in the subepithelial connective tissue (Figure 5). In the interdental papilla, decorin was localized on thinner isolated collagen bundles and expression was strong in the subepithelial and deep connective tissue (Figure 5). Staining intensity was relatively weak for biglycan in marginal gingiva, but more intense in the deep connective tissues of the papilla (Figure 5). Biglycan was localized to collagen fiber bundles in both locations. In marginal gingiva, fibromodulin showed moderate to strong staining intensity, the latter prevailing in deep connective tissue, and localization to collagen fiber bundles. In the interdental papilla, fibromodulin expression was slightly weaker in subepithelial and deep connective tissue (Figure 5). Fibromodulin was localized to collagen fiber bundles in deep connective tissue in the interdental papilla. Immunoreactivity for lumican was moderate in the subepithelial connective tissue and strongest in the deep connective tissue of marginal gingiva (Figure 5). Staining intensity for lumican was significantly weaker at all levels of connective tissue in the interdental papilla. Lumican was localized to collagen fiber bundles in the marginal gingiva and papilla. In the marginal gingiva, procollagen type I, the precursor of type I collagen, showed strongest immunoreactivity at the basement membrane zone (Figure 6). Staining intensity for procollagen was weaker in subepithelial and deep connective tissues. In the interdental papilla, staining intensity for procollagen was strong and homogenous throughout the connective tissue, although expression may have

been slightly muted in the basement membrane zone (Figure 6). Fibronectin-EDA was localized on collagen fiber bundles in the marginal gingiva. A moderate staining intensity was present at the basement membrane zone and in deep connective tissues (Figure 6). In the interdental papilla, stronger staining was noted throughout the connective tissue and areas of intense staining for fibronectin-EDA corresponded with the location of collagen fiber bundles. Fibronectin-EDB was not expressed in marginal gingiva (Figure 6). In contrast, expression was strong in the basement membrane zone of the interdental papilla, with mild to moderate expression in subepithelial and deep connective tissues, respectively (Figure 6). Tenascin-C was localized to the basement membrane zone and the superficial aspects of the subepithelial connective tissue in the marginal gingiva and interdental papilla (Figure 6). However, expression of tenascin-C was also observed in the deep connective tissue in the papilla, where it co-localized with collagen fiber bundles (Figure 6). In marginal gingiva and interdental papilla, only cell associated staining was present for TGF- $\beta_{1,2,3}$, CTGF and SOS-1 (Figure 7).

Table 7. Relative immunostaining intensity in the connective tissue extracellular matrix in healthy marginal gingiva and healthy papilla.

	Marginal Gingiva			Interdental Papilla		
	BMZ	SECT	DCT	BMZ	SECT	DCT
Decorin	-	+++	++	-	+++	+++
Biglycan	-	+	+	-	+	++
Fibromodulin	-	++	+++	-	+	++
Lumican	-	++	++/+++	-	+	+
Procollagen	++	+	+	++	+++	+++
FN-EDA	++	-	++	++	++/+++	++/+++
FN-EDB	-	-	-	+++	+	++
Tenascin-C	+++	++	-	+++	++	++

SECT: subepithelial connective tissue; DCT: deep connective tissue; BMZ: basement membrane zone. The relative staining intensities are indicative of each molecule at different tissue locations, rather than between different molecules.

5.1.3 Cell associated staining of target molecules in marginal gingiva and papilla

Although the molecules investigated may have been expressed in the extracellular matrix, some were also associated with connective tissue cells, namely fibroblasts and blood vessels (Table 8). The relative cell associated staining intensity for molecules of interest were compared between the marginal gingiva and papilla. Blood vessels and fibroblasts stained weakly for lumican in both gingival anatomic locations. In marginal gingiva, biglycan showed moderate immunoreactivity in blood vessels and mild in fibroblasts. Staining intensity was stronger for biglycan in blood vessels of the interdental papilla compared to marginal gingiva (Figure 5). Blood vessels and fibroblasts showed weak immunoreactivity for fibromodulin in both anatomical areas (Figure 5); however, there were also blood vessels in the papilla that were negative for fibromodulin (Table 8). Localized fibroblasts and blood vessels positive for procollagen were present in the marginal gingiva and papilla; however, fibroblasts were stained stronger in the papilla (Figure 6). Fibronectin-EDA showed strong immunoreactivity for blood vessels and weak for fibroblasts of the marginal gingiva. Staining intensity was similar for blood vessels, but stronger for fibroblasts of the interdental papilla than marginal gingiva (Figure 6). Fibronectin-EDB was not associated with cells in the marginal gingival connective tissue; however, blood vessels and fibroblasts stained positive for fibronectin-EDB in the papilla (Figure 6). Blood vessels in marginal gingiva and papilla stained strongly for tenascin-C, but fibroblasts were negative. In marginal gingiva, TGF- $\beta_{1,2,3}$ was localized to select blood vessels, but not to fibroblasts. However, both cell types showed moderate immunoreactivity for TGF- $\beta_{1,2,3}$ in the papilla (Figure 7). CTGF and SOS-1 were localized to fibroblasts and blood vessels of the marginal gingiva and papilla, but staining intensity was stronger in the interdental papilla (Figure 7).

Table 8. Relative staining intensity of fibroblasts and blood vessels in healthy marginal gingiva and interdental papilla.

	Marginal Gingiva		Interdental Papilla	
	FBL	BV	FBL	BV
Biglycan	+	++	+	+++
Fibromodulin	+	+	+	-/+
Lumican	+	+	+	+
Procollagen	+	+	++	+
FN-EDA	+	+++	++	+++
FN-EDB	-	-	+	++
Tenascin-C	-	+++	-	+++
TGFβ_{1,2,3}	-	+	++	++
CTGF	+	++	+++	++
SOS-1	+	++	+++	+++

FBL: fibroblast; BV: blood vessel.

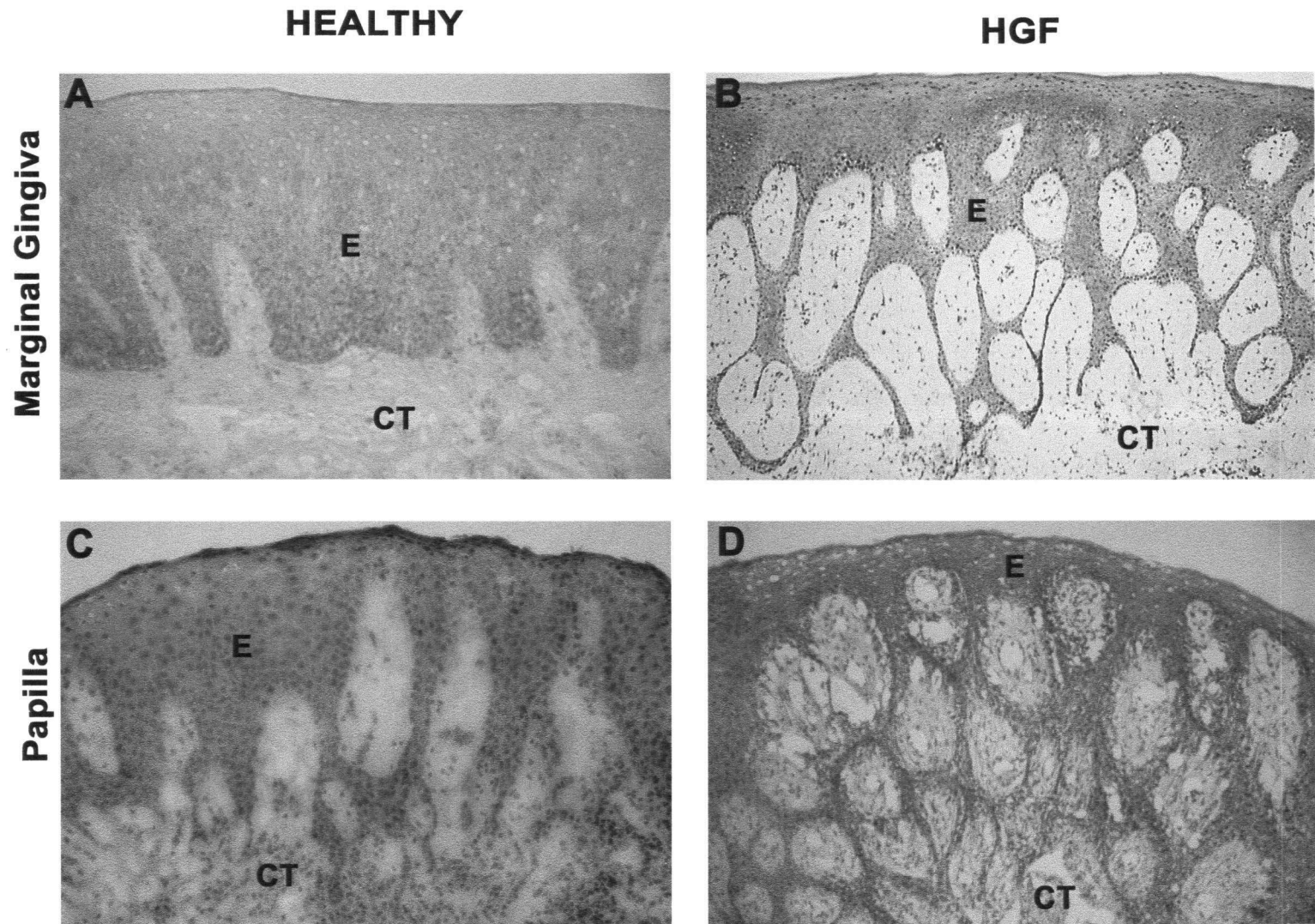


Figure 3. Hematoxylin & Eosin staining of the marginal gingiva (A and B) and interdental papilla (C and D) from healthy tissues (A and C) and hereditary gingival fibromatosis (B and D). In hereditary gingival fibromatosis, epithelial rete ridges are elongated in the marginal gingiva (B) and the interdental papilla (D). E = epithelium; CT = connective tissue

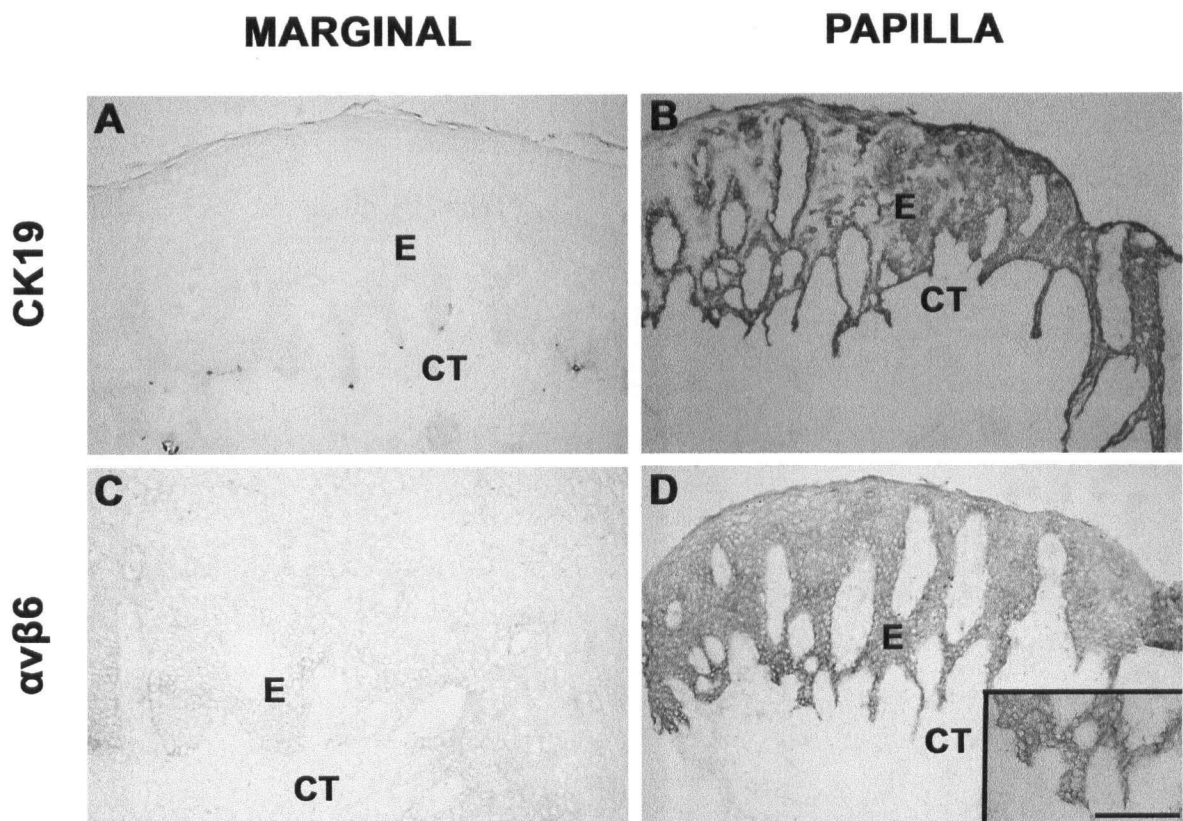


Figure 4. Immunostaining of cytokeratin 19 (CK19; A and B) and $\alpha v \beta 6$ integrin (C and D) in healthy marginal gingiva (A and C) and interdental papilla (B and D). E = epithelium; CT = connective tissue. Bar 100 μ m.

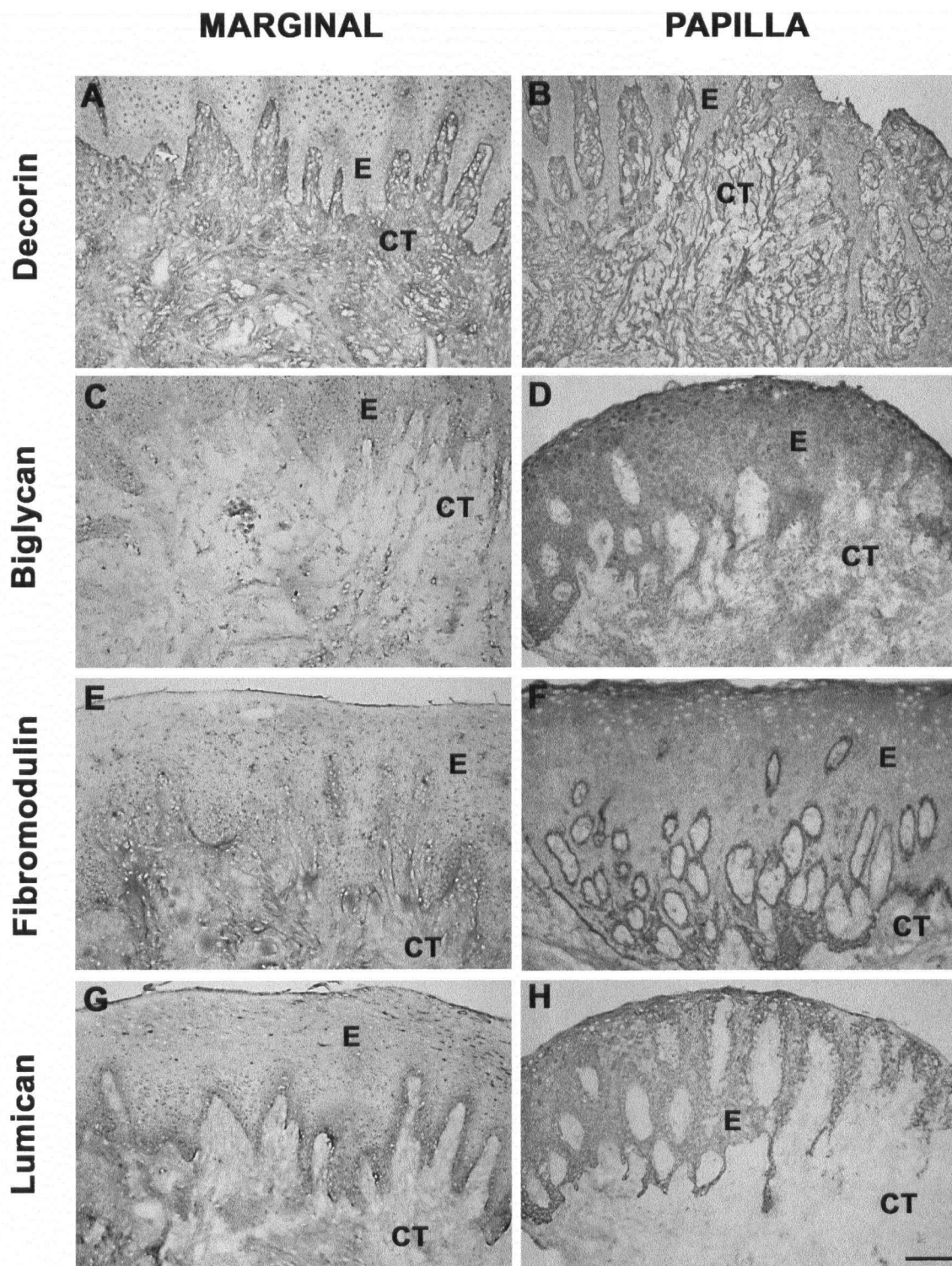


Figure 5. Immunolocalization of decorin (A and B), biglycan (C and D), fibromodulin (E and F) and lumican (G and H) in healthy marginal gingiva (A, C, E and G) and interdental papilla (B, D, F and H). E = epithelium; CT = connective tissue. Bar 100 μ m

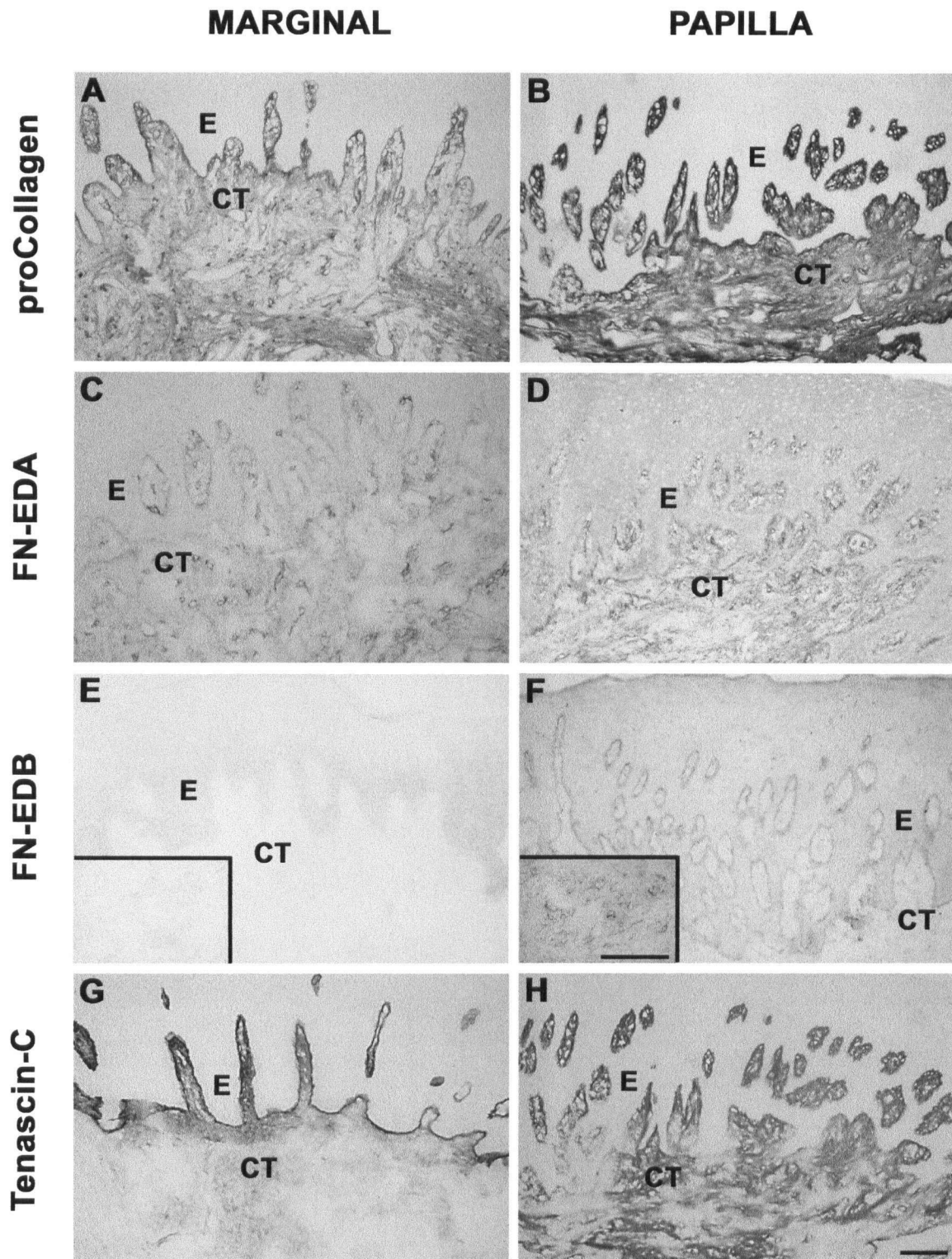


Figure 6. Immunohistochemical staining of procollagen (A and B), fibronectin-EDA (FN-EDA; C and D), fibronectin-EDB (FN-EDB; E and F) and tenascin-C (G and H) in healthy marginal gingiva (A, C, E and G) and healthy papilla (B, D, F and H). E = epithelium; CT = connective tissue. Bar 100µm

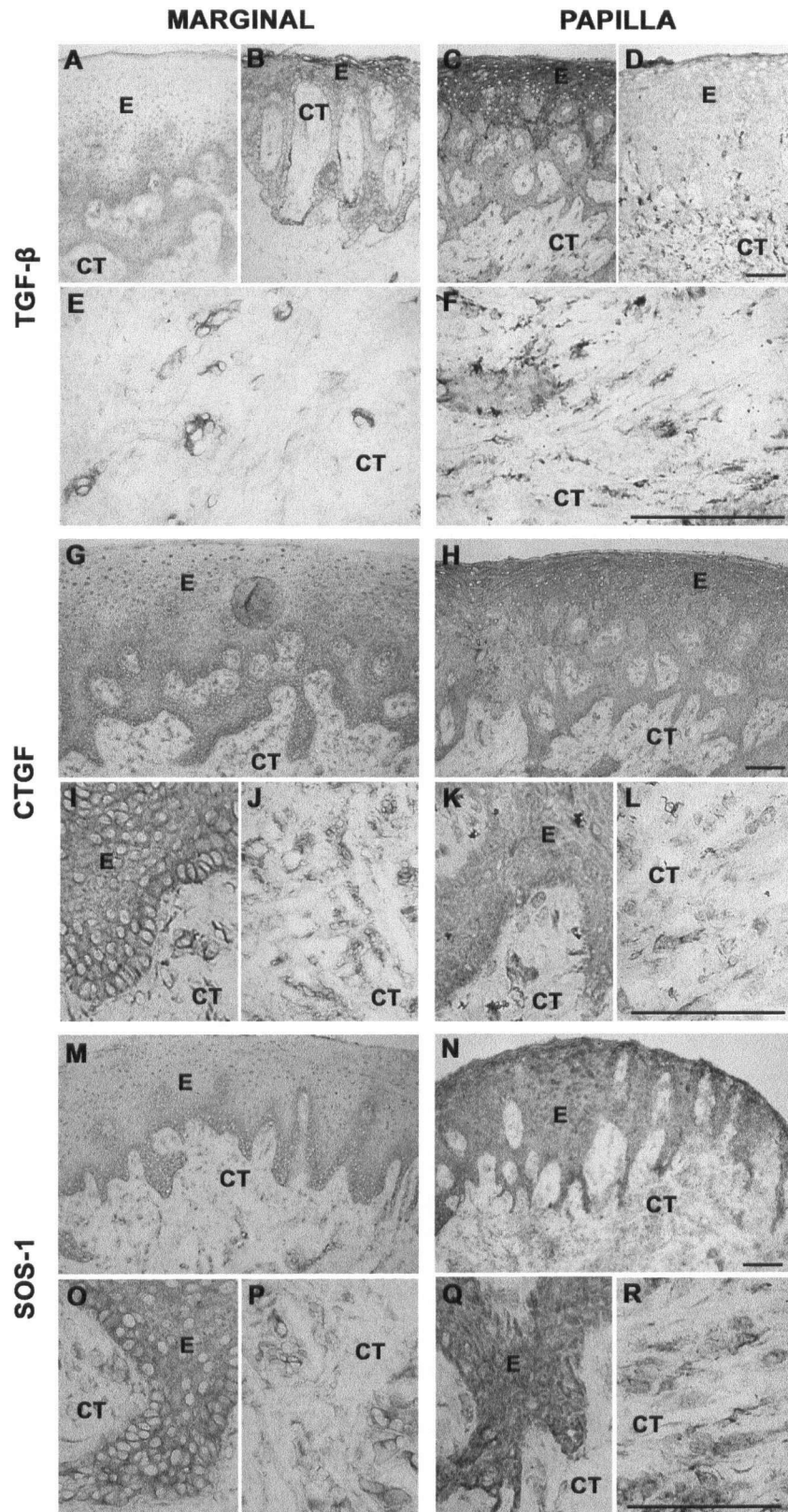


Figure 7. Localization of TGF- β (A-F), connective tissue growth factor (CTGF; G-L) and SOS-1 (M-R) in healthy marginal gingiva (A, B, E, G, I, J, M, O and P) and interdental papilla (C, D, F, H, K, L, N, Q and R). E=epithelium; CT=connective tissue. Bar 100 μ m

5.2 Comparison of marginal gingiva in health versus HGF

Immunostaining was used to determine similarities and differences in expression of molecules of interest between marginal gingiva in health and HGF (Table 9, 10 and 11). In the present experiment, comparisons were limited to healthy and HGF marginal gingival tissues, whose origin was determined on the basis of clinical information of where biopsies were obtained from and our morphological criteria. Although HGF can manifest in marginal gingiva and interdental papilla, samples obtained from either location differed on a histological level from healthy tissues (Figure 3).

In health, the oral epithelium of marginal gingiva had short, wide rete ridges of even lengths. Epithelium in HGF appeared dense and was characterized by elongated rete ridges that were relatively longer than those seen in healthy papilla (Figure 3). Connective tissues were comprised of thick bundles of interlacing collagen fibers in health. In HGF, random interwoven bundles of collagen fibers were also present, but were more dense and numerous. Furthermore, collagen bundles were occasionally oriented parallel to one another. Marginal gingiva had relatively similar number of blood vessels and fibroblasts in health and HGF; however, there were relatively fewer numbers of fibroblasts per collagen bundle in HGF. Although there was no inflammation noted in healthy marginal samples (Figure 3A), a mild localized inflammatory infiltrate was present in a proportion of HGF marginal biopsies (Figure 3B). Only samples with minimal inflammatory cell infiltrates were used for immunostaining.

5.2.1 Characterization of the epithelium in health and HGF

Key differences were present in the expression of target molecules in marginal gingival epithelium in health versus HGF (Table 9). In health, CK19 was occasionally seen in localized basal cells, but its expression was otherwise absent (Figure 8). CK19 was strongly expressed in the basal cells of 15 out of 15 marginal gingival HGF samples. However, in 2 of these 15 samples, only isolated positive cells located at the tips of rete ridges could be found (Figure 8). The epithelial integrin $\alpha\beta6$ was not expressed in health. Localized expression of integrin $\alpha\beta6$ was evident in basal cells, at tips of rete ridges in 14 out of 15 HGF samples (Figure 8). In health, biglycan expression was strongest in basal cells, with some immunoreactivity also present in the stratum spinosum (Figure 9). In HGF, there was a similar distribution of biglycan expression, but the staining intensity was stronger. Furthermore, localized cells in the stratum granulosum also stained positive for biglycan (Figure 9). Immunostaining intensity for fibromodulin was weak in the basal and immediate suprabasal cells in health. There was no fibromodulin localized to the stratum granulosum. Compared to health, fibromodulin expression in HGF was very pronounced in basal cells, creating the appearance of a “string of beads” (Figure 9); however, suprabasal cell layers were negative. In healthy marginal gingiva, staining intensity for lumican was moderate in stratum basale, mild in stratum spinosum and absent in stratum granulosum (Figure 9). There was a similar expression pattern in HGF, but staining intensity was consistently stronger (Figure 9). Decorin (Figure 9), procollagen (Figure 10), fibronectin-EDA (not shown), fibronectin-EDB (Figure 10) and tenascin-C (Figure 10) were not expressed in the oral epithelium of marginal gingiva in health or HGF. As discussed previously, there were two distinct patterns of TGF- $\beta_{1,2,3}$ expression in health. In 4 out of 7 healthy marginal gingival

samples, localization was restricted to basal cells and 2-3 suprabasal cell layers, while in the remaining 3 samples expression was strong at the cell membrane facing the basement membrane with additional immunoreactivity in the stratum spinosum and stratum granulosum (Figure 7). However, in HGF, 15 out of 15 tissue samples were homogeneous for only one of these staining patterns. Strong immunoreactivity for TGF- $\beta_{1,2,3}$ was present in the cell membranes facing the basement membrane and all suprabasal layers, but there was minimal expression in other areas of basal cells (Figure 11). At the tips of rete ridges TGF- $\beta_{1,2,3}$ immunoreactivity localized to all cell membranes of the basal cells. Compared to health, TGF- $\beta_{1,2,3}$ staining intensity was stronger in HGF (Table 9). In health, CTGF was strongly expressed by basal cells and weakly by cells of the immediate suprabasal layers, while the other cell layers were negative (Figure 11). In HGF, immunoreactivity for CTGF was relatively strong in stratum basale, spinosum and granulosum. SOS-1 was localized to basal cells in health, but was expressed throughout the oral epithelium in HGF. Specifically, SOS-1 expression in HGF was strong in basal cells, weak in stratum spinosum and moderate in stratum granulosum (Figure 11).

Table 9. Summary of differences between healthy and HGF marginal epithelium.

	Health			HGF		
	SG	SS	BC	SG	SS	BC
CK19	-	-	-	-	-	+++
Integrin $\alpha v \beta 6$	-	-	-	-	-	-/++LC
Biglycan	-	+	++	++/+++LC	++	+++BM LC
Fibromodulin	-	-/+	+	-	-	+++
Lumican	-	+	++	-	++LC	++/+++
TGF$\beta_{1,2,3}$	-/++	-/++	+/+++BM	++/+++	++/+++	-BC; +++BM
CTGF	-	+	+++	++	+/++	++BM
SOS-1	-	-	++	+/++	-/+	++/+++

BM: cell membrane facing basement membrane; BC: basal cells; SG: stratum granulosum; SS: stratum spinosum; LC: localized. The relative staining intensities are indicative of each molecule at different tissue locations, rather than between different molecules.

5.2.2 Characterization of the connective tissue in health and HGF

Differences between healthy and HGF marginal gingiva were also noted in the connective tissue (Table 10 and 11). CK19 and $\alpha v \beta 6$ integrin were not expressed in the oral connective tissue of healthy and HGF marginal gingiva (Figure 8). There were no differences in staining intensity for decorin in healthy versus HGF marginal gingiva (Figure 9 and Table 10). However, HGF was characterized by more abundant localization of decorin on collagen bundles than seen in health (Figure 9). Biglycan was weakly expressed throughout the connective tissue in health. Staining intensity for biglycan was more pronounced in HGF, being strongest in the deep connective tissue, where it associated with collagen fiber bundles (Figure 9). Staining intensity for fibromodulin was moderate subjacent to the epithelium and more pronounced in deep connective tissue in health and HGF (Figure 9). Irrespective of health or disease, immunoreactivity for lumican was moderate in subepithelial and strongest in deep connective tissue of marginal gingiva (Figure 9). However, the overall staining intensity was stronger in HGF, where it was associated with collagen fiber bundles. In healthy marginal gingiva, procollagen was moderately expressed at the basement membrane zone, with weaker expression in the subepithelial and deep connective tissue. Staining intensity was increased in HGF, except the basement membrane zone, which remained negative (Figure 10). Expression pattern and staining intensity for fibronectin-EDA was similar in health and HGF. Fibronectin-EDA was localized on collagen fiber bundles, with moderate expression at the basement membrane zone and in deep connective tissues (not shown). Although absent from healthy marginal connective tissue, fibronectin-EDB was strongly expressed in the basement membrane zone, as well as the subepithelial and deep connective tissues in HGF (Figure 10). Tenascin-C was strongly expressed in the

extracellular matrix immediately beneath the basement membrane in healthy and HGF marginal gingiva. Intense staining was also noted in deep connective tissue in HGF (Figure 10). In health and disease, cell associated staining was noted for TGF- $\beta_{1,2,3}$, CTGF and SOS-1 (Figure 11).

Table 10. Summary of differences between healthy and HGF marginal connective tissue.

	Health			HGF		
	BMZ	SECT	DCT	BMZ	SECT	DCT
Decorin	-	+++	++	-	+++	++
Biglycan	-	+	+	-	++	+++
Fibromodulin	-	++	+++	-	++	+++
Lumican	-	++	++/+++	-	++/+++	+++
Procollagen	++	+	+	-	+++	++
FN-EDA	++	-	++	++	-	++
FN-EDB	-	-	-	+++	++	++/+++
Tenascin-C	+++	++	-	+++	+++	+++

SECT: subepithelial connective tissue; DCT: deep connective tissue; BMZ: basement membrane zone. The relative staining intensities are indicative of each molecule at different tissue locations, rather than between different molecules.

5.2.3 Cell associated staining of target molecules in healthy and HGF marginal gingiva

Some molecules investigated also demonstrated cell associated staining (Table 11). A comparison was made between the relative staining intensity of blood vessels and fibroblasts positive for molecules of interest in healthy and HGF marginal gingiva. In health, biglycan showed moderate immunoreactivity in blood vessels and mild in fibroblasts. Staining intensity in blood vessels was similar in HGF, but fibroblasts were stained stronger (Figure 9). Fibromodulin expression in both cell types was weak in health and more pronounced in HGF (Table 11). Lumican showed weak staining in fibroblasts and blood vessels in health and moderate in HGF (Table 11). Blood vessels and fibroblasts were immunoreactive for procollagen in health and HGF; however, staining intensity was consistently stronger in HGF (Figure 10). In health and HGF, fibroblasts stained weakly and blood vessels strongly for fibronectin-EDA (Table 11). In contrast to health, where no cell associated staining was noted for fibronectin-EDB, blood vessels and fibroblasts were strongly positive in HGF (Figure 10). Fibroblasts were negative for tenascin-C and blood vessels were stained strongly in health and disease (Figure 10). There was weak immunoreactivity for TGF- $\beta_{1,2,3}$ in healthy marginal blood vessels, but not fibroblasts. However, both cell types had a moderate staining intensity for TGF- $\beta_{1,2,3}$ in HGF (Figure 11). Cell associated staining for CTGF and SOS-1 were similar. In health, fibroblasts stained weakly and blood vessels moderately positive for CTGF and SOS-1. In contrast, the staining intensity was stronger for both cell types in HGF marginal gingiva (Figure 11).

Table 11. Relative staining intensity of fibroblasts and blood vessels in health and HGF.

	Health		HGF	
	FBL	BV	FBL	BV
Biglycan	+	++	++	++
Fibromodulin	+	+	+/++	+/++
Lumican	+	+	++	++
Procollagen	+	+	++/+++	++
FN-EDA	+	+++	+	+++
FN-EDB	-	-	+++	+++
Tenascin-C	-	+++	-	+++
TGFβ_{1,2,3}	-	+	++	++
CTGF	+	++	+++	+++
SOS-1	+	++	+++	+++

FBL: fibroblast; BV: blood vessel.

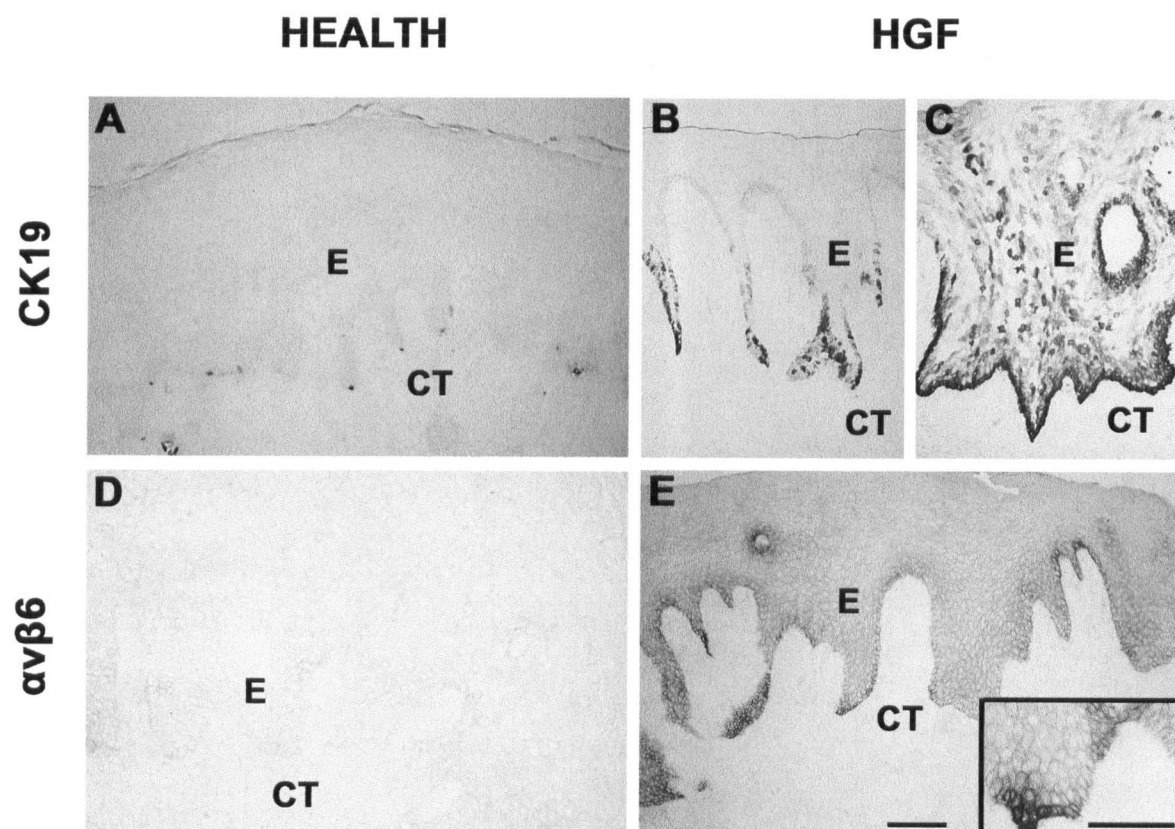


Figure 8. Expression of cytokeratin 19 (CK19; A-C) and $\alpha\text{v}\beta\text{6}$ integrin (D and E) in marginal gingiva in health (A and D) and hereditary gingival fibromatosis (B, C and E). E = epithelium; CT = connective tissue. Bar 100 μm

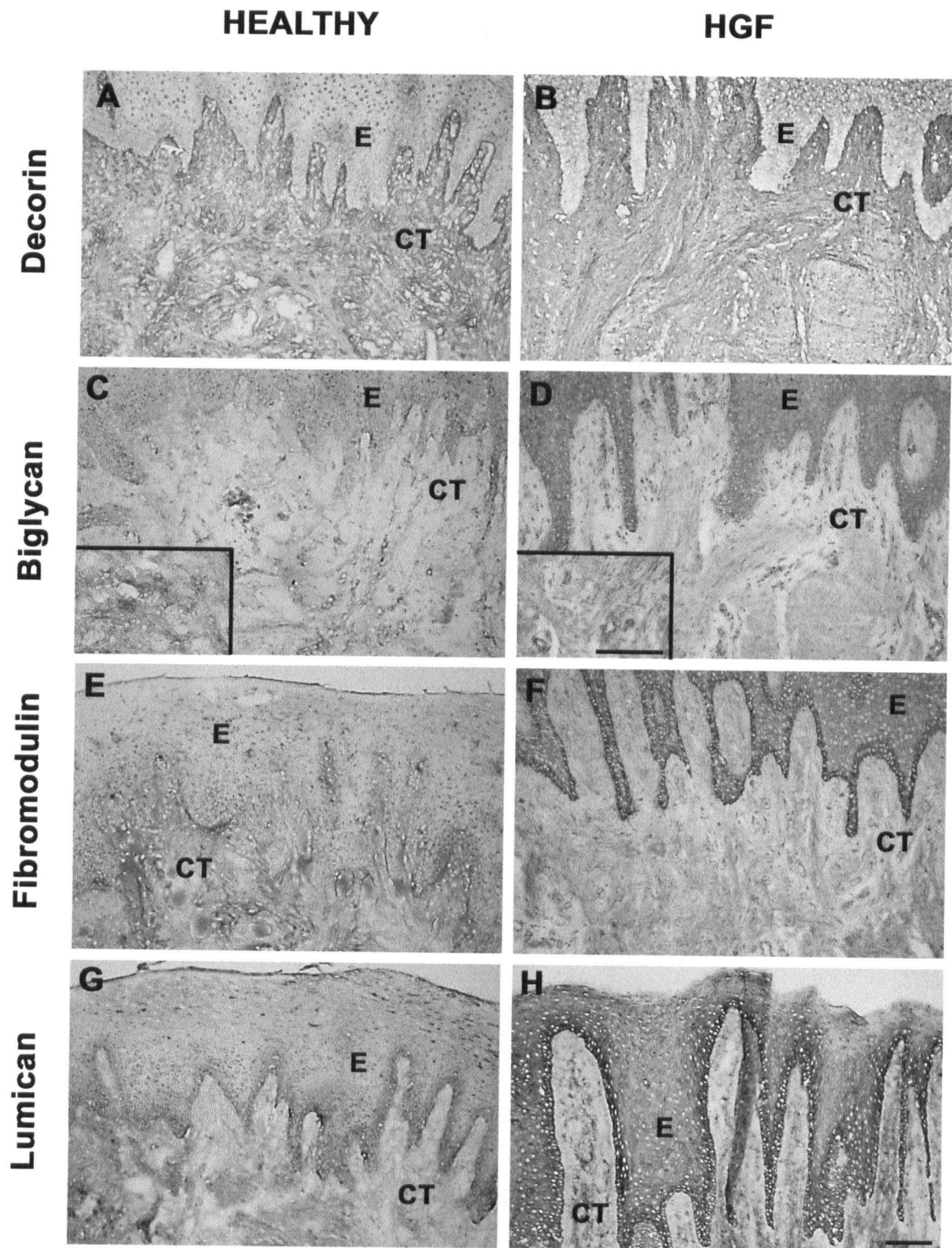


Figure 9. Localization of decorin (A and B), biglycan (C and D), fibromodulin (E and F) and lumican (G and H) in marginal gingiva in health (A, C, E and G) and hereditary gingival fibromatosis (B, D, F and H). E = epithelium; CT = connective tissue. Bar 100 μ m

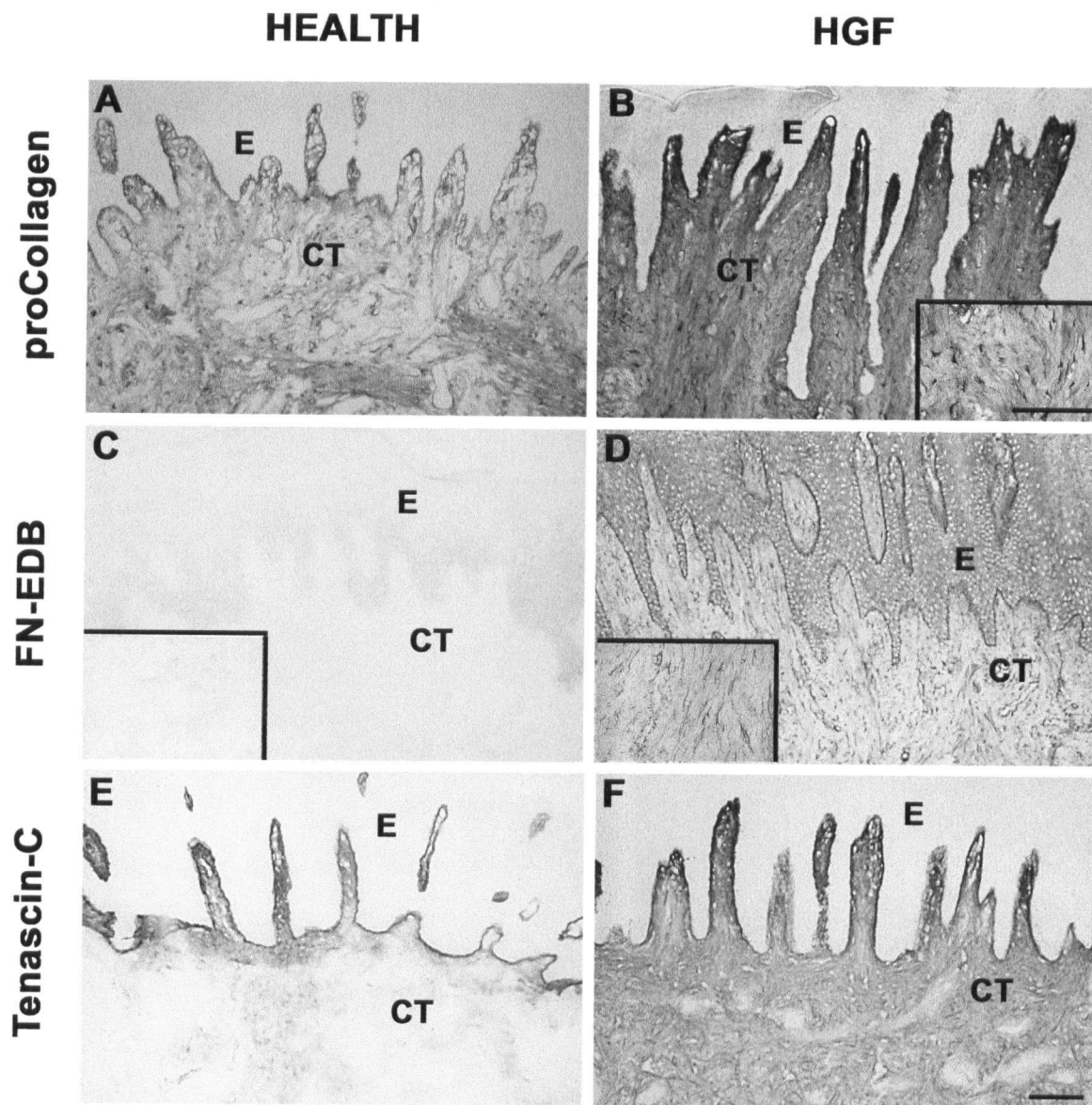


Figure 10. Immunostaining of procollagen (A and B), fibronectin-EDB (FN-EDB; C and D) and tenascin-C (E and F) in marginal gingiva in health (A, C and E) and hereditary gingival fibromatosis (B, D and F). E = epithelium; CT = connective tissue. Bar 100 μ m

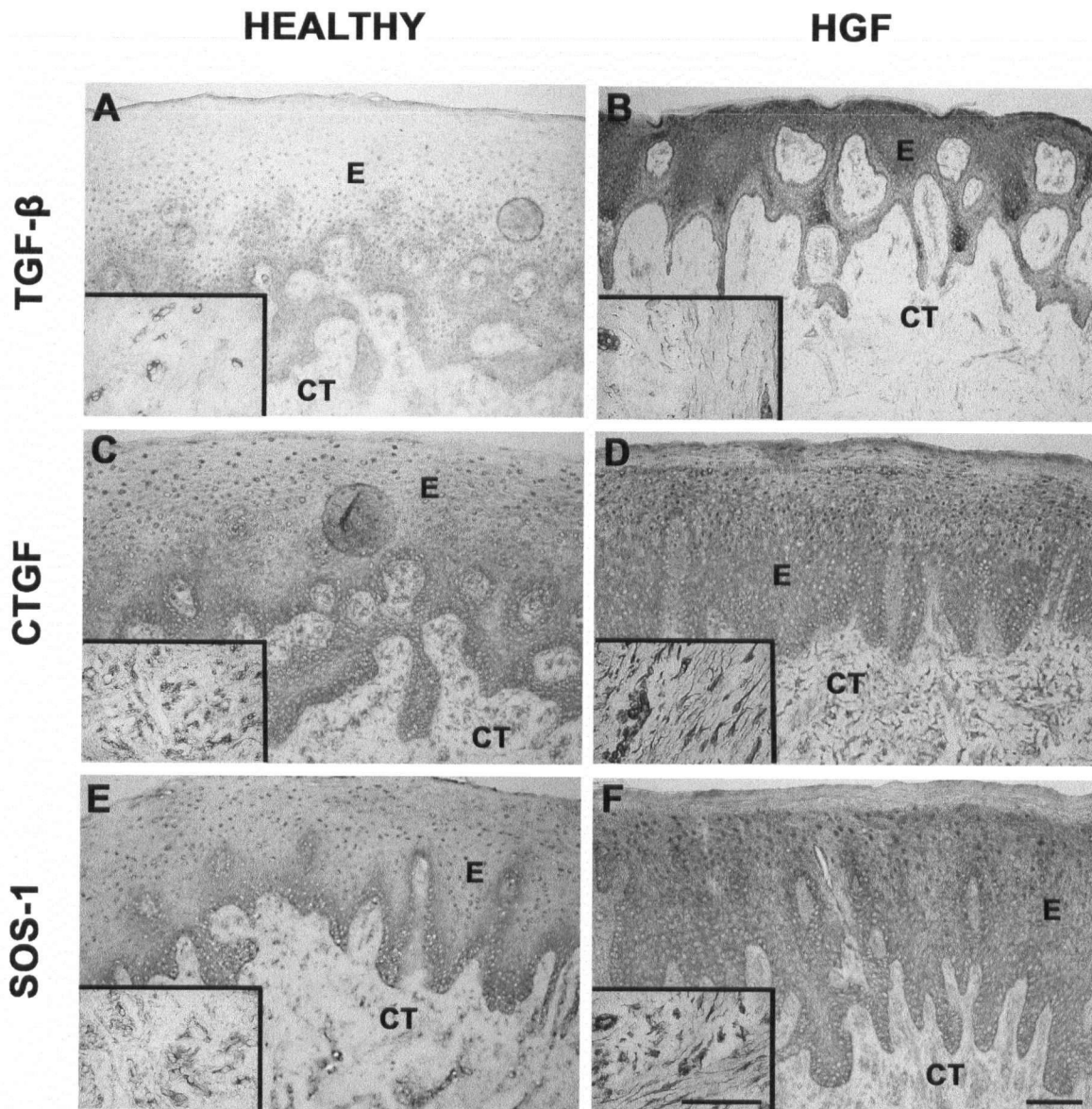


Figure 11. Immunohistochemical staining of TGF- β (A and B), CTGF (C and D) and SOS-1 (E and F) in marginal gingiva in health (A, C and E) and hereditary gingival fibromatosis (B, D and F). E = epithelium; CT = connective tissue. Bar 100 μ m

5.3 Wound healing in palatal attached gingiva

Palatal attached gingival samples obtained from two systemically healthy patients at 0, 3, 7, 14, 28 and 60 days post-wounding were immunostained for TGF- $\beta_{1,2,3}$, CTGF and SOS-1. The pattern of immunostaining of baseline biopsies (day-0) resembled that of healthy marginal gingiva. Although healthy papilla and marginal gingiva can exhibit two distinct staining patterns with TGF- $\beta_{1,2,3}$, only one pattern with strong basement membrane zone and suprabasal expression was observed in palatal biopsies (Figure 12). In palatal epithelium, SOS-1 and CTGF were most strongly expressed in cell membranes facing the basement membrane (Figure 12). In palatal connective tissue, there were numerous blood vessels positive for CTGF and SOS-1, with relatively fewer blood vessels positive for TGF- $\beta_{1,2,3}$.

Samples obtained three days post-wounding were characterized by an actively migrating epithelium and a fibrin clot rich in inflammatory cells (Figure 13). TGF- $\beta_{1,2,3}$ expression was evident throughout the migrating epithelial front. A similar pattern was also present for SOS-1. In contrast, CTGF showed strongest immunoreactivity at the cell membrane facing the connective tissue in basal cells next to the wound. TGF- $\beta_{1,2,3}$ and SOS-1 expression were upregulated in the connective tissue cells next to the fibrin clot. Inflammatory cells in the fibrin clot also showed strong immunoreactivity for SOS-1.

Epithelial migration was complete by day 7 post-wounding (Figure 14). The wound bed had been covered by epithelium; however, rete pegs had not yet formed. Granulation tissue was characterized by the presence of fibroblasts and endothelial cells. At the interface between the epithelium and granulation tissue, TGF- $\beta_{1,2,3}$, SOS-1 and CTGF

were all expressed in the cell membranes at the basal cells. CTGF and SOS-1 also showed some intracellular staining in the basal cells. There was no suprabasal staining with TGF- $\beta_{1,2,3}$, as seen in control samples (Figure 14). Strong expression of TGF- $\beta_{1,2,3}$ and SOS-1 was noted at the connective tissue and granulation tissue interface. Immunoreactivity for CTGF expression was low in this area (Figure 14).

Fourteen days after wounding, the wound was being actively remodeled and the granulation tissue had contracted to form a wound connective tissue. In the wounded epithelium, cell membranes facing the basement membrane continued to be stained with CTGF and SOS-1; however, TGF- $\beta_{1,2,3}$ expression was now nearly absent (Figure 15). None-the-less, TGF- $\beta_{1,2,3}$ expression was present in the surrounding non-wounded epithelium. Wound connective tissue cells immediately beneath the wound epithelium did not express TGF- $\beta_{1,2,3}$ or SOS-1, but they showed strong immunoreactivity for CTGF. In contrast, fibroblasts that were actively remodeling the deep wound connective tissue showed strong immunoreactivity for TGF- $\beta_{1,2,3}$, CTGF and SOS-1.

Epithelial thickness was normalized at twenty-eight days post wounding, but the rete pegs had not formed (Figure 16). In the wound epithelium, TGF- $\beta_{1,2,3}$ and SOS-1 expression was strong in the cell membranes facing the basement membrane, but there was no such expression pattern seen with CTGF. The presence of suprabasal staining with TGF- $\beta_{1,2,3}$ signified the beginning of normalization. CTGF and SOS-1 were relatively abundant in the fibroblasts in the wound connective tissue, but staining intensity of TGF- $\beta_{1,2,3}$ was very weak.

All epithelial components appeared histologically normalized and rete pegs had reformed by sixty days post wounding (Figure 17). Expression of TGF- $\beta_{1,2,3}$ and SOS-1 had normalized in the epithelium. Both these molecules were expressed in the cell membranes facing the basement membrane, while TGF- $\beta_{1,2,3}$ expression was also evident in the suprabasal cell layers, but not in other areas of basal cells. Expression of TGF- $\beta_{1,2,3}$ was minimal in the healthy unwounded connective tissue, being limited mostly to blood vessels. However, unlike normal unwounded tissue, wound connective tissue contained abundant blood vessels and fibroblasts immunoreactive for CTGF and SOS-1.

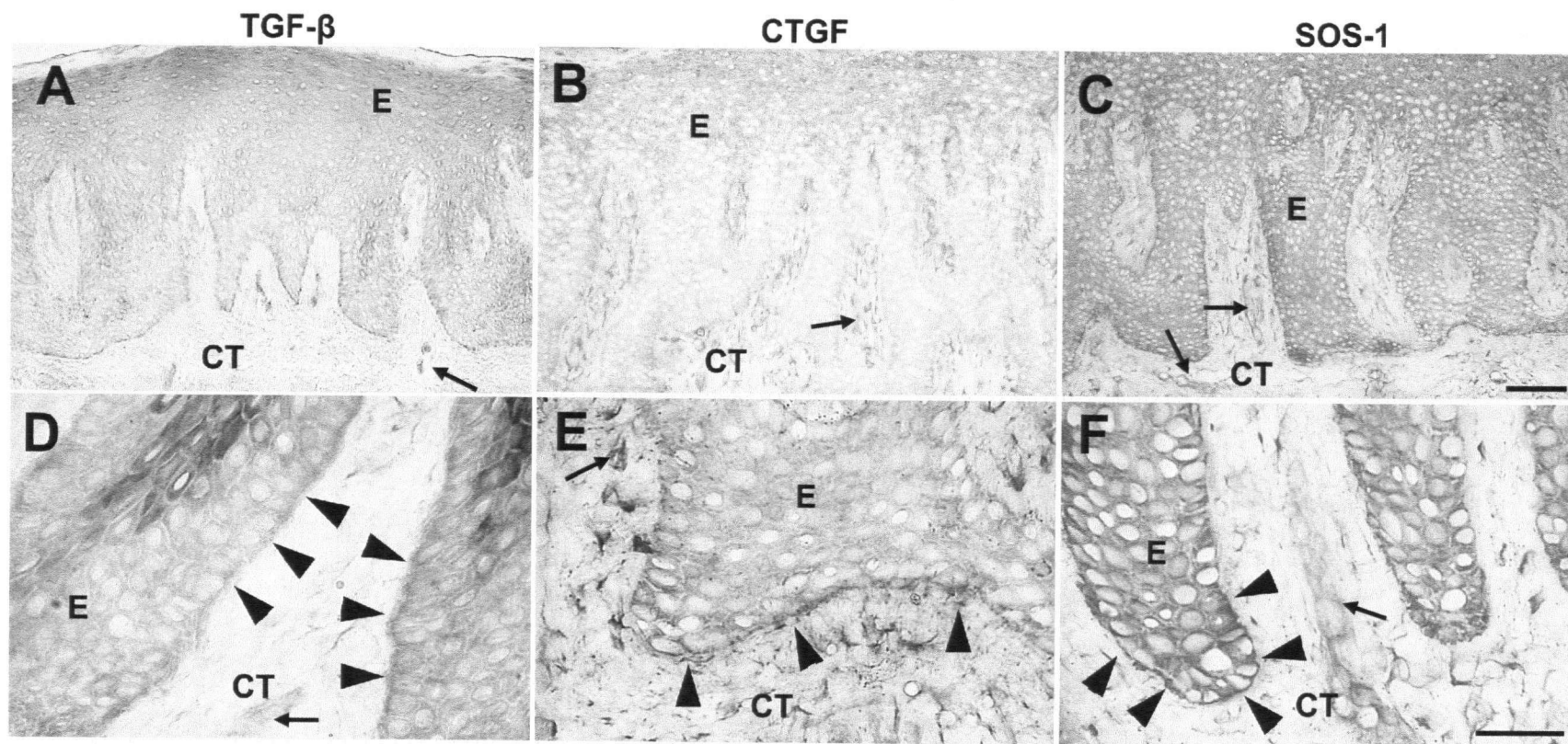


Figure 12. Baseline palatal gingiva - Day 0 (Control). Expression pattern of TGF- β (A and D), CTGF (B and E) and SOS-1 (C and F) in non-wounded palatal attached gingiva is similar to healthy marginal gingiva. D, E and F: Arrowheads indicate staining at the basal cell membrane facing the basement membrane. A, B and C: Arrows indicate blood vessels. E = epithelium; CT = connective tissue. Bar 100 μ m

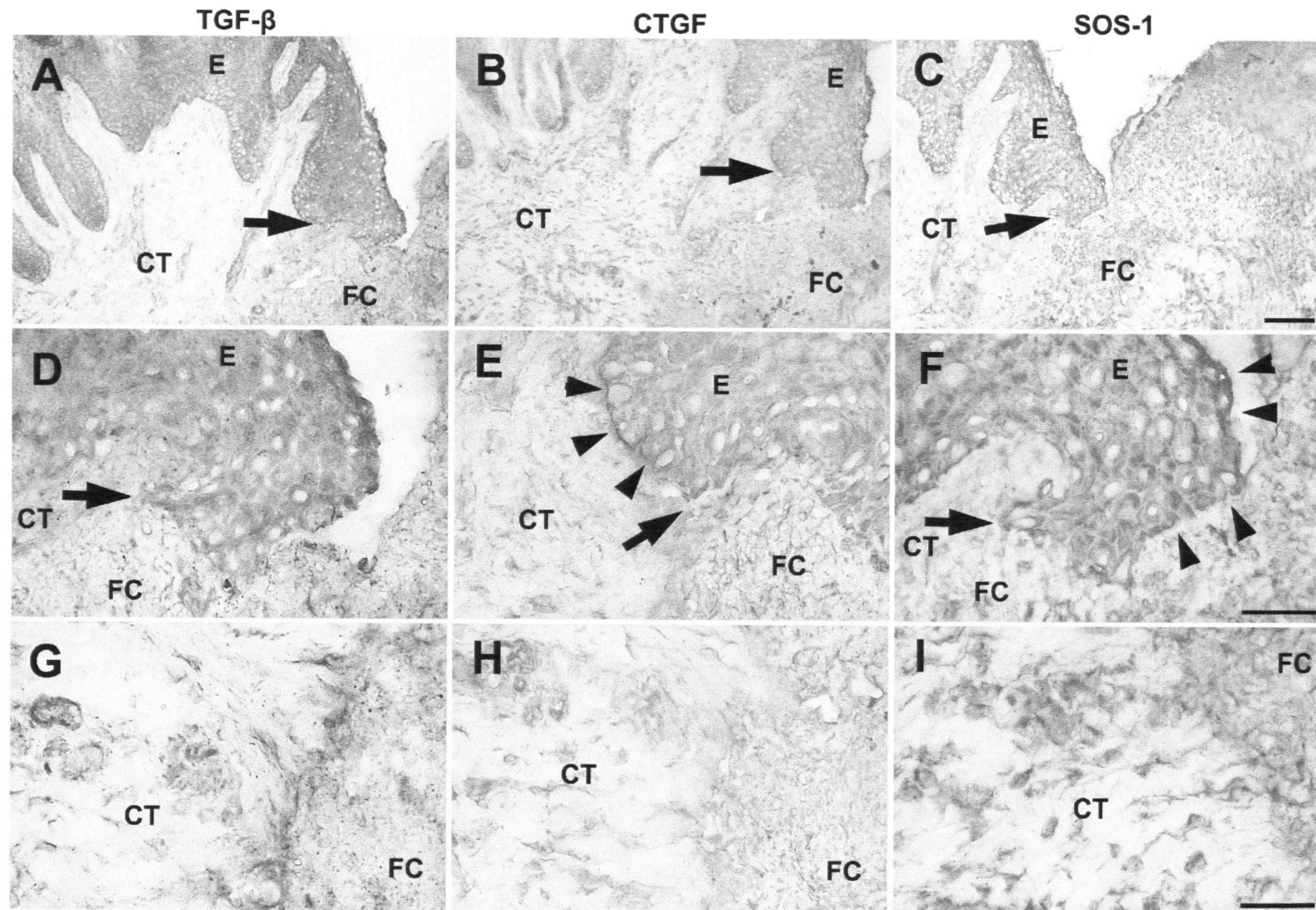


Figure 13. Expression pattern of TGF- β (A, D and G), CTGF (B, E and H) and SOS-1 (C, F and I) in palatal attached gingiva 3 days after wounding. A-F: Arrows indicate the wound edge. E and F: Arrowheads indicate localization of strong immunoreactivity at the epithelial cells. E = epithelium; CT = connective tissue; FC = fibrin clot. Bar 100 μ m

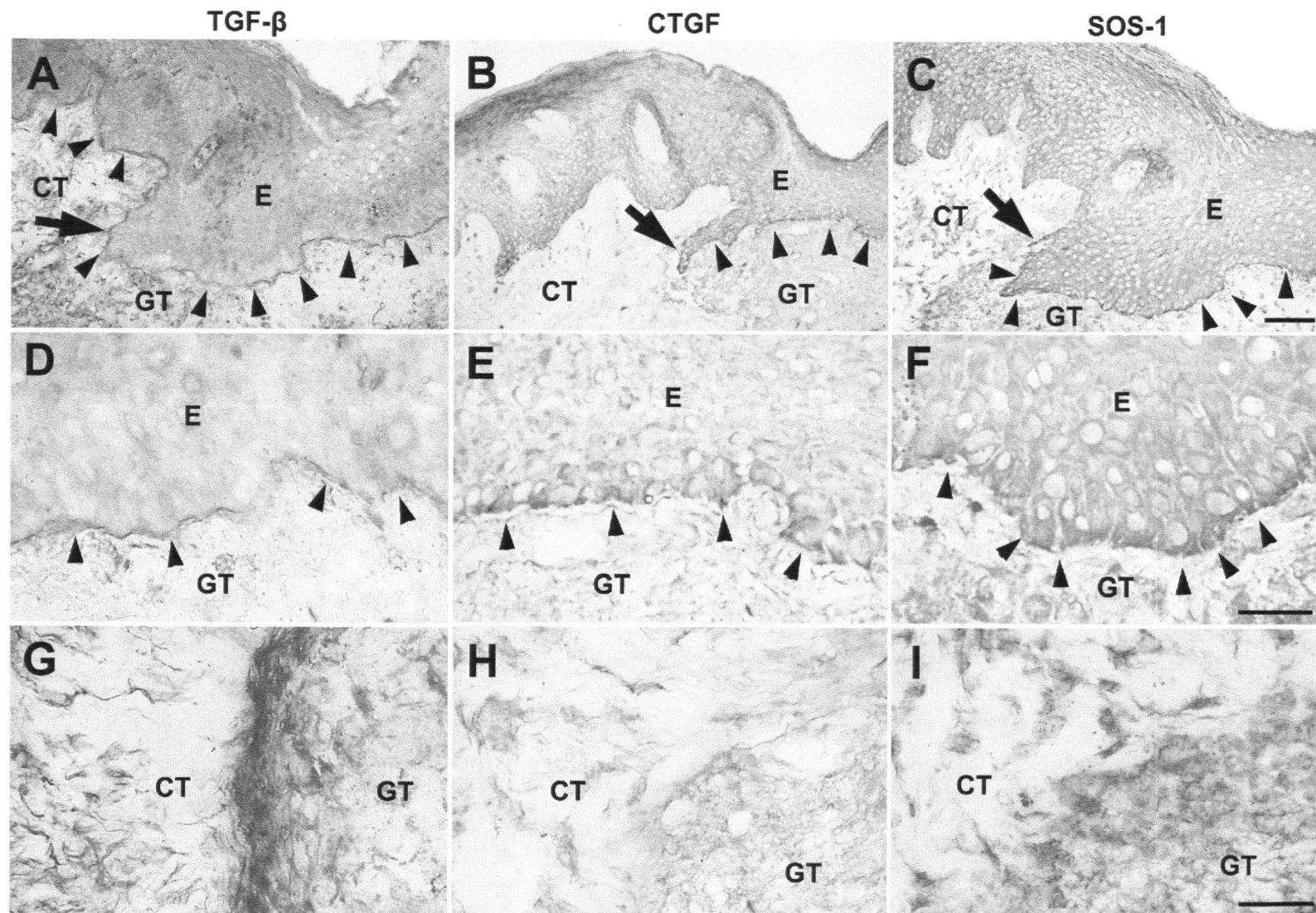


Figure 14. Localization of TGF- β (A, D and G), CTGF (B, E and H) and SOS-1 (C, F and I) in palatal attached gingiva on day 7 post wounding. A-C: Arrows indicate the wound edge. A-F: Arrowheads indicate staining at basal epithelial cells. E = epithelium; CT = connective tissue; GT = granulation tissue. Bar 100 μ m

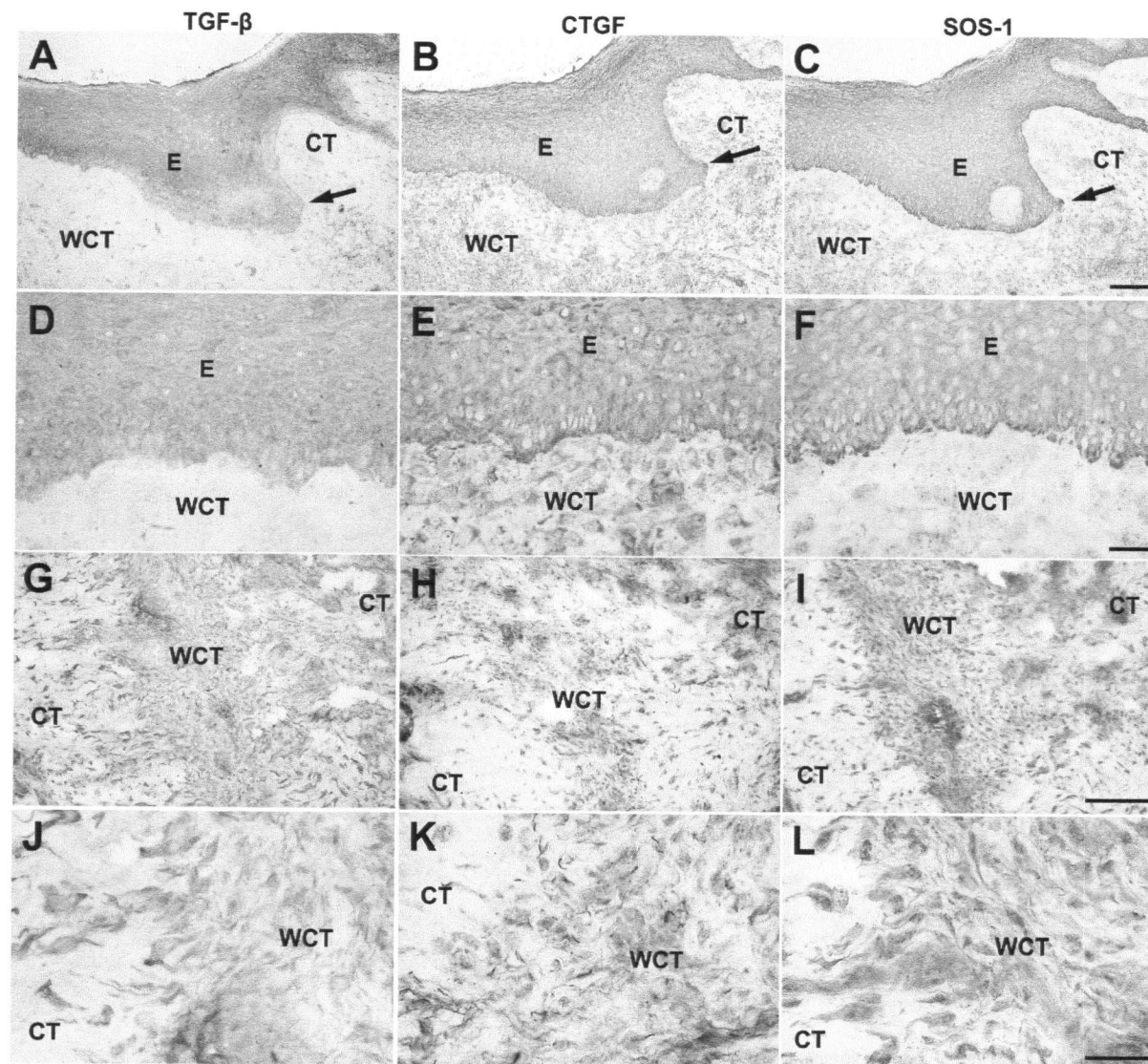


Figure 15. Expression pattern of TGF- β (A, D, G and J), CTGF (B, E, H and K) and SOS-1 (C, F, I and L) in palatal attached gingiva 14 days post wounding. A-C: Arrows indicate the wound edge. E = epithelium; CT = connective tissue; WCT = wound connective tissue. Bar 100 μ m

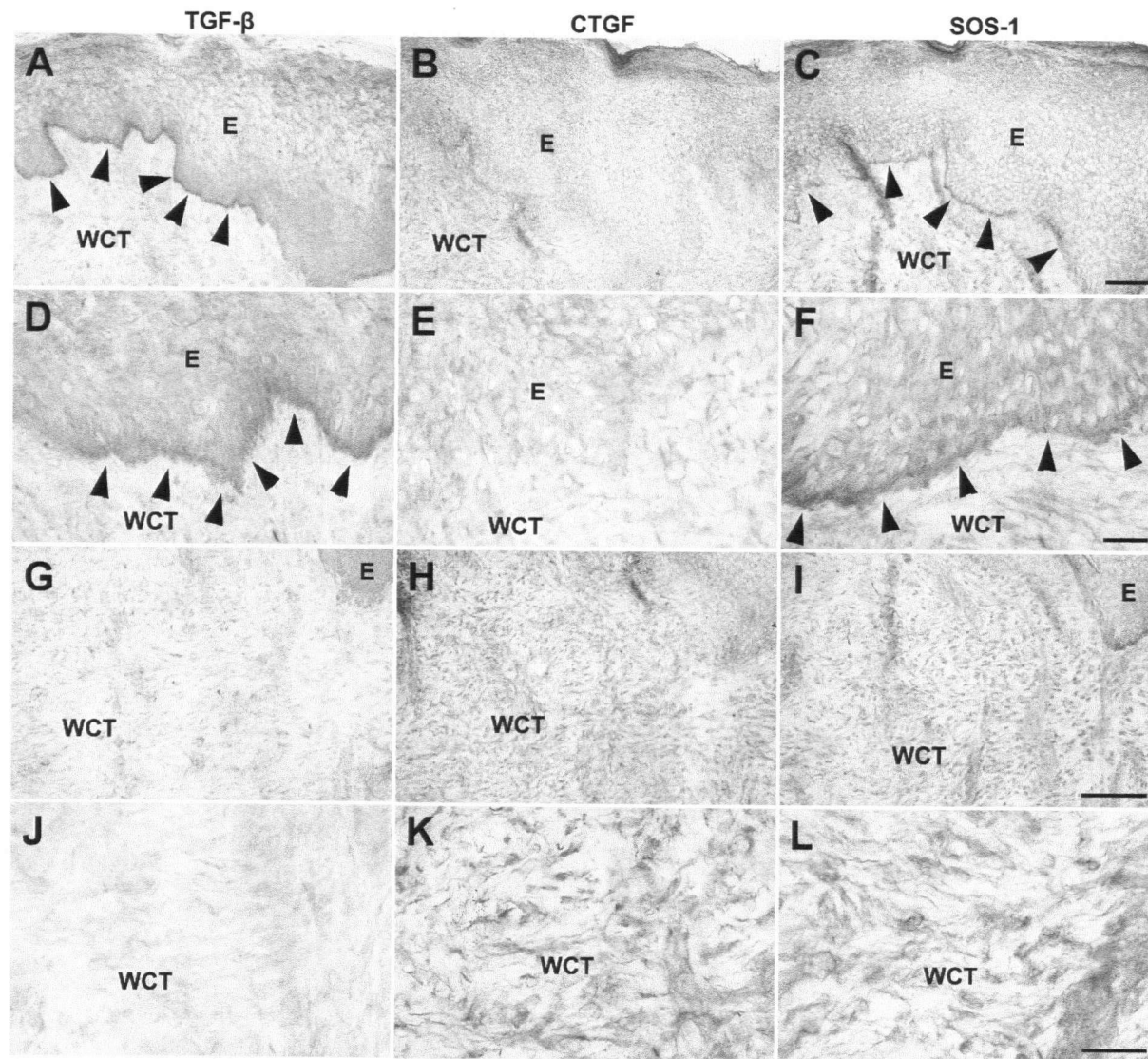


Figure 16. Expression pattern of TGF- β (A, D, G and J), CTGF (B, E, H and K) and SOS-1 (C, F, I and L) in palatal gingiva 28 days after wounding. A, C, D and F: Arrowheads indicate strong staining at the basal cells. E=epithelium; CT=connective tissue; WCT=wound connective tissue. Bar 100 μ m

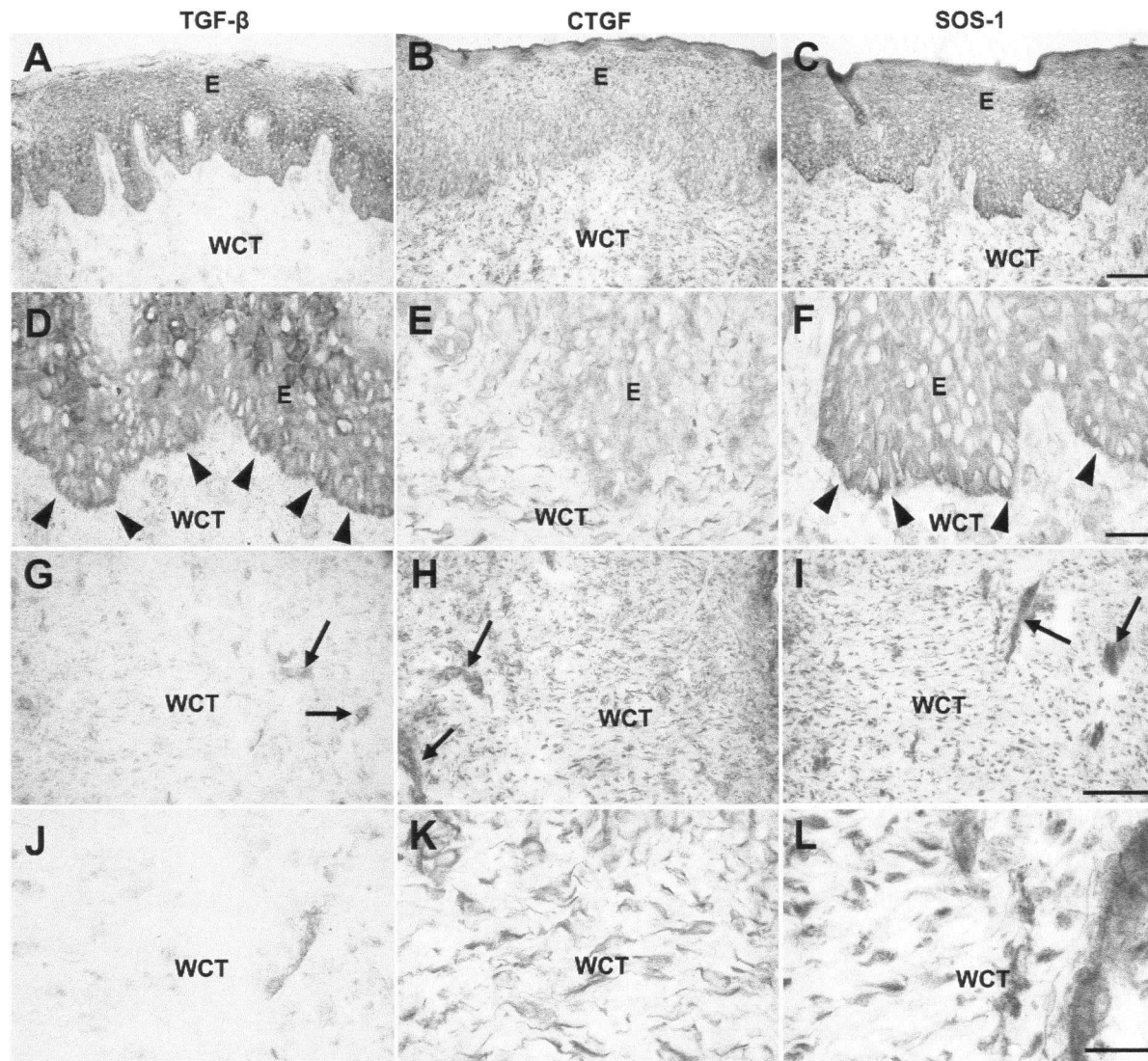


Figure 17. Localization of TGF- β (A, D, G and J), CTGF (B, E, H and K) and SOS-1 (C, F, I and L) in palatal gingiva 60 days post wounding. G-I: Arrows indicate blood vessels. D and F: Arrowheads indicate strong staining at basal cells. E = epithelium; CT = connective tissue; WCT = wound connective tissue. Bar 100 μ m

6 Discussion

6.1 Comparative analysis of marginal gingiva and interdental papilla in health

Healthy human interdental papilla presents with unique functional features that differentiate it from marginal gingiva. To determine whether the papilla has distinct molecular characteristics that serve as the basis for these differences, this study compared key molecules in the epithelium and connective tissue of buccal marginal gingiva and interdental papilla. CK19 was examined because it was found to be exclusively expressed in nonkeratinized sulcular and junctional epithelium (Dale *et al.*, 1990). Other molecules of interest were those normally absent from gingiva ($\alpha\text{v}\beta 6$ integrin and fibronectin-EDB), as well as ones that are upregulated during wound healing and regulate tissue development and regeneration (fibronectin-EDA, fibronectin-EDB, tenascin-C, TGF- β , CTGF and $\alpha\text{v}\beta 6$ integrin) (Hakkinen *et al.*, 2000a; Hakkinen *et al.*, 2000c; Larjava *et al.*, 2002). Procollagen and the small leucine-rich proteoglycans (decorin, biglycan, fibromodulin and lumican) were also studied, as they are important for extracellular matrix homeostasis (Alimohamad *et al.*, 2005; Hakkinen *et al.*, 1993; Hakkinen *et al.*, 2000b; Hakkinen and Csiszar, 2006 in press in press; Matheson *et al.*, 2005). Lastly, we immunolocalized SOS-1, an intracellular molecule that regulates key signaling cascades initiated from both growth factor receptors and integrin-type extracellular matrix receptors (Hakkinen and Csiszar, 2006 in press in press). SOS-1 was of particular interest because a mutation in a region coding for this gene eliminates the area responsible for maintaining the gene in a down-regulated state, rendering it active. The activated form of SOS-1 was found to be associated with gingival overgrowth seen in HGF (Dale *et al.*, 1990).

The present study confirmed that key molecular differences exist between the marginal gingiva and interdental papilla in health (Table 12). CK19 was immunolocalized in the epithelium of the papilla; however, only localized basal cells at tips of rete ridges stained positively in the marginal gingiva. In accordance with prior studies, areas of the papilla where CK19 was expressed throughout the epithelium corresponded to non-keratinized epithelium, namely sulcular and junctional epithelium (Dale *et al.*, 1990). However, it is also possible that CK19 expression in the epithelium may have been upregulated by the presence of inflammation (Ouhayoun *et al.*, 1990). Areas with staining limited to basal cell corresponded to epithelium of the interdental papilla. Integrin $\alpha\text{v}\beta 6$ was also expressed in the oral epithelium of the papilla, while it was absent in marginal gingiva. Compared to healthy marginal gingiva, the relative staining intensity of biglycan, fibromodulin, lumican, TGF- $\beta_{1,2,3}$, CTGF and SOS-1 was stronger in the papilla. Normally, CTGF is expressed by endothelial cells and fibroblasts and is not seen in the epithelium; however, CTGF can be expressed by keratinocytes in vitro.

Although differences exist in the expression of certain molecules in the epithelium of the interdental papilla and marginal gingiva, their functional roles have yet to be understood. By virtue of its location with respect to the cementoenamel junction, the interdental papilla has deeper probing depths compared to marginal gingiva. Furthermore, it is located near proximal tooth surfaces, which may be associated with root concavities that trap plaque. Such features surrounding the papilla create an environment that is more prone to inflammation than the marginal gingiva. In the present study, only areas with minimal inflammatory cell infiltrates were examined. Inflammation may contribute to increased CK19 expression (Ouhayoun *et al.*, 1990). Because CK19 expression was

observed throughout the epithelium of the papilla, it is possible that a mild inflammatory infiltrate in one area of the tissue may have affected more distant sites. Integrin $\alpha\beta6$ is not regulated by inflammation (Haapasalmi *et al.*, 1995), in fact, its expression is increased in gingival wounds when inflammation is reduced (Hakkinen *et al.*, 2000a). Thus, we can conclude that localization of $\alpha\beta6$ integrin in the papilla is a specific characteristic of the epithelium itself. One can further postulate that since $\alpha\beta6$ integrin, which is normally absent in health, was expressed in the epithelium of the interdental papilla, CK19 may also be present independent of inflammation. Integrin $\alpha\beta6$ is also expressed in gingival wounding (Haapasalmi *et al.*, 1996; Hakkinen *et al.*, 2000a) and can activate immunosuppressive TGF- β (Sheppard, 2005). In turn, active TGF- β can upregulate its own expression, as well as that of CTGF, in epithelium and connective tissue (Leask and Abraham, 2004; Leivonen *et al.*, 2005). Therefore, expression of $\alpha\beta6$ integrin in the epithelium of the papilla may be the cause of the increased epithelial and connective tissue cell associated staining of TGF- β and CTGF in the papilla relative to the marginal gingiva.

TGF- β plays a key role in the inflammatory response, and in conjunction with CTGF, it regulates extracellular matrix deposition, including expression of type I collagen (Frazier *et al.*, 1996). Since staining intensity for procollagen was stronger in the extracellular matrix of the papilla compared to the marginal gingiva, it is possible that TGF- β may have a similar function in the papilla. Yet another function of TGF- β , is to upregulate fibronectin-EDA, fibronectin-EDB and tenascin-C (Linnala *et al.*, 1995; Pearson *et al.*, 1988). Expression of these molecules was stronger in the connective tissue of the interdental papilla than the marginal gingiva. In fact, fibronectin-EDB was not expressed

in the marginal gingiva. This is an interesting finding since expression of these molecules is also induced during gingival wound healing (Hakkinen *et al.*, 2000a; Larjava *et al.*, 2002). Compared to marginal gingiva, epithelial and cell associated staining for SOS-1 was also upregulated in the papilla. SOS-1 mediates intracellular signaling cascades induced by growth factors and integrin-type cell adhesion receptors important in wound healing (Hakkinen and Csiszar, 2006 in press in press; Nimnual and Bar-Sagi, 2002). Hence it is not surprising that we found increased expression of SOS-1 in wounded epithelium and connective tissue. Increased expression of $\alpha v \beta 6$ integrin, TGF- β , CTGF, type I procollagen, fibronectin- EDA, fibronectin-EDB, tenascin-C and SOS-1 suggests that the interdental papilla resembles wound tissue.

Although previously described, the relevance of a stronger staining intensity for biglycan, fibromodulin and lumican in the epithelium of the papilla is not clear (Alimohamad *et al.*, 2005; Bianco *et al.*, 1990; Schaefer *et al.*, 2000). The small leucine-rich proteoglycans (decorin, biglycan, fibromodulin and lumican) regulate collagen fibrillogenesis in periodontal tissues and can serve as signaling molecules that regulate cell functions (Ameys and Young, 2002; Hildebrand *et al.*, 1994; Hocking *et al.*, 1998). In addition, decorin, biglycan and fibromodulin can inactivate TGF- β by binding to it (Hildebrand *et al.*, 1994). Decorin, biglycan, fibromodulin and lumican were strongly localized to collagen fiber bundles in the interdental papilla. Since these proteoglycans limit lateral growth of collagen fibrils (Ameys and Young, 2002; Hocking *et al.*, 1998; Matheson *et al.*, 2005), this may explain the presence of parallel thin collagen fiber bundles in the papilla, compared to the thick interwoven ones seen in marginal gingiva. Although the small leucine-rich proteoglycans were localized to collagen fibrils, the relative staining

intensity for fibromodulin and lumican was reduced in the connective tissue of the interdental papilla. Furthermore, expression of biglycan was increased and that of fibromodulin decreased in blood vessels of the papilla. Differences in expression of the small leucine-rich proteoglycans in the papilla compared to the marginal gingiva may result in unique cellular functions of the two anatomic locations.

Extent of interdental bone loss is also a determining factor for the limited regeneration ability of the interdental papilla (Zetu and Wang, 2005). If the vertical distance from the crestal bone to the interproximal contact between two teeth is greater than 5 mm, regeneration of the interdental papilla becomes unpredictable (Tarnow *et al.*, 1992). A similar finding was noted around single implant restorations (Choquet *et al.*, 2001). Furthermore, once the interdental papilla is lost as a result of disease or surgery, the surrounding marginal gingival cells may be unable to recreate the phenotypic properties of the cells inherent in the papilla. This may also contribute to the limited regeneration seen in the interdental papilla. Therefore, in addition to limiting the distance between the contact and alveolar bone crest, papilla preservation and regeneration should also focus on preserving the existing papilla as a source of specific cells during surgical procedures.

Table 12. Summary of expression of molecules of interest in the interdental papilla relative to marginal gingiva in health.

Antibody	Relative Expression			
	Interdental Oral Epithelium	ECM	FBL	BV
CK19	↑	0	0	0
Integrin $\alpha v \beta 6$	↑	0	0	0
Decorin	0	↑	0	0
Biglycan	↑	↑	-	↑
Fibromodulin	↑	↓	-	↓
Lumican	↑	↓	-	-
Procollagen	0	↑	↑	-
FN-EDA	0	↑	↑	-
FN-EDB	0	↑	↑	↑
Tenascin-C	0	↑	0	-
TGF- $\beta_{1,2,3}$	↑	0	↑	↑
CTGF	↑	0	↑	-
SOS-1	↑	0	↑	↑

↑: Upregulated; ↓: Down regulated; -: No change; 0: Not expressed; ECM: extracellular matrix; FBL: fibroblasts; BV: blood vessels.

6.2 Comparison of marginal gingiva in health and HGF

Healthy and HGF biopsies obtained from similar anatomic origins were compared. This was a unique feature of the study, as prior experimental designs did not differentiate between marginal gingiva and interdental papilla. Comparisons were made only between marginal gingival samples, as the number of biopsies obtained from HGF interdental papilla was limited. Structural and molecular differences were noted and found to be distinct.

The molecular phenotype of the marginal gingiva in health and HGF are distinct. CK19 was expressed in the epithelium in HGF, yet only localized tips of rete ridges were positive in healthy marginal gingiva. This was a novel finding, as CK19 expression has only been described in sulcular and junctional epithelium (Dale *et al.*, 1990). We have also described CK19 expression in healthy interdental papilla in this study. Integrin $\alpha\beta 6$, usually associated with gingival wound healing (Haapasalmi *et al.*, 1996; Hakkinen *et al.*, 2000a), was also immunolocalized to the epithelium in HGF, but was not present in healthy marginal gingiva. Inflammation is not a characteristic feature of gingival overgrowth (Shafer, 1983b); however, gingival pseudopocketing creates a favorable environment for bacterial accumulation and growth, and render oral hygiene difficult. Inflammation may prevail under such circumstances. Although we only examined biopsy samples with minimal inflammatory infiltrates, the possibility exists that a minute amount of localized inflammation may affect adjacent and/or distant tissues. As discussed previously, CK19 expression (Ouhayoun *et al.*, 1990), but not $\alpha\beta 6$ integrin may be upregulated by inflammation (Haapasalmi *et al.*, 1995). Since both molecules were

present in HGF, it is likely that CK19 and $\alpha\text{v}\beta 6$ integrin expression was independent of inflammation and likely an inherent characteristic of the epithelial cells.

Compared to healthy marginal gingiva, expression of TGF- β , CTGF and SOS-1 were upregulated in the epithelium, fibroblasts and blood vessels of HGF. A similar pattern of expression was also found in healthy interdental papilla and in gingival wound healing. SOS-1 is involved with intracellular signaling cascades, which are stimulated by growth factors and cell adhesion receptors involved in wound healing (Hakkinen and Csiszar, 2006 in press in press; Nimnual and Bar-Sagi, 2002). A mutation in the gene locus that codes for SOS-1 has been associated with HGF1. Since SOS-1 antibody is made against a peptide that resides in an area mutated in HGF1, any patient with this genetic mutation would lack staining for SOS-1. Because SOS-1 expression was evident in all of our patients, we can conclude that they did not have HGF1. Activation of the SOS-1 pathway in these patients may occur via another mechanism than the SOS-1 mutation present in HGF1. Therefore, other mutations in HGF may affect the same pathway i.e. SOS-mediated signaling pathway, which may be important in the pathogenesis of HGF. Since SOS-1 expression in HGF and wound healing were similar i.e. upregulated, it is possible that HGF is a form of spontaneous overhealing of a wound without the physical presence of a wound.

Increased expression of $\alpha\text{v}\beta 6$ integrin seen in HGF may activate TGF- β (Sheppard, 2005), which in an autocrine and paracrine fashion increases its own expression, as well as that of CTGF (Leask and Abraham, 2004; Leivonen *et al.*, 2005). Healthy marginal gingiva was organized into the typical basket-weave pattern of thick bundles of collagen

fibers. Unlike normal gingiva, collagen fiber bundles were densely packed together and oriented either parallel to one another or in multiple directions in HGF. Compared to health, procollagen expression in disease was upregulated in the extracellular matrix, fibroblasts and blood vessels. This may be a consequence of increased growth factor expression, as together, CTGF and TGF- β regulate extracellular matrix deposition (Frazier *et al.*, 1996). CTGF may be important in the pathogenesis of HGF because it mediates the profibrotic effects of TGF- β and its expression is upregulated in certain fibrotic conditions (Blom *et al.*, 2002). Staining intensity for fibronectin-EDB and tenascin-C was also relatively stronger in the extracellular matrix in HGF than health. Furthermore, connective tissue and cell associated staining for fibronectin-EDB was found in HGF, but not in healthy marginal gingiva. TGF- β may be the underlying mechanism of increased fibronectin-EDB and tenascin-C expression (Linnala *et al.*, 1995; Pearson *et al.*, 1988). Among its many functions, TGF- β is vital in wound healing, tissue regeneration, stimulation of fibroblast proliferation, extracellular matrix production and epithelial cell migration and proliferation.

Fibromodulin, biglycan and lumican expression was increased in oral epithelium, while biglycan and lumican were also upregulated in the extracellular matrix in HGF. In addition, fibroblast associated staining for biglycan, fibromodulin and lumican, and blood vessel associated staining for fibromodulin and lumican were relatively stronger in HGF. Decorin, biglycan and fibromodulin may inhibit TGF- β activity (Hildebrand *et al.*, 1994) and in conjunction with lumican are also important in collagen fibrillogenesis (Ameys and Young, 2002; Hildebrand *et al.*, 1994; Hocking *et al.*, 1998). Biglycan and lumican are increased in response to tissue injury (Boykiw *et al.*, 1998; Saika *et al.*, 2000; Scott *et*

al., 1995; Scott *et al.*, 1996; Soo *et al.*, 2000), while decorin initially decreases during scar formation (Sayani *et al.*, 2000; Scott *et al.*, 1998; Zhu *et al.*, 2004) (Table 14). It is conceivable that the increased staining intensity for antibodies against small leucine-rich proteoglycans in HGF may be partly a compensatory mechanism to limit the fibrotic effects of TGF- β . However, there is no information to date about these molecules in HGF.

Marginal gingiva in HGF differs from that in health. Increased expression of $\alpha v \beta 6$ integrin, biglycan, lumican, TGF- β , CTGF, procollagen, fibronectin-EDB, tenascin-C (Boykiw *et al.*, 1998; Hakkinen *et al.*, 2000a; Larjava *et al.*, 2002; Soo *et al.*, 2000) and SOS-1 suggests that marginal gingiva in HGF not only resembles wound tissue, but also healthy interdental papilla. CK19 is not normally present in wounds, but is may be expressed in HGF to various degrees. Localized basal cells positive for CK19 have however been described in scar tissues of the skin (Fu *et al.*, 2005). We didn't differentiate whether HGF is a spontaneous initiation of the wound healing pathway or rather an expansion of the papillary tissue to the marginal area. However, we have demonstrated that the molecular phenotype of marginal gingiva in HGF is similar to that of healthy interdental papilla and that both are comparable to gingival wound tissue.

Molecules involved in wound healing are also upregulated in human interdental papilla. It is not clear whether this specific phenotype is inherent to cells of the papilla or whether cells are activated by the presence of mild localized inflammation present even in clinically healthy tissues. However, it is of note that processes involved in both drug-induced gingival overgrowth and HGF begin at the interdental papilla and subsequently

spread to the marginal gingiva (Hakkinen and Csiszar, 2006 in press in press). Hence, it is possible that in the presence of hereditary gene mutations, the specific activated phenotype of the cells in the papilla may predispose the tissue to gingival overgrowth.

Table 13. Summary of expression of molecules of interest in HGF marginal gingiva relative to healthy marginal gingiva.

Antibody	Relative Expression			
	Oral Epithelium	ECM	FBL	BV
CK19	↑	0	0	0
Integrin $\alpha\text{v}\beta 6$	↑	0	0	0
Decorin	0	-	0	0
Biglycan	↑	↑	↑	-
Fibromodulin	↑	-	↑	↑
Lumican	↑	↑	↑	↑
Procollagen	0	↑	↑	↑
FN-EDA	0	-	-	-
FN-EDB	0	↑	↑	↑
Tenascin-C	0	↑	0	-
TGF- $\beta_{1,2,3}$	↑	0	↑	↑
CTGF	↑	0	↑	↑
SOS-1	↑	0	↑	↑

↑: Upregulated; ↓: Down regulated; -: No change; 0: Not expressed; ECM: extracellular matrix; FBL: fibroblasts; BV: blood vessels.

6.3 Comparison of HGF marginal gingiva and palatal attached gingival wounds

TGF- $\beta_{1,2,3}$, CTGF and SOS-1 were immunolocalized in healthy, as well as wounded palatal attached gingiva. To our knowledge, there is no published data about expression of these molecules in wounded gingival tissues. Previous studies have shown that palatal and marginal gingiva are similar with respect to expression of $\alpha\beta6$ integrin and tenascin-C (Hakkinen *et al.*, 2000a), procollagen, decorin, biglycan, fibromodulin and lumican (Alimohamad *et al.*, 2005; Hakkinen *et al.*, 1993) and fibronectin-EDA and -EDB (Larjava *et al.*, 2002). In the present study, we also found that localization of TGF- $\beta_{1,2,3}$, CTGF and SOS-1 were comparable in healthy palatal attached gingiva and marginal gingiva. Therefore, the molecular composition is similar in marginal gingiva and palatal attached gingiva; however, both differ from the interdental papilla.

Expression of TGF- $\beta_{1,2,3}$, CTGF and SOS-1 was also compared in wounded palatal attached gingiva in health and marginal gingiva in HGF (Table 14). Such a comparison was important in our attempt to understand whether these molecules of interest were involved in initiating gingival overgrowth or if they were the result of the disease. In the first two weeks after wounding, SOS-1 and TGF- $\beta_{1,2,3}$ prevailed in the wound epithelium and connective tissue. However, at day 14 there was a shift from TGF- $\beta_{1,2,3}$ to CTGF expression, the latter of which dominated in late wound healing and continued to increase in wounded connective tissue (Figure 18). Therefore, TGF- $\beta_{1,2,3}$ expression was upregulated in early wound healing of palatal gingiva and decreased in late wound healing. A similar finding was noted in HGF, where TGF- $\beta_{1,2,3}$ expression was elevated. Expression of SOS-1 and TGF- $\beta_{1,2,3}$ had normalized in the epithelium at 60 days post-injury; however, wound connective tissue contained more blood vessels and fibroblasts

immunoreactive for these molecules than seen in unwounded gingiva. CTGF expression had not normalized at day 60 post-wounding (Figure 18). HGF is similar to early gingival wound healing with respect to TGF- $\beta_{1,2,3}$ expression. Considering that gingival overgrowth seen in HGF is fibrotic in nature, our results are consistent with prior studies which found that TGF- β was over-expressed in keloids and keloid derived fibroblasts (Lee *et al.*, 1999). The increased cell associated staining with CTGF and SOS-1 seen in late wound healing was also similar to HGF. CTGF, a cytokine believed to be a downstream mediator of TGF- β , increases proliferation and differentiation of fibroblasts and synthesis of matrix molecules (Bradham *et al.*, 1991). CTGF has not only been implicated in fibrosis (Brigstock, 1999), but it's level of expression was found to be positively correlated with the level of fibrosis (Igarashi *et al.*, 1996). Determining the expression pattern of SOS-1 in health and wound healing was thought to be important, because of the association between SOS-1 and HGF1.

Table 14. Major differences in HGF and palatal gingival wounds compared to healthy marginal gingiva.

	HGF	WOUND
CK19	↑ strongly induced in BC	Not expressed in wounds. CK19 positive cells are scant in basal layer of scar tissue in the skin (Fu <i>et al.</i> , 2005)
Integrin $\alpha v \beta 6$	↑ expression is induced in localized areas of BC	↑ expression in keratinocytes 7-14 days after human gingival wounding, when epithelial sheets fuse (Haapasalmi <i>et al.</i> , 1996; Hakkinen <i>et al.</i> , 2000a)
Decorin	No difference in staining intensity, but ↑ association with collagen fibers in CT	Initially ↓ during scar formation, but is similar to health in later stages of scarring (Sayani <i>et al.</i> , 2000; Scott <i>et al.</i> , 1998; Zhu <i>et al.</i> , 2004). It may be upregulated during adult rat skin wound healing compared to fetal scarless wound healing (Soo <i>et al.</i> , 2000).
Biglycan	↑ staining intensity in BC, immediate suprabasal layer and CT. There are more FBL with immunoreactivity for biglycan	↑ in mature scars (Scott <i>et al.</i> , 1995; Scott <i>et al.</i> , 1996) and adult wound healing (Soo <i>et al.</i> , 2000). ↑ in response to injury of rabbit ligaments (Boykiw <i>et al.</i> , 1998).
Fibromodulin	↑ in BC of E. There are more FBL and BV with immunoreactivity for fibromodulin	No change in response to tissue injury of the rabbit ligament (Boykiw <i>et al.</i> , 1998) or in pig skin wound healing (Wang <i>et al.</i> , 2000)
Lumican	↑ in BC and suprabasal cells & CT matrix. There are more FBL & BV with immunoreactivity for lumican	Injured mouse corneal epithelium transiently expresses lumican during the early phase of wound healing (Saika <i>et al.</i> , 2000). ↑ in response to tissue injury of rabbit ligaments (Boykiw <i>et al.</i> , 1998).
Procollagen	↑ in CT matrix and more BV & FBL with immunoreactivity for procollagen	Changes in matrix composition during inflammation and wound healing are regulated not only by altered phenotypes of the cells that produce the matrix, but also by the ↑ response of these cells (e.g. procollagen) to TGF β_1 (Hakkinen <i>et al.</i> , 1996).

E: epithelium; CT: connective tissue; HGF: hereditary gingival fibromatosis; SS: stratum spinosum; SG: stratum granulosum; BC: basal cells; BMZ: basement membrane zone; FBL: fibroblast; BV: blood vessels

Table 14 continued. Major differences in HGF and palatal gingival wounds compared to healthy marginal gingiva.

	HGF	WOUND
FN-EDB	↑ in BMZ & CT matrix. There are more BV and FBL with immunoreactivity for FN-EDB	↑ at 4-14 days post wounding in mice (Singh <i>et al.</i> , 2004) and at the base and edges of skin wounds in rats (Ffrench-Constant <i>et al.</i> , 1989). Upregulated in granulation tissues of human oral mucosal wounds at 7-28 days after wounding (Larjava <i>et al.</i> , 2002).
Tenascin-C	↑ in CT matrix in association with collagen fibers	↑ expression under migrating epithelial front and granulation tissue during matrix deposition in oral mucosal wound repair (Hakkinen <i>et al.</i> , 2000a)
TGF-$\beta_{1,2,3}$	↑ in E and more FBL & BV with immunoreactivity for TGF- $\beta_{1,2,3}$	↑ compared to health. TGF- $\beta_{1,2}$ are over-expressed in keloids and keloid derived fibroblasts, while TGF- β_3 was comparable to health (Lee <i>et al.</i> , 1999). Whether or not TGF- β_3 is scar inducing is study dependant. Peak TGF- β levels found during fibroblast proliferation and collagen synthesis phase of healing (Cromack <i>et al.</i> , 1987). TGF- $\beta_{1,2,3}$ is increased in early wound healing, returning to baseline levels thereafter (Hakkinen unpublished data).
CTGF	↑ in E and more FBL & BV with immunoreactivity for CTGF	↑ compared to health. Level of expression correlated with degree of fibrosis in human skin biopsies (Igarashi <i>et al.</i> , 1996). CTGF steadily increases and peaks during late wound healing and remains elevated even at 60 days post-wounding (Hakkinen unpublished data).
SOS-1	↑ in E and more FBL & BV with immunoreactivity for SOS-1	No published data available to date. SOS-1 is increased in early wound healing and remains elevated even at 60 days post-wounding (Hakkinen unpublished data).

E: epithelium; CT: connective tissue; HGF: hereditary gingival fibromatosis; SS: stratum spinosum; SG: stratum granulosum; BC: basal cells; BMZ: basement membrane zone; FBL: fibroblast; BV: blood vessels

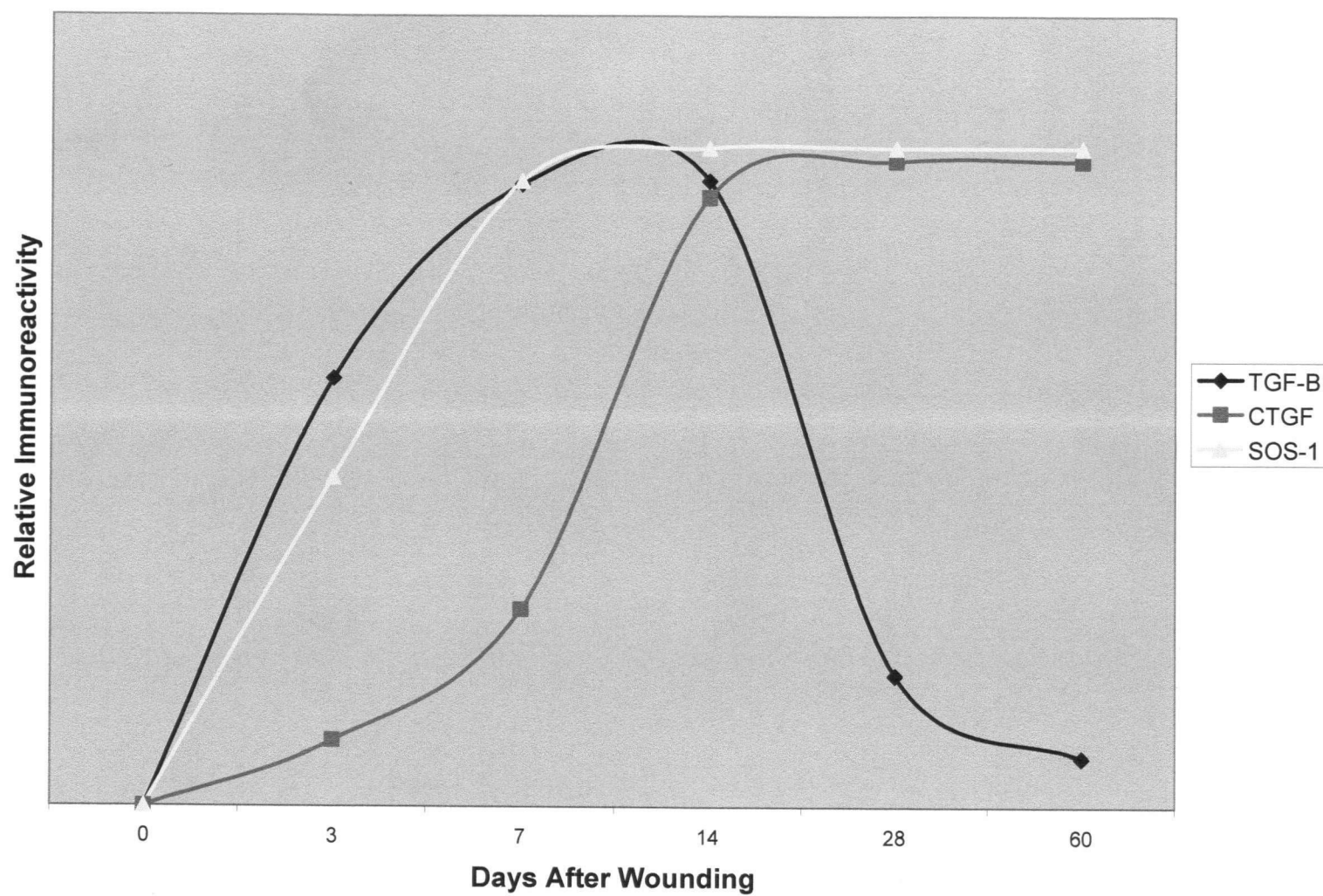


Figure 18. Summary of wound healing events in the palatal gingiva.

7 Conclusions and Future Directions

7.1 Conclusions

- The molecular composition of healthy marginal gingiva is distinct from healthy interdental papilla.
- Molecules normally induced in gingival wound healing ($\alpha\text{v}\beta\text{6}$ integrin, fibronectin-EDA, fibronectin-EDB, tenascin-C, procollagen, TGF- β , CTGF and SOS-1) are also upregulated in healthy interdental papilla, suggesting that cells in the papilla are either in an activated state or inherently display the phenotypic markers associated with wound healing.
- The molecular composition of marginal gingiva in HGF differs from that in health. Because the phenotypic markers associated with marginal gingiva in HGF resemble gingival wounds, it is possible that gingival overgrowth in HGF is a result of a wound healing response without the presence of a wound.
- The fact that HGF marginal gingiva also shows similarities to healthy interdental papilla suggests that HGF marginal gingiva may be an expansion of the interdental papilla.

7.2 Future Directions

Papilla regeneration as a result of periodontal surgery is frequently a desire, more than a reality, as its regeneration is highly unpredictable. Determining the molecular differences between healthy marginal gingiva and interdental papilla is clinically invaluable to understand the factors that regulate papilla regeneration. Although anatomic factors are an important cause of the limited regeneration ability of the papilla, specific molecules

may also play a vital role. A better understanding of the molecular phenotype of the papilla would enable researchers to develop molecular therapies that selectively promote the growth of appropriate cells.

It is possible that HGF is a spontaneous initiation of the wound healing pathway or merely an expansion of the papillary tissue to the marginal area. The focus of future studies should be on understanding the specific gene mutations involved in the various forms of HGF and correlating these mutations to clinical and histological changes. Deciphering the functions of these genes would provide new tools for diagnosis, prevention and treatment of HGF, drug-induced gingival overgrowth and other fibrotic diseases.

BIBLIOGRAPHY

Aimes RT, Quigley JP (1995). Matrix metalloproteinase-2 is an interstitial collagenase. Inhibitor-free enzyme catalyzes the cleavage of collagen fibrils and soluble native type I collagen generating the specific 3/4- and 1/4-length fragments. *J Biol Chem* 270(11):5872-6.

Alimohamad H, Habijanac T, Larjava H, Hakkinen L (2005). Colocalization of the collagen-binding proteoglycans decorin, biglycan, fibromodulin and lumican with different cells in human gingiva. *J Periodontol Res* 40(1):73-86.

Almeida JP, Coletta RD, Silva SD, Agostini M, Vargas PA, Bozzo L, Graner E (2005). Proliferation of fibroblasts cultured from normal gingiva and hereditary gingival fibromatosis is dependent on fatty acid synthase activity. *J Periodontol* 76(2):272-8.

Ameye L, Young MF (2002). Mice deficient in small leucine-rich proteoglycans: novel in vivo models for osteoporosis, osteoarthritis, Ehlers-Danlos syndrome, muscular dystrophy, and corneal diseases. *Glycobiology* 12(9):107R-16R.

Anderson J, Cunliffe WJ, Roberts DF, Close H (1969). Hereditary gingival fibromatosis. *Br Med J* 3(664):218-9.

Antman EM, Stone PH, Muller JE, Braunwald E (1980). Calcium channel blocking agents in the treatment of cardiovascular disorders. Part I: Basic and clinical electrophysiologic effects. *Ann Intern Med* 93(6):875-85.

Araiche M, Brode H (1959). A case of fibromatosis gingivae. *Oral Surg Oral Med Oral Pathol* 12(1):1307-10.

Araujo CS, Graner E, Almeida OP, Sauk JJ, Coletta RD (2003). Histomorphometric characteristics and expression of epidermal growth factor and its receptor by epithelial cells of normal gingiva and hereditary gingival fibromatosis. *J Periodontol Res* 38(3):237-41.

Baptista IP (2002). Hereditary gingival fibromatosis: a case report. *J Clin Periodontol* 29(9):871-4.

Bhavsar JP, Damle SG, Bhatt AP (1991). Idiopathic gingival fibromatosis associated with mild hypertrichosis. *J Indian Soc Pedod Prev Dent* 9(1):31-3.

Bianco P, Fisher LW, Young MF, Termine JD, Robey PG (1990). Expression and localization of the two small proteoglycans biglycan and decorin in developing human skeletal and non-skeletal tissues. *J Histochem Cytochem* 38(11):1549-63.

Birkedal-Hansen H (1988). From tadpole collagenase to a family of matrix metalloproteinases. *J Oral Pathol* 17(9-10):445-51.

Bittencourt LP, Campos V, Moliterno LF, Ribeiro DP, Sampaio RK (2000). Hereditary gingival fibromatosis: review of the literature and a case report. *Quintessence Int* 31(6):415-8.

Blom IE, Goldschmeding R, Leask A (2002). Gene regulation of connective tissue growth factor: new targets for antifibrotic therapy? *Matrix Biol* 21(6):473-82.

Bokenkamp A, Bohnhorst B, Beier C, Albers N, Offner G, Brodehl J (1994). Nifedipine aggravates cyclosporine A-induced gingival hyperplasia. *Pediatr Nephrol* 8(2):181-5.

Boykiw R, Sciore P, Reno C, Marchuk L, Frank CB, Hart DA (1998). Altered levels of extracellular matrix molecule mRNA in healing rabbit ligaments. *Matrix Biol* 17(5):371-8.

Bozzo L, de Almedia OP, Scully C, Aldred MJ (1994). Hereditary gingival fibromatosis. Report of an extensive four-generation pedigree. *Oral Surg Oral Med Oral Pathol* 78(4):452-4.

Bradham DM, Igarashi A, Potter RL, Grotendorst GR (1991). Connective tissue growth factor: a cysteine-rich mitogen secreted by human vascular endothelial cells is related to the SRC-induced immediate early gene product CEF-10. *J Cell Biol* 114(6):1285-94.

Brigstock DR (1999). The connective tissue growth factor/cysteine-rich 61/nephroblastoma overexpressed (CCN) family. *Endocr Rev* 20(2):189-206.

Brunet L, Miranda J, Roset P, Berini L, Farre M, Mendieta C (2001). Prevalence and risk of gingival enlargement in patients treated with anticonvulsant drugs. *Eur J Clin Invest* 31(9):781-8.

Casavecchia P, Uzel MI, Kantarci A, Hasturk H, Dibart S, Hart TC, Trackman PC, Van Dyke TE (2004). Hereditary gingival fibromatosis associated with generalized aggressive periodontitis: a case report. *J Periodontol* 75(5):770-8.

Chardin P, Camonis JH, Gale NW, van Aelst L, Schlessinger J, Wigler MH, Bar-Sagi D (1993). Human Sos1: a guanine nucleotide exchange factor for Ras that binds to GRB2. *Science* 260(5112):1338-43.

Choquet V, Hermans M, Adriaenssens P, Daelemans P, Tarnow DP, Malevez C (2001). Clinical and radiographic evaluation of the papilla level adjacent to single-tooth dental implants. A retrospective study in the maxillary anterior region. *J Periodontol* 72(10):1364-71.

Cochran DL, Wozney JM (1999). Biological mediators for periodontal regeneration. *Periodontol 2000* 19(1):40-58.

Coletta RD, Almeida OP, Graner E, Page RC, Bozzo L (1998). Differential proliferation of fibroblasts cultured from hereditary gingival fibromatosis and normal gingiva. *J Periodontal Res* 33(8):469-75.

Coletta RD, Almeida OP, Reynolds MA, Sauk JJ (1999). Alteration in expression of MMP-1 and MMP-2 but not TIMP-1 and TIMP-2 in hereditary gingival fibromatosis is mediated by TGF-beta 1 autocrine stimulation. *J Periodontal Res* 34(8):457-63.

Corbalan-Garcia S, Yang SS, Degenhardt KR, Bar-Sagi D (1996). Identification of the mitogen-activated protein kinase phosphorylation sites on human Sos1 that regulate interaction with Grb2. *Mol Cell Biol* 16(10):5674-82.

Cotrim P, de Andrade CR, Martelli-Junior H, Graner E, Sauk JJ, Coletta RD (2002). Expression of matrix metalloproteinases in cyclosporin-treated gingival fibroblasts is regulated by transforming growth factor (TGF)-beta1 autocrine stimulation. *J Periodontol* 73(11):1313-22.

Cromack DT, Sporn MB, Roberts AB, Merino MJ, Dart LL, Norton JA (1987). Transforming growth factor beta levels in rat wound chambers. *J Surg Res* 42(6):622-8.

Dale BA, Salonen J, Jones AH (1990). New approaches and concepts in the study of differentiation of oral epithelia. *Crit Rev Oral Biol Med* 1(3):167-90.

Daly AK, Cholerton S, Gregory W, Idle JR (1993). Metabolic polymorphisms. *Pharmacol Ther* 57(2-3):129-60.

de Andrade CR, Cotrin P, Graner E, Almeida OP, Sauk JJ, Coletta RD (2001). Transforming growth factor-beta1 autocrine stimulation regulates fibroblast proliferation in hereditary gingival fibromatosis. *J Periodontol* 72(12):1726-33.

Deliliers GL, Santoro F, Polli N, Bruno E, Fumagalli L, Risciotti E (1986). Light and electron microscopic study of cyclosporin A-induced gingival hyperplasia. *J Periodontol* 57(12):771-5.

Dill RE, Miller EK, Weil T, Lesley S, Farmer GR, Iacopino AM (1993). Phenytoin increases gene expression for platelet-derived growth factor B chain in macrophages and monocytes. *J Periodontol* 64(3):169-73.

Doufexi A, Mina M, Ioannidou E (2005). Gingival overgrowth in children: epidemiology, pathogenesis, and complications. A literature review. *J Periodontol* 76(1):3-10.

Duncan MR, Berman B (1987). Persistence of a reduced-collagen-producing phenotype in cultured scleroderma fibroblasts after short-term exposure to interferons. *J Clin Invest* 79(5):1318-24.

Duymelinck C, Deng JT, Dauwe SE, De Broe ME, Verpooten GA (1998). Inhibition of the matrix metalloproteinase system in a rat model of chronic cyclosporine nephropathy. *Kidney Int* 54(3):804-18.

Edwards DR, Murphy G, Reynolds JJ, Whitham SE, Docherty AJ, Angel P, Heath JK (1987). Transforming growth factor beta modulates the expression of collagenase and metalloproteinase inhibitor. *Embo J* 6(7):1899-904.

Ellis JS, Seymour RA, Steele JG, Robertson P, Butler TJ, Thomason JM (1999). Prevalence of gingival overgrowth induced by calcium channel blockers: a community-based study. *J Periodontol* 70(1):63-7.

Farrer-Brown G, Lucas RB, Winstock D (1972). Familial gingival fibromatosis: an unusual pathology. *J Oral Pathol* 1(2):76-83.

Ffrench-Constant C, Van de Water L, Dvorak HF, Hynes RO (1989). Reappearance of an embryonic pattern of fibronectin splicing during wound healing in the adult rat. *J Cell Biol* 109(2):903-14.

Fisher LW, Termine JD, Young MF (1989). Deduced protein sequence of bone small proteoglycan I (biglycan) shows homology with proteoglycan II (decorin) and several nonconnective tissue proteins in a variety of species. *J Biol Chem* 264(8):4571-6.

Flaitz CM, Coleman GC (1995). Differential diagnosis of oral enlargements in children. *Pediatr Dent* 17(4):294-300.

Fletcher J (1966). Gingival abnormalities of genetic origin: preliminary communication with special reference to hereditary gingival fibromatosis. *Journal of Dental Research*. 45(3):597-612.

Frazier K, Williams S, Kothapalli D, Klapper H, Grotendorst GR (1996). Stimulation of fibroblast cell growth, matrix production, and granulation tissue formation by connective tissue growth factor. *J Invest Dermatol* 107(3):404-11.

Freytag SO (1988). Enforced expression of the c-myc oncogene inhibits cell differentiation by precluding entry into a distinct predifferentiation state in G0/G1. *Mol Cell Biol* 8(4):1614-24.

Fryns JP (1996). Gingival fibromatosis and partial duplication of the short arm of chromosome 2 (dup(2)(p13-->p21)). *Ann Genet* 39(1):54-5.

Fu XB, Sun TZ, Li XK, Sheng ZY (2005). Morphological and distribution characteristics of sweat glands in hypertrophic scar and their possible effects on sweat gland regeneration. *Chin Med J (Engl)* 118(3):186-91.

Fujiwara M, Muragaki Y, Ooshima A (2005). Keloid-derived fibroblasts show increased secretion of factors involved in collagen turnover and depend on matrix metalloproteinase for migration. *Br J Dermatol* 153(2):295-300.

Gardner HP, Rajan JV, Ha SI, Copeland NG, Gilbert DJ, Jenkins NA, Marquis ST, Chodosh LA (2000). Cloning, characterization, and chromosomal localization of Pnck, a Ca(2+)/calmodulin-dependent protein kinase. *Genomics* 63(2):279-88.

Goldblatt J, Singer SL (1992). Autosomal recessive gingival fibromatosis with distinctive facies. *Clin Genet* 42(6):306-8.

Gorlin R, Cohen MM, Levis LS (1990). Syndromes of the head and neck. 3 ed. New York: Oxford University Press.

Govinden R, Bhoola KD (2003). Genealogy, expression, and cellular function of transforming growth factor-beta. *Pharmacol Ther* 98(2):257-65.

Grover J, Chen XN, Korenberg JR, Roughley PJ (1995). The human lumican gene. Organization, chromosomal location, and expression in articular cartilage. *J Biol Chem* 270(37):21942-9.

Gunhan O, Gardner DG, Bostanci H, Gunhan M (1995). Familial gingival fibromatosis with unusual histologic findings. *J Periodontol* 66(11):1008-11.

Haapasalmi K, Makela M, Oksala O, Heino J, Yamada KM, Uitto VJ, Larjava H (1995). Expression of epithelial adhesion proteins and integrins in chronic inflammation. *Am J Pathol* 147(1):193-206.

Haapasalmi K, Zhang K, Tonnesen M, Olerud J, Sheppard D, Salo T, Kramer R, Clark RA, Uitto VJ, Larjava H (1996). Keratinocytes in human wounds express alpha v beta 6 integrin. *J Invest Dermatol* 106(1):42-8.

Hakkinen L, Larjava H (1992). Characterization of fibroblast clones from periodontal granulation tissue in vitro. *J Dent Res* 71(12):1901-7.

Hakkinen L, Oksala O, Salo T, Rahemtulla F, Larjava H (1993). Immunohistochemical localization of proteoglycans in human periodontium. *J Histochem Cytochem* 41(11):1689-99.

Hakkinen L, Westermarck J, Kahari VM, Larjava H (1996). Human granulation-tissue fibroblasts show enhanced proteoglycan gene expression and altered response to TGF-beta 1. *J Dent Res* 75(10):1767-78.

Hakkinen L, Hildebrand HC, Berndt A, Kosmehl H, Larjava H (2000a). Immunolocalization of tenascin-C, alpha9 integrin subunit, and alphavbeta6 integrin during wound healing in human oral mucosa. *J Histochem Cytochem* 48(7):985-98.

Hakkinen L, Strassburger S, Kahari VM, Scott PG, Eichstetter I, Lozzo RV, Larjava H (2000b). A role for decorin in the structural organization of periodontal ligament. *Lab Invest* 80(12):1869-80.

Hakkinen L, Uitto VJ, Larjava H (2000c). Cell biology of gingival wound healing. *Periodontol 2000* 24(127-52).

Hakkinen L, Koivisto L, Gardner H, Saarialho-Kere U, Carroll JM, Lakso M, Rauvala H, Laato M, Heino J, Larjava H (2004). Increased expression of beta6-integrin in skin leads to spontaneous development of chronic wounds. *Am J Pathol* 164(1):229-42.

Hakkinen L, Csiszar A (2006 in press). Hereditary gingival fibromatosis: Characteristics and novel putative pathogenic mechanisms. *Journal of Dental Research*.

Hart TC, Pallos D, Bowden DW, Bolyard J, Pettenati MJ, Cortelli JR (1998). Genetic linkage of hereditary gingival fibromatosis to chromosome 2p21. *Am J Hum Genet* 62(4):876-83.

Hart TC, Pallos D, Bozzo L, Almeida OP, Marazita ML, O'Connell JR, Cortelli JR (2000). Evidence of genetic heterogeneity for hereditary gingival fibromatosis. *J Dent Res* 79(10):1758-64.

Hart TC, Zhang Y, Gorry MC, Hart PS, Cooper M, Marazita ML, Marks JM, Cortelli JR, Pallos D (2002). A mutation in the SOS1 gene causes hereditary gingival fibromatosis type 1. *Am J Hum Genet* 70(4):943-54.

Hassell TM, Page RC, Narayanan AS, Cooper CG (1976). Diphenylhydantoin (dilantin) gingival hyperplasia: drug-induced abnormality of connective tissue. *Proc Natl Acad Sci USA* 73(8):2909-12.

Hassell TM, Hefti AF (1991). Drug-induced gingival overgrowth: old problem, new problem. *Crit Rev Oral Biol Med* 2(1):103-37.

Hassell TM (1993). Tissues and cells of the periodontium. *Periodontol* 2000 3(9-38).

Hildebrand A, Romaris M, Rasmussen LM, Heinegard D, Twardzik DR, Border WA, Ruoslahti E (1994). Interaction of the small interstitial proteoglycans biglycan, decorin and fibromodulin with transforming growth factor beta. *Biochem J* 302 (Pt 2):527-34.

Hocking AM, Shinomura T, McQuillan DJ (1998). Leucine-rich repeat glycoproteins of the extracellular matrix. *Matrix Biol* 17(1):1-19.

Horning GM, Fisher JG, Barker BF, Killoy WJ, Lowe JW (1985). Gingival fibromatosis with hypertrichosis. A case report. *J Periodontol* 56(6):344-7.

Huang X, Wu J, Zhu W, Pytela R, Sheppard D (1998). Expression of the human integrin beta6 subunit in alveolar type II cells and bronchiolar epithelial cells reverses lung inflammation in beta6 knockout mice. *Am J Respir Cell Mol Biol* 19(4):636-42.

Hyland PL, Traynor PS, Myrillas TT, Marley JJ, Linden GJ, Winter P, Leadbetter N, Cawston TE, Irwin CR (2003). The effects of cyclosporin on the collagenolytic activity of gingival fibroblasts. *J Periodontol* 74(4):437-45.

Igarashi A, Okochi H, Bradham DM, Grotendorst GR (1993). Regulation of connective tissue growth factor gene expression in human skin fibroblasts and during wound repair. *Mol Biol Cell* 4(6):637-45.

Igarashi A, Nashiro K, Kikuchi K, Sato S, Ihn H, Fujimoto M, Grotendorst GR, Takehara K (1996). Connective tissue growth factor gene expression in tissue sections from localized scleroderma, keloid, and other fibrotic skin disorders. *J Invest Dermatol* 106(4):729-33.

Innocenti M, Tenca P, Frittoli E, Faretta M, Tocchetti A, Di Fiore PP, Scita G (2002). Mechanisms through which Sos-1 coordinates the activation of Ras and Rac. *J Cell Biol* 156(1):125-36.

Jain N, Brickenden A, Ball EH, Sanwal BD (1994). Inhibition of procollagen I degradation by colligin: a collagen-binding serpin. *Arch Biochem Biophys* 314(1):23-30.

James P, Prasad SV (1971). Gingival fibromatosis: report of a case. *J Oral Surg* 29(1):55-59.

Johnson LL, Dyer R, Hupe DJ (1998). Matrix metalloproteinases. *Curr Opin Chem Biol* 2(4):466-71.

Kataoka M, Kido J, Shinohara Y, Nagata T (2005). Drug-induced gingival overgrowth--a review. *Biol Pharm Bull* 28(10):1817-21.

Kato T, Okahashi N, Kawai S, Kato T, Inaba H, Morisaki I, Amano A (2005). Impaired degradation of matrix collagen in human gingival fibroblasts by the antiepileptic drug phenytoin. *J Periodontol* 76(6):941-50.

Kelekis-Cholakakis A, Wiltshire WA, Birek C (2002). Treatment and long-term follow-up of a patient with hereditary gingival fibromatosis: a case report. *J Can Dent Assoc* 68(5):290-4.

Kharbanda O, Sidhu SS, Panda SK, Deshmuck R (1993). Gingival fibromatosis: study with three generations with consanguinity. *Quintessence International*. 24(3):161-164.

Kim Y, Ratzu V, Choi SG, Lalazar A, Theiss G, Dang Q, Kim SJ, Friedman SL (1998). Transcriptional activation of transforming growth factor beta1 and its receptors by the Kruppel-like factor Zf9/core promoter-binding protein and Sp1. Potential mechanisms for autocrine fibrogenesis in response to injury. *J Biol Chem* 273(50):33750-8.

Krontiras H, Roye GD, Beenken SE, Myers RB, Mayo MS, Peters GE, Grizzle WE (1999). Fatty acid synthase expression is increased in neoplastic lesions of the oral tongue. *Head Neck* 21(4):325-9.

Kuru L, Yilmaz S, Kuru B, Kose KN, Noyan U (2004). Expression of growth factors in the gingival crevice fluid of patients with phenytoin-induced gingival enlargement. *Arch Oral Biol* 49(11):945-50.

Larjava H, Koivisto, L, Hakkinen, L (2002). Keratinocyte interactions with fibronectin during wound healing. In: Cell Invasion (Medical Intelligence Unit). J Heino, Kahari, VM editor. Turku, Finland: Landes Bioscience, pp. 42-64.

Leask A, Abraham DJ (2004). TGF-beta signaling and the fibrotic response. *FASEB J* 18(7):816-27.

Lee TY, Chin GS, Kim WJ, Chau D, Gittes GK, Longaker MT (1999). Expression of transforming growth factor beta 1, 2, and 3 proteins in keloids. *Ann Plast Surg* 43(2):179-84.

Leivonen SK, Hakkinen L, Liu D, Kahari VM (2005). Smad3 and extracellular signal-regulated kinase 1/2 coordinately mediate transforming growth factor-beta-induced expression of connective tissue growth factor in human fibroblasts. *J Invest Dermatol* 124(6):1162-9.

Lindhe J, Karring T, Lang NP (2003). Clinical Periodontology and Implant Dentistry. 4 ed. Iowa: Blackwell Publishing.

Linnala A, Kinnula V, Laitinen LA, Lehto VP, Virtanen I (1995). Transforming growth factor-beta regulates the expression of fibronectin and tenascin in BEAS 2B human bronchial epithelial cells. *Am J Respir Cell Mol Biol* 13(5):578-85.

Lynch M, Brightman VJ, Greenberg MS (1994). Burket's Oral Medicine. 9 ed. Philadelphia: J.B. Lippincott.

Ma C, Tarnuzzer RW, Chegini N (1999). Expression of matrix metalloproteinases and tissue inhibitor of matrix metalloproteinases in mesothelial cells and their regulation by transforming growth factor-beta1. *Wound Repair Regen* 7(6):477-85.

Macias-Flores MA, Garcia-Cruz D, Rivera H, Escobar-Lujan M, Melendrez-Vega A, Rivas-Campos D, Rodriguez-Collazo F, Moreno-Arellano I, Cantu JM (1984). A new form of hypertrichosis inherited as an X-linked dominant trait. *Hum Genet* 66(1):66-70.

Majola MP, McFadyen ML, Connolly C, Nair YP, Govender M, Laher MH (2000). Factors influencing phenytoin-induced gingival enlargement. *J Clin Periodontol* 27(7):506-12.

Martelli-Junior H, Cotrim P, Graner E, Sauk JJ, Coletta RD (2003). Effect of transforming growth factor-beta1, interleukin-6, and interferon-gamma on the expression of type I collagen, heat shock protein 47, matrix metalloproteinase (MMP)-1 and MMP-2 by fibroblasts from normal gingiva and hereditary gingival fibromatosis. *J Periodontol* 74(3):296-306.

Massague J (1992). Receptors for the TGF-beta family. *Cell* 69(7):1067-70.

- Matheson S, Larjava H, Hakkinen L (2005). Distinctive localization and function for lumican, fibromodulin and decorin to regulate collagen fibril organization in periodontal tissues. *J Periodontal Res* 40(4):312-24.
- McCollam L, Bonfini L, Karlovich CA, Conway BR, Kozma LM, Banerjee U, Czech MP (1995). Functional roles for the pleckstrin and Dbl homology regions in the Ras exchange factor Son-of-sevenless. *J Biol Chem* 270(27):15954-7.
- McCulloch CA, Knowles GC (1993). Deficiencies in collagen phagocytosis by human fibroblasts in vitro: a mechanism for fibrosis? *J Cell Physiol* 155(3):461-71.
- Miller DA, Pelton RW, Derynck R, Moses HL (1990). Transforming growth factor-beta. A family of growth regulatory peptides. *Ann N Y Acad Sci* 593(208-17.
- Miller M, Truhe T (1993). Lasers in dentistry: an overview. *J Am Dent Assoc* 124(2):32-5.
- Miranda J, Brunet L, Roset P, Berini L, Farre M, Mendieta C (2001). Prevalence and risk of gingival enlargement in patients treated with nifedipine. *J Periodontol* 72(5):605-11.
- Morey MA, Higgins RR (1990). Ectro-amelia syndrome associated with an interstitial deletion of 7q. *Am J Med Genet* 35(1):95-9.
- Nares S, Ng MC, Dill RE, Park B, Cutler CW, Iacopino AM (1996). Cyclosporine A upregulates platelet-derived growth factor B chain in hyperplastic human gingiva. *J Periodontol* 67(3):271-8.
- Nery EB, Edson RG, Lee KK, Pruthi VK, Watson J (1995). Prevalence of nifedipine-induced gingival hyperplasia. *J Periodontol* 66(7):572-8.
- Nimnual A, Bar-Sagi D (2002). The two hats of SOS. *Sci STKE* 2002(145):PE36.
- Nimnual AS, Yatsula BA, Bar-Sagi D (1998). Coupling of Ras and Rac guanosine triphosphatases through the Ras exchanger Sos. *Science* 279(5350):560-3.
- Nishikawa S, Nagata T, Morisaki I, Oka T, Ishida H (1996). Pathogenesis of drug-induced gingival overgrowth. A review of studies in the rat model. *J Periodontol* 67(5):463-71.
- O'Leary R, Wood EJ, Guillou PJ (2002). Pathological scarring: strategic interventions. *Eur J Surg* 168(10):523-34.
- Ouhayoun JP, Goffaux JC, Sawaf MH, Shabana AH, Collin C, Forest N (1990). Changes in cytokeratin expression in gingiva during inflammation. *J Periodontal Res* 25(5):283-92.

Overall CM, Wrana JL, Sodek J (1989). Independent regulation of collagenase, 72-kDa progelatinase, and metalloendoproteinase inhibitor expression in human fibroblasts by transforming growth factor-beta. *J Biol Chem* 264(3):1860-9.

Overall CM, Wrana JL, Sodek J (1991). Transcriptional and post-transcriptional regulation of 72-kDa gelatinase/type IV collagenase by transforming growth factor-beta 1 in human fibroblasts. Comparisons with collagenase and tissue inhibitor of matrix metalloproteinase gene expression. *J Biol Chem* 266(21):14064-71.

Pankewycz OG, Miao L, Isaacs R, Guan J, Pruett T, Haussmann G, Sturgill BC (1996). Increased renal tubular expression of transforming growth factor beta in human allografts correlates with cyclosporine toxicity. *Kidney Int* 50(5):1634-40.

Pearson CA, Pearson D, Shibahara S, Hofsteenge J, Chiquet-Ehrismann R (1988). Tenascin: cDNA cloning and induction by TGF-beta. *Embo J* 7(10):2977-82.

Plaas AH, Wong-Palms S (1993). Biosynthetic mechanisms for the addition of polyactosamine to chondrocyte fibromodulin. *J Biol Chem* 268(35):26634-44.

Pritlove-Carson S, Charlesworth S, Morgan PR, Palmer RM (1997). Cytokeratin phenotypes at the dento-gingival junction in relative health and inflammation, in smokers and nonsmokers. *Oral Dis* 3(1):19-24.

Qian X, Esteban L, Vass WC, Upadhyaya C, Papageorge AG, Yienger K, Ward JM, Lowy DR, Santos E (2000). The Sos1 and Sos2 Ras-specific exchange factors: differences in placental expression and signaling properties. *Embo J* 19(4):642-54.

Raeste AM, Collan Y, Kilpinen E (1978). Hereditary fibrous hyperplasia of the gingiva with varying penetrance and expressivity. *Scand J Dent Res* 86(5):357-65.

Ramer M, Marrone J, Stahl B, Burakoff R (1996). Hereditary gingival fibromatosis: identification, treatment, control. *J Am Dent Assoc* 127(4):493-5.

Ramon Y, Berman W, Bubis JJ (1967). Gingival fibromatosis combined with cherubism. *Oral Surg Oral Med Oral Pathol* 24(4):435-48.

Redman RS, Ward CC, Patterson RH (1985). Focus of epithelial dysplasia arising in hereditary gingival fibromatosis. *J Periodontol* 56(3):158-62.

Research Letter (2002). Hereditary gingival fibromatosis with hypertrichosis is unlinked to the HGF1 and HGF2 loci. *Americal Journal of Medical Genetics* 116(A):312-314.

Rivera H, Ramirez-Duenas ML, Figuera LE, Gonzalez-Montes RM, Vasquez AI (1992). Opposite imbalances of distal 14q in two unrelated patients. *Ann Genet* 35(2):97-100.

Roberts AB, Froli C, Anzano M, Assoian RK, Sporn MB (1984). Purification of type B transforming growth factors from non-neoplastic tissues. Methods for preparation of media. Supplements and substrata from serum-free animal culture. *Cell Culture Methods for Molecular Cell Biology*. In: SD Barnes DW, Stao GH editor. New York: Alan R. Liss Inc., pp. 181-194.

Saggi SJ, Andoh TF, Safirstein R, Bennett WM (2004). Cyclosporin induces renal proto-oncogene RNA message and increased transforming growth factor-beta prior to renal fibrosis: Modification by calcium channel blockade in the salt replete rat. *Nephrology (Carlton)* 9(2):58-64.

Saika S, Shiraishi A, Liu CY, Funderburgh JL, Kao CW, Converse RL, Kao WW (2000). Role of lumican in the corneal epithelium during wound healing. *J Biol Chem* 275(4):2607-12.

Saito K, Mori S, Iwakura M, Sakamoto S (1996). Immunohistochemical localization of transforming growth factor beta, basic fibroblast growth factor and heparan sulphate glycosaminoglycan in gingival hyperplasia induced by nifedipine and phenytoin. *J Periodontal Res* 31(8):545-55.

Saito K, Mori S, Tanda N, Sakamoto S (2000). Immunolocalization of c-Myc and bcl-2 proto-oncogene products in gingival hyperplasia induced by nifedipine and phenytoin. *J Periodontol* 71(1):44-9.

Satoh M, Hirayoshi K, Yokota S, Hosokawa N, Nagata K (1996). Intracellular interaction of collagen-specific stress protein HSP47 with newly synthesized procollagen. *J Cell Biol* 133(2):469-83.

Sayani K, Dodd CM, Nedelec B, Shen YJ, Ghahary A, Tredget EE, Scott PG (2000). Delayed appearance of decorin in healing burn scars. *Histopathology* 36(3):262-72.

Schaefer L, Grone HJ, Raslik I, Robenek H, Ugorcakova J, Budny S, Schaefer RM, Kresse H (2000). Small proteoglycans of normal adult human kidney: distinct expression patterns of decorin, biglycan, fibromodulin, and lumican. *Kidney Int* 58(4):1557-68.

Scita G, Nordstrom J, Carbone R, Tenca P, Giardina G, Gutkind S, Bjarnegard M, Betsholtz C, Di Fiore PP (1999). EPS8 and E3B1 transduce signals from Ras to Rac. *Nature* 401(6750):290-3.

Scott PG, Dodd CM, Tredget EE, Ghahary A, Rahemtulla F (1995). Immunohistochemical localization of the proteoglycans decorin, biglycan and versican and transforming growth factor-beta in human post-burn hypertrophic and mature scars. *Histopathology* 26(5):423-31.

Scott PG, Dodd CM, Tredget EE, Ghahary A, Rahemtulla F (1996). Chemical characterization and quantification of proteoglycans in human post-burn hypertrophic and mature scars. *Clin Sci (Lond)* 90(5):417-25.

Scott PG, Dodd CM, Ghahary A, Shen YJ, Tredget EE (1998). Fibroblasts from post-burn hypertrophic scar tissue synthesize less decorin than normal dermal fibroblasts. *Clin Sci (Lond)* 94(5):541-7.

Seymour RA, Heasman PA (1988). Drugs and the periodontium. *J Clin Periodontol* 15(1):1-16.

Seymour RA, Thomason JM, Ellis JS (1996). The pathogenesis of drug-induced gingival overgrowth. *J Clin Periodontol* 23(3 Pt 1):165-75.

Shafer W, Hine MK, Levy BM (1983a). A textbook of oral pathology. 4 ed. Philadelphia: W.B. Saunders.

Shafer W, Hine MK, Levy BM (1983b). A textbook of oral pathology. 4 ed. Philadelphia: W.B. Saunders.

Shah M, Foreman DM, Ferguson MW (1995). Neutralisation of TGF-beta 1 and TGF-beta 2 or exogenous addition of TGF-beta 3 to cutaneous rat wounds reduces scarring. *J Cell Sci* 108 (Pt 3):985-1002.

Shapiro P (2002). Ras-MAP kinase signaling pathways and control of cell proliferation: relevance to cancer therapy. *Crit Rev Clin Lab Sci* 39(4-5):285-330.

Shashi V, Pallos D, Pettenati MJ, Cortelli JR, Fryns JP, von Kap-Herr C, Hart TC (1999). Genetic heterogeneity of gingival fibromatosis on chromosome 2p. *J Med Genet* 36(9):683-6.

Sheppard D (2005). Integrin-mediated activation of latent transforming growth factor beta. *Cancer Metastasis Rev* 24(3):395-402.

Shirasuna K, Okura M, Watatani K, Hayashido Y, Saka M, Matsuya T (1988). Abnormal cellular property of fibroblasts from congenital gingival fibromatosis. *J Oral Pathol* 17(8):381-5.

Sibilia M, Fleischmann A, Behrens A, Stingl L, Carroll J, Watt FM, Schlessinger J, Wagner EF (2000). The EGF receptor provides an essential survival signal for SOS-dependent skin tumor development. *Cell* 102(2):211-20.

Singer SL, Goldblatt J, Hallam LA, Winters JC (1993). Hereditary gingival fibromatosis with a recessive mode of inheritance. Case reports. *Aust Dent J* 38(6):427-32.

Singh P, Reimer CL, Peters JH, Stepp MA, Hynes RO, Van De Water L (2004). The spatial and temporal expression patterns of integrin alpha9beta1 and one of its ligands, the EIIIA segment of fibronectin, in cutaneous wound healing. *J Invest Dermatol* 123(6):1176-81.

Soo C, Hu FY, Zhang X, Wang Y, Beanes SR, Lorenz HP, Hedrick MH, Mackool RJ, Plaas A, Kim SJ, Longaker MT, Freymiller E, Ting K (2000). Differential expression of fibromodulin, a transforming growth factor-beta modulator, in fetal skin development and scarless repair. *Am J Pathol* 157(2):423-33.

Sporn MB, Roberts AB (1990). The transforming growth factor-betas: past, present, and future. *Ann N Y Acad Sci* 593(1-6).

Tarnow DP, Magner AW, Fletcher P (1992). The effect of the distance from the contact point to the crest of bone on the presence or absence of the interproximal dental papilla. *J Periodontol* 63(12):995-6.

Tipton DA, Howell KJ, Dabbous MK (1997). Increased proliferation, collagen, and fibronectin production by hereditary gingival fibromatosis fibroblasts. *J Periodontol* 68(6):524-30.

Tipton DA, Dabbous MK (1998). Autocrine transforming growth factor beta stimulation of extracellular matrix production by fibroblasts from fibrotic human gingiva. *J Periodontol* 69(6):609-19.

Tipton DA, Woodard ES, 3rd, Baber MA, Dabbous M (2004). Role of the c-myc proto-oncogene in the proliferation of hereditary gingival fibromatosis fibroblasts. *J Periodontol* 75(3):360-9.

Trackman PC, Kantarci A (2004). Connective tissue metabolism and gingival overgrowth. *Crit Rev Oral Biol Med* 15(3):165-75.

Trojanowska M, Wu LT, LeRoy EC (1988). Elevated expression of c-myc proto-oncogene in scleroderma fibroblasts. *Oncogene* 3(4):477-81.

Uzel MI, Kantarci A, Hong HH, Uygur C, Sheff MC, Firatli E, Trackman PC (2001). Connective tissue growth factor in drug-induced gingival overgrowth. *J Periodontol* 72(7):921-31.

Wang DZ, Hammond VE, Abud HE, Bertoncello I, McAvoy JW, Bowtell DD (1997). Mutation in *Sos1* dominantly enhances a weak allele of the EGFR, demonstrating a requirement for *Sos1* in EGFR signaling and development. *Genes Dev* 11(3):309-20.

Wang JF, Olson ME, Reno CR, Kulyk W, Wright JB, Hart DA (2000). Molecular and cell biology of skin wound healing in a pig model. *Connect Tissue Res* 41(3):195-211.

Weller A, Beck S, Ekblom P (1991). Amino acid sequence of mouse tenascin and differential expression of two tenascin isoforms during embryogenesis. *J Cell Biol* 112(2):355-62.

Wright H, Chapple ILC, Cooper P, Matthews JB (2001). TGF-beta isoforms and TGF-beta receptors in drug-induced and hereditary gingival overgrowth. *J Oral Pathol Med* 30(5):281-9.

Wright H, Chapple ILC, Cooper P, Matthews JB (2006). Platelet-derived growth factor (PDGF) isoform and PDGF receptor expression in drug-induced gingival overgrowth and hereditary gingival fibromatosis. *Oral Diseases* 12(3):315-23.

Wynne SE, Aldred MJ, Bartold PM (1995). Hereditary gingival fibromatosis associated with hearing loss and supernumerary teeth--a new syndrome. *J Periodontol* 66(1):75-9.

Xiao S, Wang X, Qu B, Yang M, Liu G, Bu L, Wang Y, Zhu L, Lei H, Hu L, Zhang X, Liu J, Zhao G, Kong X (2000). Refinement of the locus for autosomal dominant hereditary gingival fibromatosis (GINGF) to a 3.8-cM region on 2p21. *Genomics* 68(3):247-52.

Xiao S, Bu L, Zhu L, Zheng G, Yang M, Qian M, Hu L, Liu J, Zhao G, Kong X (2001). A new locus for hereditary gingival fibromatosis (GINGF2) maps to 5q13-q22. *Genomics* 74(2):180-5.

Yamasaki A, Rose GG, Pinero GJ, Mahan CJ (1987). Ultrastructure of fibroblasts in cyclosporin A-induced gingival hyperplasia. *J Oral Pathol* 16(3):129-34.

Ye X, Shi L, Cheng Y, Peng Q, Huang S, Liu J, Huang M, Peng B, Bian Z (2005). A novel locus for autosomal dominant hereditary gingival fibromatosis, GINGF3, maps to chromosome 2p22.3-p23.3. *Clin Genet* 68(3):239-44.

Zetu L, Wang HL (2005). Management of inter-dental/inter-implant papilla. *J Clin Periodontol* 32(7):831-9.

Zhang Y, Guo C, Yu G (2005). A pilot study of fatty acid metabolism in oral squamous cell carcinoma. *Int J Oral Maxillofac Surg* 34(1):78-81.

Zhu KQ, Engrav LH, Tamura RN, Cole JA, Muangman P, Carrougher GJ, Gibran NS (2004). Further similarities between cutaneous scarring in the female, red Duroc pig and human hypertrophic scarring. *Burns* 30(6):518-30.