Use of Allelic Loss to Predict Malignant Risk for Low-Grade Oral Epithelial Lesions

by

Xing Cheng
M.Sc., Xian Medical University, 1986

A THESIS SUBMITTED IN PARTIAL FULFILLMENT OF
THE REQUIREMENTS FOR THE DEGREE OF
MASTER OF SCIENCE
in

THE FACULTY OF GRADUATE STUDIES

(Department of Oral Biological and Medical Sciences, Faculty of Dentistry)

We accept this thesis as conforming
to the required standard

THE UNIVERSITY OF BRITISH COLUMBIA

November 1999

Department of Oral Biological and Medical Sciences
The University of British Columbia
Vancouver
Canada

Date Dec 17, 1999

ABSTRACT

Oral squamous cell carcinomas (SCC) are believed to develop through progressing stages of oral premalignant lesions (histologically divided into hyperplasia, mild dysplasia, moderate dysplasia, severe dysplasia and carcinoma in situ, CIS) before finally become invasive. Prognosis is poor once invasion occurs and SCC is formed. The key to improve this gloomy prognosis may lie in early diagnosis and proper management of oral premalignant lesions.

However, the majority of oral premalignant lesions, particularly low-grade lesions (hyperplasia, mild and moderate dysplasia) do not progress into cancer. Since carcinogenesis is underlain by changes to critical control genes, it is hypothesized that the small percentage of progressing premalignancies differs genetically from the majority of non-progressing lesions. One of the best approaches to identifying genetic changes critical to oral cancer progression is to compare progressing and non-progressing oral premalignant lesions. However, such samples are rare, and little information is available on genetic changes in progressing and non-progressing lesions.

This thesis, for the first time, compared genetic changes in 116 cases of progressing and non-progressing low-grade oral premalignant lesions by microsatellite analysis for loss of heterozygosity (LOH) using 19 probes for 7 chromosome arms.

The progressing and non-progressing cases showed dramatically different LOH patterns of multiple allelic losses. An essential step for progression seems to involve LOH at 3p and/or 9p as virtually all progressing cases showed such loss. However, LOH at 3p and/or 9p also occurred in non-progressing cases. Individuals with LOH at 3p and/or 9p but no other arms exhibit only a

slight increase of 3.8-fold in relative risk for developing cancer. In contrast, individuals with additional losses (on 4q, 8p, 11q, 13q or 17p), which appeared uncommon in non-progressing cases, showed 33-fold increases in relative cancer risk.

The results suggest that LOH patterns will facilitate the prediction of the malignant potential of low-grade premalignancies. They also demonstrate the predictive value of assaying allelic loss at arms other than 3p and/or 9p. We may more precisely predict the malignant potential of low-grade premalignancies if we combine molecular analysis with the clinical assessment to premalignent lesions.

Clinically, the data also support the belief that the molecular tools such as microsatellite analysis for LOH may be used in differentiating between progressing and non-progressing lesions. The identification of molecular changes that can be used to predict the likely behavior of low-grade lesions would allow the clinician to identify which patients with low-grade lesions should be managed more aggressively and thus, should improve prognosis.

TABLE OF CONTENTS

ABSTRACT ii

TABLE OF CONTENT iv

LIST OF TABLES vii

LIST OF FIGURES viii

ABBREVIATIONS ix

ACKNOWLEDGMENTS xi

DEDICATION xii

1. INTRODUCTION 1

1.1. Importance of studying oral premalignant lesions 1

1.2.Oral mucosa 2

1.3.Oral premalignant lesions and their relation to oral SCC 2

1.4. Problems with the histological progression model 5

1.5. Molecular biology of carcinogenesis 6

1.5.1. Genetic pathway of carcinogenesis 6

1.5.2. The major genes involved in tumorigenesis 9

1.6. Loss of heterozygosity (LOH) and microsatellite analysis 11

1.7. LOH in oral and head and neck malignant lesions 13

1.8. LOH in oral and head and neck premalignant lesions 18

1.9. A molecular progressing model for oral SCC 21

2. STATEMENT OF THE PROBLEMS 23

3. OBJECTIVES 25

4. HYPOTHESIS 26

5. EXPERIMENTAL DESIGN AND STATISTICAL ANALYSIS 26

5.1. Experimental design 27

5.2. Statistical analysis 28

6. MATERIALS AND METHODS 29

6.1. Sample collection. 29

6.2. Sample sets 29

6.3. Histological diagnostic criteria for the samples 31

6.4. Slide preparation 32

6.5. Microdissection 33

6.6. Sample digestion and DNA extraction 33

6.7. DNA quantitation 34

6.8. Primer-extension preamplification (PEP) 34

6.9. Coding samples 35

6.10. End-labeling 35

6.11. PCR amplification 35

6.12. Scoring of LOH 36

7. RESULTS 38

7.1. Frequency of allelic loss 38

7.2. Pattern of allelic loss 39

7.3. Progression risk 41

7.4. Comparison of LOH pattern in matching premalignant and malignant lesions 44

7.5. Clinical history of the lesions. 46

8. DISCUSSION 53

8.1. High frequency of allelic loss characterized dysplastic lesions 53

8.2 Increased frequency of allelic loss in progressing lesions 54

8.3. The pattern of allelic loss characterized progressing lesions 55

8.4. LOH as markers to predict cancer risk - further statistic analysis..... 57

8.5. Most progressed lesions may be derived by clonal outgrowth from the earlier lesions. . 60

8.6.Does evidernce of recurrence serve as a further indicator of cancer risk in premalignant lesions?..... 61

8.7. Summary 63

9. REFERENCES 65

10. APPENDIX.....76

LIST OF TABLES

Table 1. LOH frequencies (%) in Head and Neck and Oral Cancers..... .76

Table 2. LOH and oral premalignant lesions.....20

Table 3. Samples sets and groups.....30

Table 4. Accumulation of allelic loss in progressing and non-progressing lesions.....38

Table 5. Patterns of allelic loss in progressing and non-progressing lesions.....40

Table 6. The time between initial biopsy and current date /the date when lesion has progressed to SCC.....78

Table 7. Probability of lesions not progressing to cancer after 5 years follow-up.....43

Table 8. Comparisons of LOH patterns in initial biopsies with that seen in CIS/SCC that later developed at the same anatomical site.....44

Table 9. Characteristics of patients with dysplasia.....46

Table10. LOH frequencies and clinical history in progressing lesions.....47

Table11. Allelic loss in recurrent premalignant lesions without a history of progression.....52

LIST OF FIGURES

Figure 1. Histological progression model of oral premalignant and malignant lesions.....4

Figure 2. Genetic pathway of carcinogenesis.....8

Figure 3. Tumor Progression model for head and neck cancers as proposed by Califano *et al* 1996.....22

Figure 4. Probability of having no progression to cancer, according to LOH pattern 42

Figure 5. LOH analysis of 2 patients (*a, b*) 45

ABBREVIATIONS

APC	adenomatous polyposis coli gene
BCCA	British Columbia Cancer Agency
bcl-1, 2	B-cell lymphoma
CDK	Cyclin-dependent kinase
CIS	Carcinoma *in situ*
DNA	Deoxyribonucleic acid
doc1 VHL	The gene responsible for von Hippel-Lidadu syndrome
erbB	Erythroblastosis
FHIT	Fragile histidine triad
H&E	Hematoxylin and eosin
HHSCC	Head and neck SCC
LOH	Loss of heterozygosity
MEN1	Multiple endocrine neoplasia type 1
NBCCS	Nevoid basal cell carcinoma syndrome
NF1,2	neurofibromatosis type I and II
PEP	Primer-extension preamplification
PC	Phenol-chloroform
PCR	Polymerase chain reaction
p16/INK4A/MTS-1/CDK2A	A tumor suppressor gene, encodes a cell cycle protein that halt cell-cycle progression
ras	Rat sarcoma
Rb	Retinoblastoma gene
RFLP	Restriction fragment length polymorphism

SCC	Squamous cell carcinoma
SDS	Sodium dodecyl sulfate
TSG	Tumor suppressor gene
TβR-II	Transforming growth factor type II receptor
UBC	University of British Columbia
WHO	World Health Organization

ACKNOWLEDGMENTS

I would like to express my deepest thanks to my supervisors, Dr. Lewei Zhang and Dr. Miriam P. Rosin, for giving me the opportunity to learn and earn an M.Sc. degree under their professional guidance, as well as their support throughout my degree. I am also grateful to Dr. Robert Priddy and Dr. Joel Epstein for their valuable contributions to clinical issues in my thesis. Thanks also to Dr. Douglas Waterfield for chairing my final oral examination. I appreciate very much the assistance of all the people in the laboratory. Special thanks go to my dearest friend, Xiao Lei Zhang for her special support and understanding.

DEDICATION

To my Dear Mom and Dad
To my Dearest Daughter

1. INTRODUCTION

.1. Importance of studying oral premalignant lesions

Head and neck cancers, including those of the mouth and upper air and food passages (oral cavity, oropharynx, nasopharynx, hypopharynx, and larynx), the salivary glands, and thyroid, account for approximately 6% of all human malignancies in the western world. The incidence is much higher in the Far East and India in particular with up to 40% of malignancies occurring in the head and neck region. The prognosis of oral cancer has not significantly improved during the past two decades: the 5-year-survival rate is still less than 50% and is one of the lowest among the major types of cancers despite recent advances in surgery, radiotherapy, and chemotherapy (Raybaud-Diogene *et al* 1996; Todd *et al* 1995). As oral cancer is believed to progress from oral premalignant lesions, the key to improve the gloomy prognosis of oral cancer may lie in early diagnosis and proper management of oral premalignant lesions.

The research of our lab focuses on oral premalignant and malignant lesions. This thesis represents one aspect of the focus the investigation of molecular changes in early oral premalignancies of oral mucosa.

1.2. Oral mucosa

The oral cavity is lined by oral mucosa, which consists of overlying epithelium and underlying lamina propria. The overlying epithelium of oral mucosa is stratified squamous epithelium. The connective tissue lamina propria underneath the epithelium contains blood and lymphatic vessels, small nerves, fibroblasts, collagen, and elastic fibers. The stratified squamous epithelium could be divided largely into basal and prickle cells in addition to there are other types: merkel, langerhans and melanocyte cells. The one-layered basal cells separate the overlying epithelium from the underlying connective tissue. They are the only cells that have the capacity to divide in the epithelium and subsequently give rise to either more new basal cells or differentiate into prickle cells located above them. The majorities of oral premalignant and malignant lesions arise from this stratified squamous epithelium of oral mucosa and the malignant tumors are called squamous cell carcinoma (SCC).

1.3. Oral premalignant lesions and their relation to oral SCC

Oral SCC is believed to be a result of a multistage carcinogenesis process over a long period of time. This multistage process involves progression from normal to premalignant lesions and finally invasive SCC. A premalignant or precancerous lesion has been defined by the World Health Organization (WHO, 1978) as a morphologically altered tissue in which cancer is more likely to occur than in its apparently normal counterpart. In the oral cavity, most premalignant lesions present clinically as leukoplakias. Other types of clinical forms exist, such as erythroplakia and possibly lichen planus (WHO 1978). Leukoplakia means a "white patch" and occurs on mucous membranes such as the mucosa of the oropharynx,

larynx, esophagus, and genital tract. Not necessarily white, leukoplakias also may appear yellow to light brown, especially in smokers. The World Health Organization (WHO, 1978) defines leukoplakia in the oral cavity as a white patch or plaque of oral mucosa that cannot be characterized clinically or pathologically as any other diagnosable disease and is not removed by rubbing. It is only a clinical term.

When a biopsy is taken, a leukoplakia will show microscopically hyperkeratosis and/or epithelial hyperplasia (acanthosis) with or without epithelial dysplasia.

Dysplastic lesions are further divided into mild, moderate, and severe forms depending upon how much of the tissue is dysplastic. Mild dysplasia is lesions in which the dysplastic cells are confined to the basal layer and the cells exhibit the smallest degree of the above changes. With moderate and severe dysplasia, the epithelial layers involved and the severity of the cellular changes are progressively increased. In carcinoma *in situ*, the dysplastic cells occupy the entire thickness of the epithelium (bottom to top changes) although the basement membrane is still intact. Invasion of dysplastic cells through the basement membrane into the underlying stroma and/or the dissemination of these cells to other sites through lymphoid and circulatory systems are events associated with development of invasive SCC.

The presence and absence of dysplasia and the degree of dysplasia is believed to have a huge impact on the malignant risk of the premalignant lesions. All studies to date have shown that leukoplakia with dysplasia has a higher malignant risk than leukoplakia without dysplasia. A large clinical study by Silverman *et al* (1984) found that during a mean onset of 7.2 years after presentation, more than 36% of leukoplakia lesions with microscopic epithelial dysplastic features eventually underwent malignant transformation whereas leukoplakia without dysplasias only demonstrated a malignancy rate of 15%. The risk of dysplasia and degree of dysplasia is further demonstrated by studies from the uterine cervix and other

systems and organs including skin and respiratory system. As a result, currently the gold standard for judging the malignant potential of premalignant lesions in these organs and systems, including the oral cavity, is the presence and degree of dysplasia.

Using these criteria, a histological progression model has been established for the oral cavity (Fig. 1). Premalignant lesions are classified histologically into categories with progressively increased risk of becoming invasive SCC: epithelial hyperplasia (without dysplasia), mild, moderate and severe dysplasias, and carcinoma *in situ* (CIS).

Figure 1: Histological progression model of oral premalignant and malignant lesions

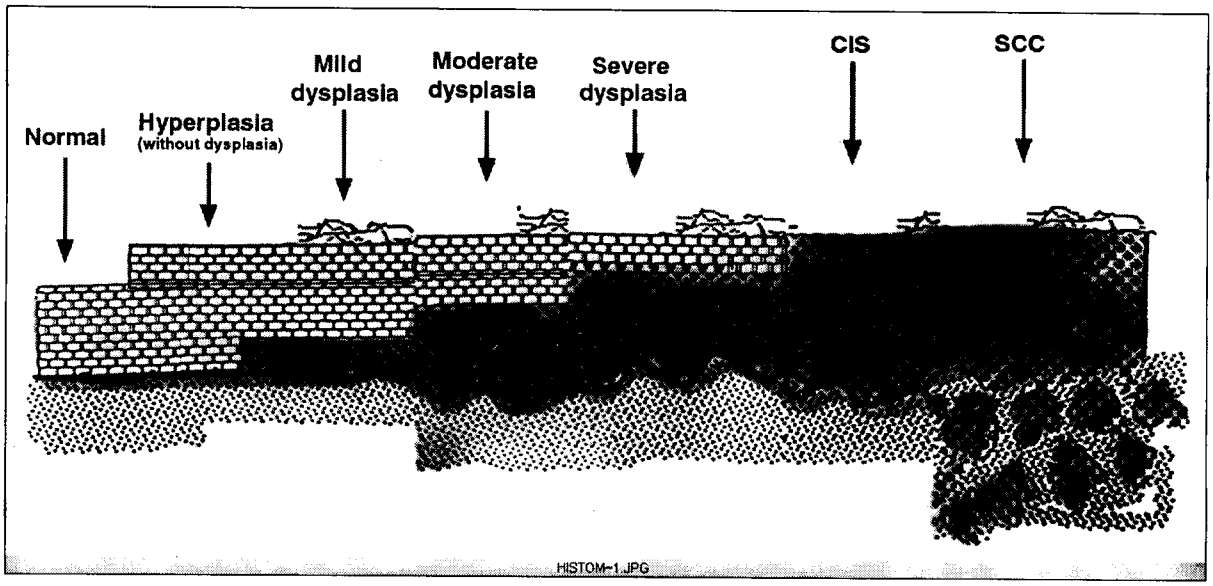

Other factors also affect the malignant potential of oral premalignant lesions. These include location and duration of the lesion, gender of the patient, appearance of the lesion (homogenous vs non-homogenous) and presence of *C. albicans* (Waal, 1997). Most studies on the malignant transformation of oral premalignant lesions have been done on leukoplakias (clinical presentation of oral premalignant lesions), frequently without knowledge of dysplasia

for all the study cases. The reported malignant risk for leukoplakia varies from study to study, ranging from as low as 0.13% to as high as 24% depending upon the patient population and follow-up time (Papadimitrakopoulou *et al*, 1997; Lumerman *et al*, 1995; Silverman *et al,* 1984).

1.4. Problems with the histological progression model

The histological progression model has a better predictive value for high-grade preinvasive lesions (severe dysplasia and CIS) which are believed by many to have a much higher possibility of progression into invasive lesions than low-grade lesions including hyperplasia without dysplasia and those with low-grade dysplasia (mild and moderate dysplasias) if left untreated. Some even, believe that oral CIS will inevitably become cancer if left untreated (Regezi *et al*, 1989). As a result, high-grade preinvasive lesions are generally treated aggressively, and the histological progression model has served as a good guidance for the aggressive treatment.

While the histological progression model has a good or reasonable predictive value for high-grade preinvasive lesions, it is poor at predicting the malignant potential of low-grade lesions. This model is more problematic in guiding the treatment of the low-grade lesions. The majority of these low-grade lesions do not progress into oral cancer, either remaining static or regressing, with only a small percentage progressing. On the other hand, these low-grade lesions constitute the bulk of leukoplakias and account for more than 90% of leukoplakias (hyperplasia without dysplasia, 80.1%; early dysplasia, 12.2%; late dysplasia, 4.5% and SCC, 3.1%) (Waldron Lumerman *et al*, 1975). This poses a management dilemma for clinicians. Aggressive treatment does not seem to be justified for the majority of these

lesions, both in terms of side effects and cost. New methods that could identify that small percentage of progressing low-grade lesions from the majority of non-progressing lesions are highly desired.

The significance of establishing these new methods lies in two aspects. First, this will facilitate the understanding of the mechanisms of early carcinogenesis; and second, this will have direct impact on the clinical management of these lesions. If we could understand the critical events occurring during early carcinogenesis, we may not only be able to predict the malignant potential at a very early stage, but can also plan management of this small percentage of progressing lesions accordingly (e.g., aggressive treatment or chemoprevention). Successful treatment of these early lesions and prevention of their progression will decrease the mortality and morbidity of oral SCC drastically.

A central dogma of carcinogenesis is that alteration to critical control genes underlies malignant transformation. The investigation of these critical changes in genes has been greatly facilitated recently with the rapid development of molecular biology techniques. This thesis has investigated some of the molecular changes in early oral premalignant lesions.

1.5. Molecular biology of carcinogenesis

1.5.1. Genetic pathway of carcinogenesis

In 1976, Nowel proposed that neoplastic transformation occurred in a single cell that had a critical genetic alteration giving it a growth advantage over its neighboring cells. The tissue would then go on to accumulate multiple mutations with these subsequent mutations being random in nature; however, the determination of which mutated cells would expand

into genetic clones in the tissue would be dependent on a variety of intracellular and environmental factors, including earlier mutations. Thus, all daughter cells in a tumor would share early initiating events but during tumorigenesis subclones would arise with additional genetic changes (that give them a selective advantage) and lead to heterogeneity. The non-random nature of this mutation selection is responsible for the preferred molecular pathways that are envisaged for many cancers. Ilyas Lumerman *et al* (1996) summarized that for a normal cell to become malignant, it must acquire the stepwise accumulation of genetic changes and a minimum number of necessary mutations which help it to overcome growth controls. These mutations and the order of development of the mutation profile comprise the "genetic pathway" of carcinogenesis.

Figure 2. Genetic pathway of carcinogenesis

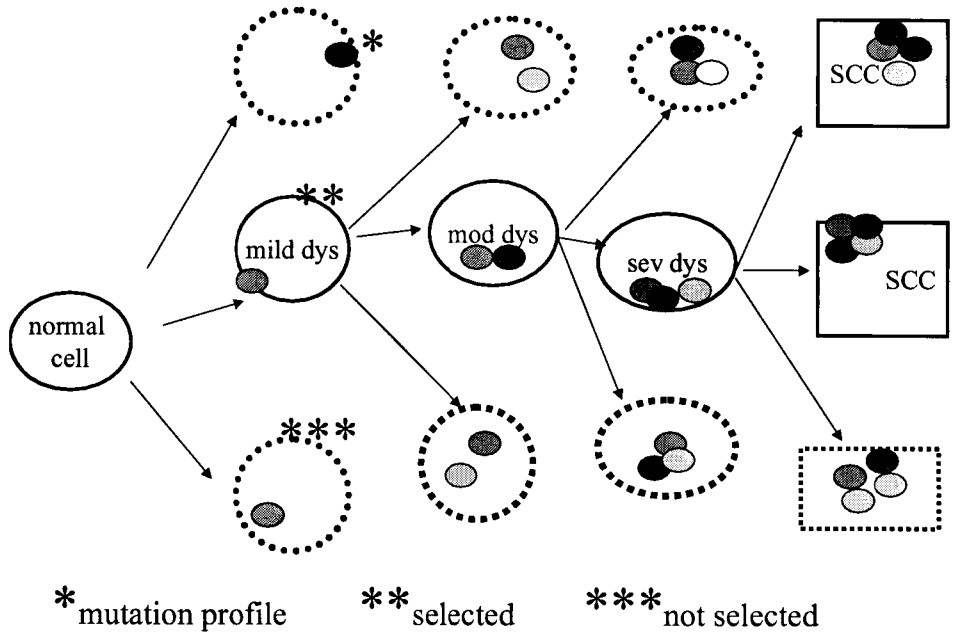

*Mutation profile: the group of mutations which are essential for tumour development.
**A cell, gets greatest survival advantage over its surrounding cells, will undergo colonial expansion and outgrowth, becomes predominant.
***Not selected, become apoptosis.

The understanding of the genetic pathways is essential in identifying those lesions that are following the pathways to cancer from those lesions with less critical genetic changes and with less cancer risk. Since the alteration to critical control genes underlies malignant transformation, it may be logical to assume that progressing premalignant lesions are genetically different from morphologically similar non-progressing lesions. The identification of molecular changes that can be used to predict the likely behavior of low-

grade lesions would allow the clinician to identify which patients with low-grade lesions should be managed more aggressively (either by more frequent screening or by early treatment, using traditional approaches such as surgery, or newer techniques such as chemopreventive regimes), and to better control and prevent the progression of premalignant lesions to cancer.

1.5.2. The major genes involved in tumorigenesis

It is now well established that clonal evolution of cancer is due to a progressive accumulation of critical genetic alterations, including at least two large groups: (1) the proto-oncogenes, which can be activated in the tumorigenic process to increase cell proliferation and induce malignant transformation, and (2) the tumor suppressor genes (TSGs), which maintain several growth control checkpoints and control the ability of cells to invade or metastasize.

Proto-oncogenes code for proteins that regulate the many functions of the normal cell, including the control of cell division, the production of enzymes that alter cellular activity, and the production of intercellular adhesion molecules and cell surface molecules that are bound by extracellular molecules. They include genes for growth factors, growth factor receptors, protein kinases, signal transducers, nuclear phosphoproteins and transcription factors. Proto-oncogenes act in a dominant fashion to positively regulate cell growth and differentiation. Mutation of these proto-oncogenes to oncogenes can occur in the coding region of gene, resulting in alteration of structure and activity in coded proteins. Many oncogenes have been identified in the literature; however, few of them have been reported to occur in HNSCC. Some of the oncogenes that have been found altered or expressed at

abnormal levels in head and neck cancers are *ras, cyclin-D1, myc, erbB, bcl-1, bcl2, int-2 CK8 and CK19* (Staibano *et al*, 1998; Kannan *et al* 1996; Bartkova *et al* 1995; Xu *et al* 1995; Gaffey *et al* 1995; Michalides *et al* 1995; Anderson *et al* 1994; Clark *et al* 1993; Eversole *et al* 1993; Wong *et al* 1993; Riviere *et al* 1990; Yokota *et al* 1986).

In contrast, TSGs function antagonistically with cellular proto-oncogenes to negatively regulate cell growth and differentiation. The functions of TSGs must be lost in order for tumorigenesis to occur. According to Knudson's hypothesis (1985), both copies of a tumor suppressor gene have to be inactivated for its protective function to be lost in a cell. Experience with known suppressor genes, such as the retinoblastoma gene, suggests that this process involves two separate events, the first quite often involving a point mutation in one allele, followed by loss of loci containing the wild type gene in the remaining allele. Some of the TSGs involved in head and neck cancers include *p53, Rb (retinoblastoma), and p16INK4A* (Gallo *et al* 1999; Jares *et al*, 1999; Liggett *et al*, 1999; Papadimitrakopoulou *et al,*1999; Sartor *et al,* 1999; Partridge *et al*, 1999a and 1998; Pavelic *et al*,1997; Reed *et al* 1996; Gleich *et al* 1996; Largey *et al* 1994). Other potential candidates are *FHIT (*fragile histidine triad), *APC* (adenomatous polyposis coli), *doc-1 VHL* (the gene responsible for von Hippel-Lidau syndrome) and *TβR-II* (the gene coding for transforming growth factor type II receptor). (Croce *et al*, 1999; Uzawa *et al* 1999 and 1994; Mao *et al* 1998 and 1996; Waber *et al* 1996;Todd *et al* 1995).

This meticulous balance between growth inducers (coded by proto-oncogenes) and suppressors (coded by tumour suppressor genes) controls the rate of division in normal cells. These genes are altered through a multistep process in which a cell accumulates many genetic changes, breaking the balance of normal cell growth and leading to the malignant phenotype. Recent advancement in the techniques of molecular analysis has rapidly revolutionized our

ability to look at these genetic alterations. My research will focus on loss of tumor suppressor genes (TSGs).

Functional loss of TSGs is one of the most common genetic alterations during carcinogenesis (Leis *et al*, 1996). Therefore, defining chromosomal regions harboring biologically important suppressor genes may have broad practical implications not only on our comprehension of progression of tumors but also on the clinical management of cancers and premalignant lesions. This thesis has studied regions of chromosome loss that contain presumptive TSGs by employing a polymerase chain-based *microsatellite analysis* for *loss of heterozygosity (LOH).*

1.6. Loss of heterozygosity (LOH) and microsatellite analysis

LOH is defined as a loss of genomic material (as small as a few thousand nucleotides to as large as a whole chromosome) in one of a pair of chromosomes. The LOH assay is designed to assess polymorphic chromosomal regions that map close to or within putative or known recessive cancer-related genes. The concept of LOH is consistent with Knudson's two-hit hypothesis, which states that inactivation of one of the two alleles by either a germline or somatic mutation will provide a growth advantage to the tumor cell because only one more inactivation of the remaining allele is needed. LOH analysis has been employed as a means of identifying critical loci containing TSGs and has subsequently led to the discovery of several important genes of this class, including the retinoblastoma (*Rb*) gene and the genes responsible for multiple endocrine neoplasia type 1 (*MEN1*), the nevoid basal cell carcinoma syndrome (*NBCCS*), adenomatous polyposis coli (*APC*), and neurofibromatosis type I and II (*NF1 and NFII*, respectively) (Fearon *et al,* 1997 and Ah-See *et al* , 1994).

Two methods have been available for the study of LOH or allelic loss: the more classical approach of restriction frequent length polymorphism (RFLP) analysis, and the newer method of microsatellite analysis. This thesis employed microsatellite analysis for at least two reasons. First, microsatellite repeat markers are highly polymorphic and well-distributed throughout the human genome. They show levels of heterozygosity between 30-80%, significantly above the level observed with the RFLP analysis based on base substitutions at endonuclease recognition sites. Second, this PCR-based approach is much more sensitive than the RFLP analysis and requires only small quantities of DNA (5 nanograms or less per reaction). For these reasons, the microsatellite analysis procedure has become the major tool for the majority of current LOH studies.

Microsatellites contain runs of short and tandemly iterated sequences of di, tri, or tetranucleotides, such as GTGTGT... or GTAGTAGTA... or GTACGTACGTA.... These short repetitive DNA sequences are called microsatellites. The number of such tandem repeats is found to be highly polymorphic in the population, with each individual typically containing a different number of copies (generally 4 to 40) of the repeat at each particular locus. In addition, they are well interspersed throughout the human genome (e.g., estimated every 30-60 KB for CA repeats) and are highly conserved through successive generations (Ah-See *et al* 1994). Testing of highly polymorphic microsatellite markers from a specific chromosomal region allows rapid assessment of allelic loss by comparing the alleles in tumor DNA to normal DNA. Therefore microsatellites are good way to research the TSGs either close to or within these chromosome spots. Loss of heterozygosity suggests that a putative tumor suppressor gene nearby may be also lost.

1.7. LOH in oral and head & neck malignant lesions

Recent studies including those from this lab have shown that the loss of specific regions of chromosomes that contain tumor suppressor genes is a common event in oral SCCs. In this thesis, microsatellite markers on chromosome arms 3p, 4q, 8p, 9p, 11q, 13q and 17p were used, since they have been reported to lie within regions most frequently lost in oral SCCs. Each of these regions will be discussed briefly.

Chromosome 3: High frequency of LOH at chromosome 3p has been reported in head and neck cancers (Table 1 in the appendix). The losses appear to center around 3p13-21.1, 3p21.3-23, and 3p24-25 (Partridge *et al,* 1999b, 1998; Scully *et al,* 1996; Partridge *et al*,1996; Roz *et al*, 1996; Maestro *et al*,1993). The number of regions showing allele loss at 3p (3p 12.1-14.2, 21.3-22.1 and 24-26) is consistent with the progressive accumulation of genetic errors during the development of oral SCC (Partridge *et al*, 1996).

Each of the three regions is presumed to contain at least one putative TSG. Within the region of 3p14.2 exists one of the most common fragile site locus, called FRA3B, in the human genome. Fragile sites are portions of chromosomes that are extremely weak and break easily. Consequently, these weak areas may be easy targets for carcinogens such as those found in tobacco. The gene, *FHIT* (Fragile histidine triad), was recently identified at this fragile site and appears to be involved in various cancers such as esophageal, gastric, colonic, breast, cervical, small cell lung, and head and neck carcinomas (Pennisi *et al,* 1996; Sozzi *et al,* 1996; Ohta *et al,* 1996; Wilke *et al,* 1996; Mao *et al* 1996a and Wu *et al* ,1994). It encodes a protein with 69% similarity to a *Schizosaccharomyces* pombe enzyme, diadenosine 5', 5'''-P1, P4-tetraphosphate (Ap4A) asymmetrical hydrolase which cleaves the AP4A

substrate into 5' - ADP and AMP. Current theories suggest that diadenosine tetraphosphate may accumulate in the cells in the absence of the normal expression of the gene and may eventually lead to DNA synthesis and cell replication (Mao *et al,* 1996).

Several recent studies have shown that *FHIT* may be significantly involved in oral SCC development (Croce *et al,* 1999; Mao *et al,* 1998a and 1998b) and suggest that alteration to this gene may play an important role in early stage in the development of this cancer (Mao *et al*, 1996b). It was recently suggested in some tissues and organs, particularly those associated with exposure to environmental carcinogens, alterations in *FHIT* occur quite early in the development of human cancer (Croce *et al*, 1999). Croce concluded that *FHIT* loss in bronchial tissue indicates the occurrence of genetic alterations associated with the early steps of carcinogenesis. LOH at 3p14 has been shown to be involved in oral premalignant lesions (Mao *et al,* 1996a).

Until now there is sufficient evidence for only one gene, *FHIT*, to be responsible for the LOH at the region 3p14.3, although the evidence in support of it being a TSG is still considered to be controversial (Mao *et al*, 1998b). TSGs that are responsible for LOH at the other two regions (3p24-pter, and 3p21.3) are still not clear. For example, the region of 3p24-25 contains the VHL gene, which is thought to be a member of a novel class of glycan-anchored membrane proteins that function in signal transduction and cell adhesion (Waber *et al*, 1996), and its alteration has been reported especially in VHL-associated cancers (van den Berg, *et al*, 1997; Kok *et al*, 1997 and Decker *et al*, 1997). Uzawa also mentioned the possibility that the VHL gene may in involved in oral SCC development (1998). However, mutations of the VHL gene could not be identified and the VLH gene was not inactivated by hypermethylation in HNSCC. Hypermethylation is an alternation method of inactivity of a gene that does not require direct mutation to the gene. It is possible that allelic loss of

chromosome arm 3p in HNSCC involves regions surrounding the VHL locus but does not include the VHL gene. Another TSG in HNSCC may exist in the regions surrounding D3S 1110 at 3p 25 (Uzawa *et al,* 1998; Waber *et al*, 1996).

Chromosome 9: LOH on 9p is by far the most commonly reported chromosomal defect in head and neck cancers, with LOH reported in 72% of malignant lesions. The most commonly affected region is chromosome 9p21-22. In addition, LOH at 9p22-q23.3 is also common (> 70% of head and neck cancers) (Scully *et al* 1996 and Nawroz *et al*, 1994). The putative TSGs are near the interferon locus and are not clearly identified.

At 9p21, the prime TSG candidate involved in the head and neck cancers is *p16* (also know as *MTS-1* for major tumor-suppressor 1, *INK4a* for inhibitor of cyclin-dependent kinase4a, and *CDKN2A* for cyclin-dependent kinase inhibitor 2A). The TSG *p16 (INK4A/MTS-1/CDKN2A)* encodes a cell cycle protein that inhibits cyclin-dependent kinases (CDK) 4 and 6, preventing phosphorylation of Rb protein and consequently inhibiting the cell cycle transition of the G1-S phase (Reed *et al*, 1996). The major biochemical effect of p16 is to halt cell-cycle progression at the G1/S boundary. The loss of p16 function may lead to cancer progression by allowing unregulated cellular proliferation (William *et al*, 1998).

Although mutations of this gene are not apparently frequent for oral cancer, this might suggest that either this gene is inactivated by an alternative mechanism such as homozygous deletion or by methylation of the 5'CpG-rich region, which results in a complete blook of gene transcription (Papadimitrakopoulou *et al*, 1997; Rawnsley *et al*, 1997; Matsuda *et al*, 1996 and Merlo *et al*, 1995). Reed and Papadimitrakopoulou found that ~80% of the head and neck cancers and premalignant lesions were p16 inactivated at the protein and/or DNA level and suggest that inactivation of p16 may play an important role in early head and neck cancer development (Papadimitrakopoulou *et al*, 1997 and Reed *et al*, 1996). Alternatively, another

tumor suppressor gene may exist in this region (Waber *et al*, 1997; Dawson *et al*, 1996; Reed *et al*, 1996).

Chromosome 17: LOH on 17p has been reported in 50% of head and neck cancers, most frequently involving 17p13 and 17p11.1-12 (Scully *et al*, 1996; Field *et al*, 1996; Adamson *et al*, 1994; Nawroz *et al*, 1994). The region 17p13 harbors the gene *p53* (17p13.1), which has been reported to have the highest frequency (~50%) of mutations in human cancers. Mutation at p53 is also one of the most common events in HNSCC (Lazarys *et al*, 1995). Its protein functions as mediator in several activities, including transcription activation, DNA repair, apoptosis, senescence, and G1 and G2 cell cycle inhibition. In addition, increasing evidence also shows that a region, defined by the cholinergenic receptor B1 (CHRNB1) locus at 17p11.1-12, that is tightly linked to the *p53* regions may contain a novel TSG.

Chromosome 4: LOH on chromosome 4 has been studied in cancers of many systems and organs including hepatocellular, bladder, ovarian and cervical cancers. The putative tumor suppressor locus was localized to a region near the epidermal growth factor gene on 4q25 and 4q24-26. Loss at 4q25 occurs in 70% of head and neck cancers (Pershouse *et al,* 1997) and loss at 4q26-28 occurs in 47% (Califano *et al,* 1996; Bockmihl *et al*, 1996). The combination of allelic deletions and chromosomal transfer studies strongly suggests the presence of a TSG within 4q24-26. This region was involved in >80% of the tumors examined, suggesting that a putative chromosome 4q TSG may play an important role in the evolution of HNSCC (Pershouse *et al*, 1997).

***Chromosome 8*:** Investigation of 8p regions in head and neck squamous carcinoma has shown a relatively high incidence of alterations (31%-67%) (Wu *et al,* 1997; Califano *et al,* 1996; Bockmuhl *et al,* 1996; Scholnick *et al,* 1996; El-Naggar *et al,* 1995; Field *et al,* 1995; Ah-aee *et al,* 1994; Li *et al,* 1994). Deletion mapping of oral and oropharyngeal SCC defines three discrete areas on chromosome arm 8p: 8p23, 8p22, and 8p12-p21 (Wu *et al,* 1997 and El-Naggar *et al,* 1995). Several studies have linked allelic loss at 8p to a higher stage (Wu *et al,* 1997) and poor prognosis (Scholnick *et al,* 1996 and Li *et al,* 1994).

***Chromosome 11*:** LOH on human chromosome 11 has also been commonly reported in a variety of human cancers, including HNSCC (39%-61%) (Lazar *et al,* 1998; Venugopalam *et al,* 1998; Bockmuhl *et al,* 1996; Califano *et al,* 1996; Uzawa *et al,* 1996; El-Nagger *et al,* 1995; Nawroz *et al,* 1994). The common region of loss at this chromosome seems to be near the INT-2 locus at 11q13 (Nawroz *et al,* 1994). It is possible that some of this region's allelic imbalance may be due to amplification rather than LOH (Nawroz *et al,* 1994). Amplification of this region associated with poor prognosis was also reported (Papadimitrakopoulou *et al,* 1997).

***Chromosome 13*:** More than half of HNSCCs shows LOH of 13q in regions close to the RB (retinoblastoma) locus, but not RB gene (52-67%) (Ogawara *et al,* 1998; Ishwad *et al,* 1996; Maestro *et al,* 1996; Bockmuhl *et al,* 1996; Califano *et al,* 1996; Nawroz *et al,* 1994). A hot spot of D13s133 at 13q14.3, which lies just telomeric to the RB gene, was reported (Yoo *et al,* 1994). A recent study done by Ogawara showed LOH on 13q14.3 correlated with lymph node metastasis of oral cancer ($p<0.0024$). His results also suggest that LOH on 13q is a common event in oncogensis and/or progression of oral SCC and the existence of a new

suppressor gene near D13S273-D13S176 loci which may play a role in these events since no significant variation in RB protein expression was detected (Ogawara *et al,* 1998). The study of Harada *et al,* (1999) confirmed that LOH in chromosome 13 showed a significant correlation with lymph node metastasis in esophageal squamous cell carcinoma, included in HNSCC. They reported that unidentified TSG(s) in region 13q12-13 might be involved.

1.8. LOH in oral and head & neck premalignant lesions

Since tumorigenesis is a sequential accumulation of genetic alterations, analysis of early and late stage lesions may define the genetic changes associated with the development and progression of HNSCC. Few studies (Table 2) have investigated the premalignant stages of the lesions while there are many studies of LOH on oral SCC. The main difficulties lie in the fact that: 1) premalignant lesions are small and therefore it is extremely hard to obtain sufficient amount of DNA for molecular analysis, 2) big hospitals or research centers typically have better access to cancers rather than premalignant lesions, and 3) it is much harder to microdissect premalignant lesions compared to carcinomas.

The limited number of studies on premalignant lesions either used only a small number of cases or primers, or did not correlate LOH with degree of dysplasia and mostly form high-grade dysplasias. Nonetheless, results from these studies clearly show that LOH is a frequent event in premalignant lesions (Califano *et al,* 1996; Mao *et al,* 1996a; Emilion *et al,* 1996; Roz *et al,* 1996; El-Naggar *et al,* 1995). For example, a similar frequency of LOH at 9p was reported in preinvasive lesions (71%) as in SCC (72%) (Van der Riet *et al,* 1994). This suggests that loss of 9p is an early event in the progression of oral cancer (Papadimitrakopoulou *et al,* 1997 and Van der Riet *et al,* 1994). Similarly LOH at 3p have been found to occur very early during oral carcinogenesis and in a significant number of oral

mild dysplasia or even hyperplasias (Zhang *et al,* 1997). On the other hand, data from this lab showed that LOH at 17p was not found in reactive hyperplastic lesions and mild dysplasia of oral mucosa, indicating loss at 17p occurs later than LOH at 3p and 9p (Zhang *et al,* 1997). El-Naggar and his colleges (1998) recently found LOH at 8p in 27% of the dysplastic lesions and in 67% of the invasive oral and laryngeal SCCs. The highest frequency of allele losses in dysplasia and cancer were detected in the same loci: 8p21 and 8p22. In addition, allelic losses in both dysplastic and corresponding invasive specimens were noted at the same loci, suggesting their emergence from a common preneoplastic clone. The studies suggested that inactivation of TSG(s) within these loci may constitute an early event in the evolution of oral and laryngeal SCCs.

Moreover, a study by Mao and co-workers (Mao *et al,* 1996a) showed that LOH in oral premalignant lesions could be used to predict risk of cancer progression of these premalignant lesions. They reported that the presence of LOH at 9p21 &/or 3p14 in oral leukoplakia was associated with a greater probability of progression of this premalignant lesion into SCC: 7 of 19 (37%) cases with such LOH progressed to SCC in their study, as compared to only 1 of 18 (6%) cases without LOH.

Table 2. LOH and oral premalignant lesions

Authors	Chromosome arm studied	Degree of oral dysplasias	LOH and risk of malignant transformation
Van der Riet, 1994	9p21-22	Severe dys/ CIS lesions	Not evaluated
El-Naggar, 1995	3p, 5q,8p, 9, 11q, 17	Severe dysplasia adjacent to cancer	LOH at 8p loci has higher risk of tumor's aggressive feature
Califano, 1996	3p, 4q, 6p, 8, 9p, 11q, 13q, 14q, 17p	Dysplasia with no indication of severity	Not evaluated
Mao, 1996a	3p14, 9p21	Reported as leukoplakias - some of which were dysplastic	Patients with LOH at 9p and/or 3p have higher risk of cancer development
Mao, 1996	5q (APC)	Dysplasia: 5 cases CIS: 3 cases	Not evaluated
Emilion, 1996	3p, 17p(p53), 18q(DCC)	Primary dysplasias: Mild: 8 cases Moderate: 4 cases Severe: 5 cases Dysplasia adjacent to cancer: Mild: 4 cases Moderate: 6 cases Severe: 3 cases	LOH was not associated with the degree of dysplasia, but the number of allelic loss increased while tumor developed.
Roz, 1996	3p	Severe/CIS lesions only	Not evaluated
Zhang, 1997	3p, 9p, 17p	Reactive lesions: 29 cases Mild dysplasias: 10 cases Moderate dysplasias: 11 cases Severe dys/CIS: 16 cases Cancer: 22 cases	Loss of more than one chromosome arm is associated with degree of dysplasia

El-Naggar, 1998	8p	Eight paired severe dysplasia and corresponding invasive lesions	Both lesions emergent from a common preneoplastic clone
Partridge, 1998	3p21 8p21-23 9p21 13q14.2 (Rb) 17p 11.2 (tp53) 18q21.1 (DCC)	31 Dysplasia with no indication of severity	The probability of progressing to SCC was much greater for cases showing AI at two or more relevant loci

1.9. A molecular progressing model for oral SCC

In the late 80s, Fearon and Volgelstein, among the first people to describe molecular progression, suggested that a) tumors progress via the activation of oncogenes and the inactivation of TSGs, each generating a growth advantage for a clonal population of cells; b) specific genetic events generally occur in a distinct order of progression; but c) the order of progression is not necessarily the same for each individual tumor, and therefore it is the accumulation of genetic events that determines tumor progression. It has been estimated that at least 6-10 independent genetic events are required in order for head and neck cancers to occur (Emilion *et al* 1996). It is now accepted that the histologic progression of oral cancer (from hyperplasia → mild dysplasia → moderate dysplasia → severe dysplasia → CIS → SCC) is underlain by the accumulation of such changes to critical genes. In a landmark study by Califano and his colleagues (1996), LOH was investigated in a whole spectrum of oral premalignant lesions including hyperplasia, dysplasia, CIS and SCC. The study proposed a

genetic progression model for oral carcinogenesis (Fig. 3). The model proposes that LOH at 9p is the earliest event associated with transition from normal to benign hyperplasia; LOH at 3p and 17p is associated with dysplasia, whereas CIS and SCC were characterized by additional deletions on 4q, 6p, 8, 11q, 13q, and 14q (Fig 3).

Figure 3 Tumor Progression Model for Head and Neck cancers as proposed by Califano *et al* 1996

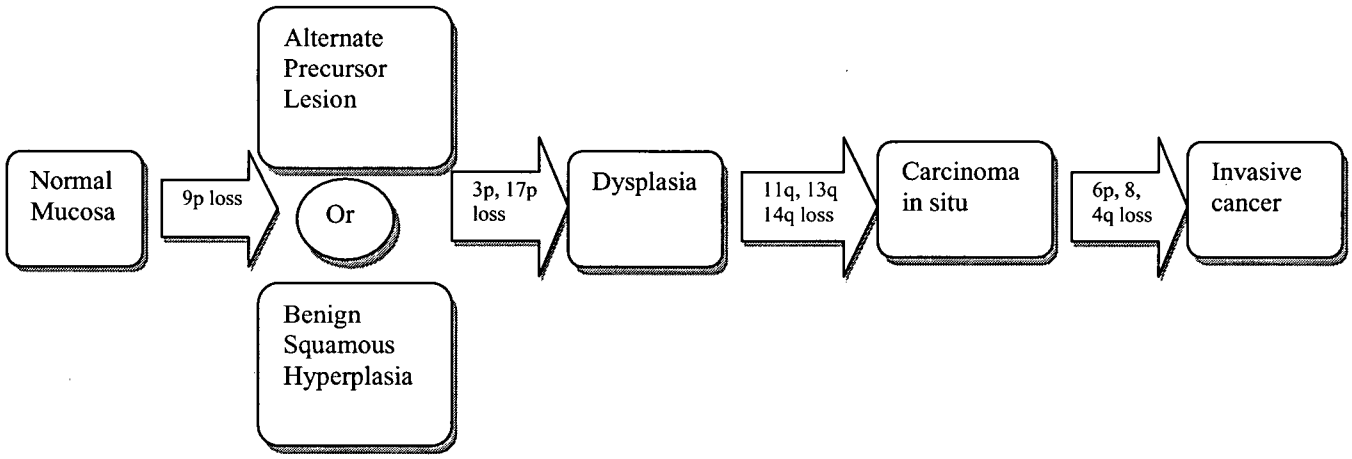

2. STATEMENT OF THE PROBLEMS

Oral SCC is believed to progress through stages of oral premalignant lesions (hyperplasia, mild dysplasia, moderate dysplasia, and severe dysplasia, CIS) before finally become invasive. While the prognosis of oral premalignant lesions are excellent, once invasion occurs and oral SCC is formed the prognosis is poor and about half of the patients die within 5 years of diagnosis despite recent advancement in treatment. Those who survive still face severe cosmetic and functional morbidity. The understanding and intervention of oral premalignant lesions will be critical in the reduction of the mortality and morbidity of oral SCC. However, the majority of oral premalignant lesions do not progress into oral SCC and aggressive treatment of these lesions is not justified. At present, we can not identify those progressing oral low-grade premalignant lesions from the majority of non-progressing low-grade oral premalignant lesions. Since cancer is underlain by changes to the critical control genes, the understanding of molecular changes during early oral cancer development may be critical in the establishment of molecular markers for the identification of high-risk oral premalignant lesions. It is likely that the progressing low-grade oral premalignant lesions are molecularly different from the morphologically similar non-progressing low-grade premalignant lesions. With the rapid development of molecular biology techniques, there have been numerous studies on the molecular changes in human cancers, including oral SCCs. However, few studies are done in oral premalignant lesions because these lesions are not readily available and are small in size. A number of studies done on premalignant lesions are all limited either in the number of cases used or the number of probes used. Furthermore, most of these studies were either done on high-grade oral premalignant lesions or the degree of dysplasia was not mentioned. There is a marked lack of information on the molecular

changes of low-grade oral premalignant lesions, which are the majority of oral premalignant lesions, and are the hardest to predict in terms of their malignant risk. A molecular model has been proposed by Califano *et al*, (1995) based on studies on oral premalignant and malignant lesions. However, the study merged all dysplasias together. It is well known that the prognosis of low-grade oral premalignant lesions (e.g. mild dysplasia) differs drastically from that of high-grade oral premalignant lesions (e.g., severe dysplasia). Furthermore, there is no data available on the characteristics of molecular changes of those oral premalignant lesions that have known to have progress into cancer. The main problem is that such lesions are hard to find. This thesis will investigate the molecular changes of low-grade oral premalignant lesions, and compare the characteristics of genetic changes of those premalignant lesions that have progressed into CIS or SCC with those with no known progressing history.

3. OBJECTIVES

1) To characterize the pattern of genetic changes in premalignant lesions by means of LOH analysis using microsatellite markers for the 7 chromosomal regions known to be frequently lost in oral tumors: 3p, 4q, 8p, 9p, 11q, 13q and 17p.

2) To determine whether the LOH profile was significantly altered in cases that have progressed to CIS or SCC as compared to those that have not.

4. HYPOTHESIS

1) Molecular changes as assayed by the LOH analysis occur early during oral carcinogenesis, including low-grade oral premalignant lesions.

2) Progressing early lesions (low-grade dysplastic and hyperplasia without dysplasia) are genetically different from morphologically similar non-progressing lesions.

If the data support the first hypothesis, it would suggest that loss of regions of chromosomes that contain presumptive tumor suppressor genes is critical for early oral carcinogenesis.

If the data support the second hypothesis, it would suggest that early lesions progressing to cancer, though morphologically indistinguishable from those without a history of progression, are in fact different genetically. It is this genetic difference that underlines the behavior of these lesions. It would also support the belief that the molecular tools such as microsatellite analysis for LOH may be used in differentiating between progressing and non-progressing lesions. The identification of molecular changes that can be used to predict the likely behavior of low-grade lesions would allow the clinician to identify which patients with low-grade lesions should be managed more aggressively, either by more frequent screening or by early treatment, using traditional approaches such as surgery, or newer techniques such as chemopreventive regimes.

5. EXPERIMENTAL DESIGN AND STATISTICAL ANALYSIS

5.1. Experimental design

This is a case – control study (Chap, 1997, p2 and King, 1996, p38). The study subjects were those who already had a certain condition (premalignant lesions known to have progressed to CIS or SCC): These subjects are the cases and this thesis investigated the characteristics shared by the cases. The comparison group (those lesions without progression history) – the controls – was selected so that it resembled the cases as closely as possible (Brunette, 1996). We tried to avoid the usual problems usually in a case control design: information bias or data collected in the past under uncertain conditions. First, there was no information bias in our study because there were no significant differences in quality or availability of data between the cases and controls. Second, the experimental data (LOH data) were collected under the same experimental conditions. Although some data were collected in the past under uncertain conditions, like gender, age, site and smoking history, there was no significant difference between cases and controls in terms of gender distribution, age distribution, site distribution, and smoking history (Table 9). These matched factors can no longer be evaluated as etiologic agents since they will be equalized in the cases and the controls (Brunette, 1996). Moreover, the histological diagnosis of hyperplasia or mild or moderate dysplasia was reconfirmed by two pathologists (LZ and RP) using criteria established by the World Health Organization (WHO collaborating Reference centre 1978).

This study was a retrospective design. We obtained some clinical information by tracking recurrent lesions as they appeared in our database and by following the case histories of treatment in hospital charts. However, there was no evidence that treatment was less

aggressive among progressing cases compared with those without a history of progression (see details in discussion part).

5.2. Statistical analysis

Associations between LOH and progression were examined using Fisher's exact test (two-tailed). Clinical differences between progressing and non-progressing groups were examined using either Fisher's exact test (gender distribution and smoking habit) or unpaired t-test (age and follow up time). All p values were two-sided. A P value of 0.05 or less was considered significant.

Time-to-progression curves were estimated by the Kaplan-Meier method and comparisons were performed using log-rank test (Chap, 1997 and Armitage *et al*, 1987). Relative risks were determined using Cox regression analysis (Chap, 1997 and Armitage *et al*, 1987).

6. MATERIALS AND METHODS

6.1. Sample collection.

This study used paraffin-embedded archival samples from the provincial Oral Biopsy Service of British Columbia. This centralized Oral Biopsy Service provides service to dentists and ENT surgeons throughout the province, at no cost to the provider or patient, with more than 3,500 biopsies of oral lesions received per year (19 years archived). This provides a large collection of early lesions that can be followed over time. Cases that progressed into cancer were identified by linking the database of this Service to the British Columbia Cancer Registry, which receives notification of all histologically confirmed cases of cancer and CIS diagnosed in the Province.

6.2. Sample sets

Two sample (archival paraffin blocks) sets were used (Table 3):

Set 1: Oral lesions from patients with no subsequent history of head and neck cancer. We refer to these cases as non-progressing.

Set 2: Oral lesions from patients that later progressed to CIS or SCC.

Both sets of samples included hyperplasia (without dysplasia) group and low-grade dysplasia (mild or moderate dysplasia) group.

Table 3. Samples sets and groups

Lesion Type	*Number of Cases*	
	Lesions with no history of head and neck cancer	**Lesions that later progressed to CIS or SCC**
Epithelial Hyperplasia (without dysplasia)	33	6
Mild Dysplasia (low-grade dysplasia)	31	9
Moderate Dysplasia (low-grade dysplasia)	23	14

The criteria for choosing Set 1 samples included:

1) A histological diagnosis of a case confirmed by two pathologists using criteria established by the World Health Organization (WHO collaborating Reference centre 1978).

2) The provision that the sample was large enough to yield sufficient DNA from both the epithelium and from the connective tissue for multiple LOH analyses.

3) Confirmation that these patients had no prior history of head and neck cancer and that they had not developed such cancer so far was obtained both from hospital records and by using a computer linkage with the British Columbia Cancer Registry. All but three of these cases had at least 3 years of follow up time.

The inclusion criteria for selection of the set 2 lesions in addition to those described for set 1 included:

1) Both the primary hyperplastic or dysplastic lesions and their matching CIS or SCC had to be from the same anatomical site as recorded on pathology reports and patients charts;

2) The interval between the primary lesions and later CIS or SCC had to be longer than 6 months. This criterion was used to exclude cases that might be due to inadequate biopsy, with the time interval chosen for exclusion being arbitrary.

6.3. Histological diagnostic criteria for the samples

The generally accepted histological diagnostic criteria for dysplasia includes loss of basal cell polarity, more than 1 layer of basaloid cells, increased nuclear to cytoplasmic ratio, drop-shaped rete ridges, irregular stratification, increased and/or abnormal numbers of mitosis in the basal compartment as well as increased mitotic figures in the superficial half of the epithelium, cellular pleomorphism, nuclear hyperchromatism, enlarged nucleoli, reduction of cellular cohesion, and keratinization of single cells or cell groups in the spinous cell layer (WHO collaborating Reference centre 1978).

Based on the above-mentioned criteria as well as the extent of the epithelial tissue that is dysplastic, dysplasias are divided into mild, moderate, and severe forms. Those classified as mild indicate that the dysplastic cells are confined to the basal layer and that they exhibit the smallest degree of changes. With moderate and severe dysplasias, the epithelial layers involved and the severity of the cellular changes increase progressively. In carcinoma *in situ*, the dysplastic cells occupy the entire thickness of the epithelium (from bottom to top), although the basement membrane is still intact. Invasion of dysplastic cells through the basement membrane into the underlying connective tissue and the dissemination of these cells to other sites through the circulatory systems are characteristics of malignancy (i.e., cancer) (Zhang *et al,* 1997) (Fig 1).

The histological diagnoses of the lesions were performed independently by Dr. R. Priddy and Dr. L. Zhang, oral pathologists at University of British Columbia. Only those cases in which the two pathologists agreed on the diagnosis were used for the study.

6.4. Slide preparation

A case was chosen after the pathologists agreed on the diagnosis, and after the determination that the block was big enough and contained sufficient epithelial and connective tissues for molecular analysis. The tissue block for the case was removed from the archive, one 5 micron thick slide was cut and stained with H&E (hematoxylin and eosin) and coverslipped for reference. The actual samples for microdissection were 12 microns thick and approximately 15 slides, each with multiple thick sections, were cut for each tissue block. They were also stained with H&E but left uncoverslipped. The H&E procedure for the slides is described below:

Baked at 37°C in an oven overnight, then at 60-65C^0 for 1 hour, and left at room temperature to cool;

Deparaffinized by two changes of xylene for 15 min each;

Dehydrated in graded ethanol (100%, 95% and 70%), 5 min each;

Hydrated by rinsing in tap water, 2 min;

Placed in Gill's Hematoxylin for 5 min;

Rinsed in tap water, 2 min;

Blued with 1.5 % (w/v) sodium bicarbonate, 1 min;

Rinsed in water, 2 min;

Counterstained with eosin for 10 sec;

Dehydrated in graded alchohol (75%, 95% and 100%), 3 min each;

Cleared in xylene, 3 min twice for coverslipping (for the H&E slide) or submitted for microdissection.

6.5. Microdissection

Microdissection of the specimens was either performed or supervised by Dr. L. Zhang. Areas of dysplasia were identified microscopically. Epithelial cells in these areas were then meticulously dissected from adjacent non-epithelium tissue under an inverted microscope using a 23-G needle. The non-epithelial underlying stroma dissected out from the same tissue block was used as controls (Zhang *et al*, 1997).

6.6. Sample digestion and DNA extraction

The microdissected tissue was placed in a 1.5 ml eppendorf tube and digested in 300 μl of 50 mM Tris-HCL (pH 8.0) containing 1% sodium dodecyl sulfate (SDS) proteinase K (0.5 mg/ml) at $48C^0$ for 72 or more hours. During incubation, samples were spiked with 10 or 20 μl of fresh proteinase K (20 mg/ml) twice daily. The DNA was then extracted 2 times with PC-9, a phenol-chloroform mixture, precipitated with 70% ethanol in the presence of glycogen, and washed with 70% ethanol. The samples were then re-suspended in LOTE, a low ionic strength Tris buffer, and submitted for DNA quantitation (Zhang *et al*, 1997).

6.7. DNA quantitation

The fluorescence analysis using the Picogreen kit (Molecular Probes) was used to quantitate DNA. Absorbance was read from an SLM 4800C spectrofluorometer (SLM Instruments Inc. Urbana, IL). The sample DNA was then determined from the standard curves. A series of dilutions were done subsequently to adjust the concentration of DNA to five ng/μl with LOTE buffer (Zhang *et al*, 1997).

6.8. Primer-extension preamplification (PEP)

If the concentration of DNA was less than 100 ng total, a procedure called PEP was first done. PEP involves amplification of multiple sites of the genome using random primers and low stringency conditions and hence increases the amount of total DNA for microsatellite analysis. It was carried out in a 60 μl reaction volume containing 20 ng of the DNA sample, 900 mM of Tris-HCL of pH 8.3, 2 mM of dNTP where N is A, C, G and T, 400 nM of random 15-mers (Operon Techologies, SP 182-2, Poly N, 15 mer), and 1 μl of Taq DNA polymerase (GibcoBRL, 5U/μl). Two drops of mineral oil were added prior to the reaction. PEP using the automated thermal cycler (Omigene HBTR3CM, Hybaid Ltd) involved 1 cycle of pre-heat at 95 C^0 for 2 min, 50 cycles of 1) denaturation at 92 C^0 for 1 min, 2) annealing at 37 C^0 for 2 min, and 3), ramping from 37 C^0 to 55 C^0 at 10 sec/degree, polymerization at 55 C^0 for 4min.

6.9. Coding samples

All samples were coded in such a way that the analysis of LOH would be performed without the knowledge of the sample diagnosis.

6.10. End-Labeling

One more step before PCR was end-labeling of one of the primer pair. The reaction contained a 50μl mixture of PCR water 38μl, 10 × buffer for T4 polynucleotide kinase 5μl, 10 × BSA 1μl, one of the primer pair 1μl, T4 polynucleotide kinase 3μl, and [γ-^{32}P] ATP (20 μCi, Amersham) 2 μl. It was then run for 1 cycle at 37 C^0 for 60 min using the thermal cycler (Zhang *et al*, 1997).

6.11. PCR amplification

Microsatellite LOH analysis in this study was done on chromosome arms 3p, 4q, 8p, 9p, 11q, 13q and 17p. The pairs of ^{32}P end-labeled polymorphic probes (primer pairs, chromosome markers, Research Genetics - Huntsville, AL) that flank the area of tandem repeats in the chromosomal region of interest mapped to the following regions: 3p14.2 (*D3S1234, D3S1228, D3S1300*); 4q26 (*FABP2*); 4q31.1 (*D4S243*); 8p21.3 (*D8S261*); 8p23.3 (D8S262); 8p23.3 (*D8S264*); 9p21-22 (*IFNA*, *D9S171*, *D9S736*, *D9S1748, D9S1751*); 11q13.3 (*INT2*); 11q22.3 (*D11S1778*); 13q32 (*D13S170*); 13q14.3 (*D13S133*); 17p11.2 (*CHRNB1*) and 17p13.1 (*tp53* and *D17S786*). These markers are localized to regions

previously shown to be frequently lost in head and neck tumors (Lazar *et al*,1998; El-Naggar *et al*, 1998; Zhang *et al*, 1997; Maestro *et al*, 1996; Uzawa *et al*, 1996; Califano *et al*, 1996; Mao *et al*, 1996a; Emilion *et al*, 1996; Roz *et al*, 1996; El-Naggar *et al*, 1995; Ah-See *et al*,1994; Nawroz *et al*, 1994; Adamson *et al*, 1994; Wu *et al*, 1994). Some of the markers, like the regions 3p14 (instead of 3p21.3-23 and 3p24-25) and 9p21 (instead of 9p22-23), are preferentially chosen for analysis, because high frequencies of LOH at these regions have not only been reported in head and neck cancers but also have been shown to be associated with the risk of malignant transformation of oral premalignant lesions (Mao *et al,* 1996a).

PCR amplification using the thermal cycler was carried out in a 5 μl reaction volume containing 5 ng of genomic DNA, 1 ng of labeled primer, 10 ng of each unlabeled primer, 1.5 mM each of dATP, dGTP, dCTP, and dTTP, 0.5 units of Taq DNA polymerase (GIBCO, BRL), PCR buffer [16.6 mM ammonium sulfate, 67 mM Tris (pH8.8), 6.7 mM magnesium chloride, 10 mM (mercaptoethanol, 6.7 mM EDTA, and 0.9% dimethyl sulfoxide], and 2 drops of mineral oil. Amplification involved 1 cycle of pre-heat at 95C^0 for 2 min; 40 cycles of 1) denaturation at 95 C^0 for 30 sec, 2) annealing at 50-60 C^0 (depending on the primer used) for 60s, and 3) polymerization at 70 C^0 for 1 min; and 1 cycle of final polymerization at 70 C^0 for 5 min. The PCR products were then diluted 1:2 in loading buffer and separated on an 7% urea-formamide-polyacrylamide gels, and visualized by autoradiography. The films were then coded and scored for LOH (Zhang *et al,* 1997).

6.12. Scoring of LOH

For each case, two samples, the epithelial cells in the lesion and the connective tissue underneath (which serves as a control), were subjected to amplification at the same time. An

informative case will yield two alleles, one maternal and the other paternal, with electrophoretic migration dependent on the different sizes. Samples were scored by comparison of the intensity of the autoradiographic bands (which represent the PCR product) of the lesion with that of the normal connective tissue control. Allelic imbalance detected as loss or marked reduction (>50%) of one of these allelic bands is termed LOH. A case is non-informative if both paternal and maternal alleles are of the same size. In this situation, an alternative information probe was replaced.

All samples showing LOH would be subjected to repeat analysis after a second independent amplification and re-scored whenever the quantity of DNA was sufficient.

7. RESULTS

7.1. Frequency of allelic loss

LOH was present in 68 of 116 (59%) pre-malignant lesions studied, occurring more frequently among dysplastic (55 of 77, 71%) than hyperplastic (13 of 39, 33%) lesions ($P < 0.001$). LOH frequencies were dramatically elevated in lesions that later progressed to cancer (Table 4). All progressing lesions (both hyperplastic and dysplastic) showed LOH at one or more of the 19 microsatellite loci tested. LOH was detected in only 21% of the non-progressing hyperplasias and 59% of dysplasias.

Multiple chromosomal arm loss was characteristic of progressing lesions (50% of hyperplasia and 91% of dysplasia, see Table 4). It was absent in non-progressing hyperplasia and occurred in only 31% of the non-progressing dysplasias.

Table 4. Accumulation of allelic loss in progressing and non-progressing lesions

	Hyperplasia			**Low-grade dysplasia**		
	Without progression	With progression	P	Without progression	With progression	P
# of lesions	33	6		54	23	
# with LOH[a]	7 (21)	6 (100)	0.001	32 (59)	23 (100)	0.0001
>1 arm lost	0	3 (50)	0.002	17 (31)	21 (91)	<0.0001
>2 arms lost	0	3 (50)	0.002	11 (20)	13 (57)	0.003

[a] A total of 7 chromosomal loci were tested. Values in parentheses are percentages

7.2. Pattern of allelic loss

The most common losses for both progressing and non-progressing cases were on 3p and 9p with a higher frequency in the progressing cases (Table 5). Among non-progressing cases, 4 of 30 (13%) hyperplasias and 13 of 53 (25%) dysplasias had a loss at 3p. LOH at 9p was rare in non-progressing hyperplasias (3% of cases), but present in 24 of 52 (46%) dysplasias. In contrast, 67% of the progressing hyperplasias and 64% dysplasias showed LOH at 3p; 50% of the progressing hyperplasias and 83% dysplasias showed LOH at 9p.

The frequency of loss at other arms (4q, 8p, 11q, 13q, 17p) was low for non-progressing cases. Only 2 of 33 hyperplasias (6%) had loss on any of these arms (1 at 11q, 1 at 13q). Nineteen of 54 (35%) of non-progressing dysplasias had loss on these arms, most frequently at 17p (20% of cases) and 8p (15%) followed by 11q (12%), 4q (8%), and 13q (4%).

Further increases in LOH frequencies at 4q, 8p, 11q, 13q and 17p occurred in lesions that progressed to tumors. For dysplasias, this increase was significant for 8p, 11q and 13q, with the increase for 4q approaching significance ($P = 0.057$). There was also a doubling in the frequency of LOH on 17p (from 20% to 41% of cases), although this increase was not significant ($P = 0.087$). For hyperplasias, increases were significant in comparisons of progressing versus non-progressing lesions for 4q, 8p, and 17p, with 11q approaching significance ($P = 0.062$).

Table 5 **Patterns of allelic loss in progressing and non-progressing lesions**

	Hyperplasia			Low-grade dysplasia		
Arm	Without progression	With progression	P	Without progression	With progression	P
3p	4/30 (13) [a]	4/6 (67)	**0.014** [b]	13/53 (25)	14/22 (64)	**0.003**
9p	1/32 (3)	3/6 (50)	**0.009**	24/52 (46)	19/23 (83)	**0.005**
4q	0/31 (0)	2/6 (33)	**0.023**	4/48 (8)	6/21 (29)	0.057
8p	0/31 (0)	2/6 (33)	**0.023**	8/51 (15)	11/21 (52)	**0.003**
11q	1/31 (3)	3/6 (33)	0.062	6/52 (12)	9/23 (39)	**0.011**
13q	1/32 (3)	0/4 (0)	1	2/53 (4)	7/21 (33)	**0.002**
17p	0/33 (0)	2/6 (33)	**0.020**	11/54 (20)	9/22 (41)	0.087
3p &/or 9p	*5/29 (17)*	*6/6 (100)*	***0.004***	*30/54 (56)*	*22/23 (96)*	***0.004***
3p &/or 9p plus any other arm	*0/32 (0)*	*3/6 (50)*	***0.002***	*15/54 (28)*	*18/23 (78)*	***0.0001***

[a] Loss/informative cases (% loss)

[b] Bold means $p < 0.05$, was considered significant.

7.3. Progression risk

Specific LOH patterns in premalignant lesions were examined for association with disease progression by using the Kaplan-Meier method (Armitage *et al,* 1987). Almost all the progressing lesions (28 of 29, 97%) had LOH on 3p &/or 9p. Time-to-progression curves (see table 6 in appendix of time between initial biopsy and current date or the date on which a lesion has progressed to SCC, with time of first biopsy set at 0) were plotted as a function of LOH at 9p (Fig. 4A), 3p (Fig. 4B), or a combination of 3p &/or 9p (Fig. 4C). All were significant. A further comparison was made of cases with loss on these 2 arms in the presence and absence of LOH at any of the other 5 chromosomes (4q, 8p, 11q, 13q and 17p; Fig.4D). A significant difference was again observed. Finally, we separately compared time-to-progression for cases in which 3p &/or 9p LOH was restricted to these 2 arms alone with additional losses on each of the chromosome arms (Fig.4E – 4I). Significant *P* values were observed for combinations that included 8p, 11q or 13q.

Additional analyses included an assessment of relative risk of progression for each of the LOH patterns presented and a determination of the proportion of cases without progression at 5 years follow-up. These results are tabulated in Table 7 with an assessment of their significance respectively.

Figure 4. Probability of having no progression to cancer, according to LOH pattern

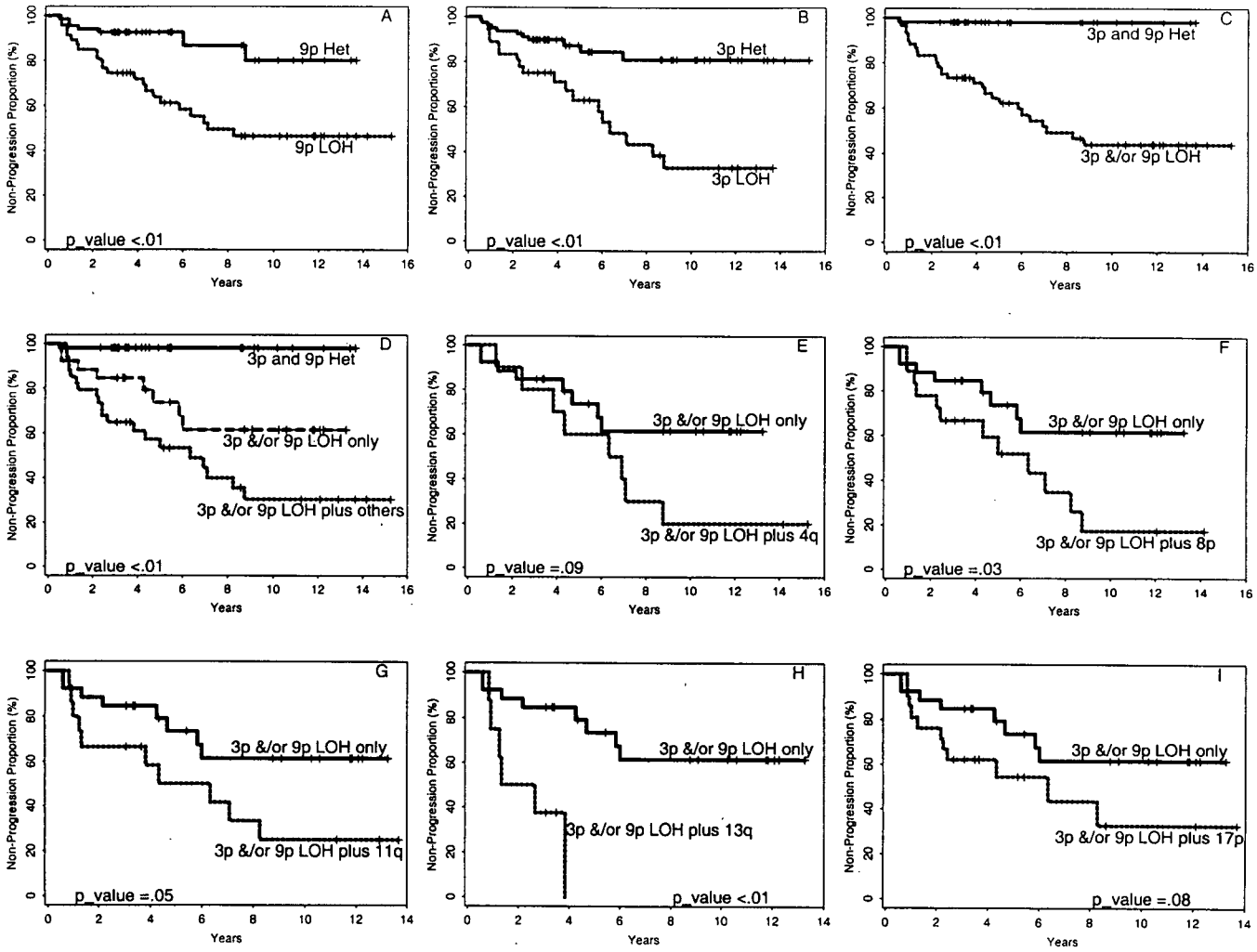

A, progression as a function of LOH at 9p (No LOH = 69; LOH = 47). **B**, progression as a function of LOH at 3p (No LOH = 80; LOH = 36). **C**, progression as a function of LOH at 3p &/or 9p (No LOH = 56, LOH = 60). **D**, progression as a function of LOH at 3p &/or 9p when this loss occurred in the absence or presence of LOH at any other arm (No additional arms lost = 26, LOH on at least 1 of the following arms: 4q, 8p, 11q, 13q or 17p = 34). **E, F, G, H,** and **I**, progression as a function of LOH at 3p &/or 9p when this loss occurred with no additional arms lost (n = 26) or with LOH at 4q (n = 10), 8p (n = 18), 11q (n = 15), 13q (n = 8) or 17p (n = 21) respectively.

Table 7. Probability of lesions not progressing to cancer after 5 years follow-up

LOH pattern	# of cases	Proportion (%) of non-progressing cases (95% CI)	RR (95% CI)
No LOH	48	100	-
9p*[1]:			
9p Het	69	93 (87-99)	1.0
9p LOH	47	61 (48-78)	3.97 (1.68-9.15)
3p*[2]:			
3p Het	80	85 (76-95)	1.0
3p LOH	36	63 (48-83)	3.74 (1.76-7.93)
3p &/or 9p*[3]:			
3p &/or 9p Het[a]	56	98 (95-100)	1.0
All cases with 3p &/or 9p LOH	60	63 (50-77)	24.1 (3.3-176)
3p &/or 9p LOH (but no other arms)	26	74 (57-95)	3.75 (1.32-10.7)
3p &/or 9p LOH (+ LOH at any other arm)	34	53 (38-74)	33.4 (4.48-249)
3p &/or 9p + others*[4]:			
3p &/or 9p LOH (but no other arms)	26	74 (57-95)	1.0
3p &/or 9p plus 4q LOH	10	60 (36-99)	2.3 (0.86-6.16)
3p &/or 9p plus 8p LOH	18	52 (32-84)	2.59 (1.05-6.37)
3p &/or 9p plus 11q LOH	15	50 (29-86)	2.49 (0.98-6.31)
3p &/or 9p plus 13q LOH	8	0[b]	7.08 (1.93-25.9)
3p &/or 9p plus 17p LOH	21	54 (35-83)	2.2 (0.18-5.5)

[a]Includes 8 cases with LOH at other arms
[b]Calculation does not include 2 non-progressing cases that have less than 5 years follow-up
*[1]The RR estimates the risk of 9p LOH group relative to group of 9pHet.
*[2]The RR estimates the risk of 3p LOH group relative to group of 3pHet.
*[3]The RR estimates the risk of each group relative to group of 3p&/or 9p Het
*[4]The RR estimates the risk of each group relative to group of 3p&/or 9p LOH (but no other arm loss).

7.4. Comparison of LOH pattern in matching premalignant and malignant lesions

In the Table 8, a comparison was made of the regions of loss in biopsy pairs of progressing cases. Twenty-five of 29 progressing cases had later CIS/SCC biopsies available for LOH analysis. In 17 cases (68%), allelic losses in the premalignant lesions (upper versus lower allele) were found in the later lesion (see Fig 5. b), although 14 of these cases showed additional losses on other chromosome arms. The remaining 8 cases showed an alteration in the pattern of loss in the tumor for some of the loci that had LOH in the early biopsy.

Table 8: Comparisons of LOH patterns in initial biopsies with that seen in CIS/SCC that later developed at the same anatomical site

	# of cases	Case ID #
Cases in which later biopsy was available for analysis	25	
Those with same LOH pattern in both biopsies	3/25 (12%)	#281 (6 losses), #470 (3 losses); #365 (1 loss)
Those with LOH in first biopsy also present in later biopsy, but with additional losses in the later lesions in the following arms:	14/25 (56%)	#385, #405, #416, #271, #293, #399, #185, #377, #245, #286, #464, #121, #223, #460
3p	4/14 (29%)	#405, #121, #399, #185
9p	1/14 (7%)	#416
17p	3/14 (21%)	#385, #405, #223
4q	5/14 (36%)	#385, #271, #293, #245, #286
8p	8/14 (57%)	#405, #385, #223, #293, #185, #377, #245, #460
11q	6/14 (43%)	#385, #405, #416, #185, #286, #464
13q	3/14 (21%)	#245, #377, #121
Different LOH patterns	8/25 (32%)	#173, #446, #472, #401, #95, #406, #122, #473
Later biopsy not available	4	#471, #363, #197, #79

Figure 5. LOH analysis of 2 patients (*a, b*)

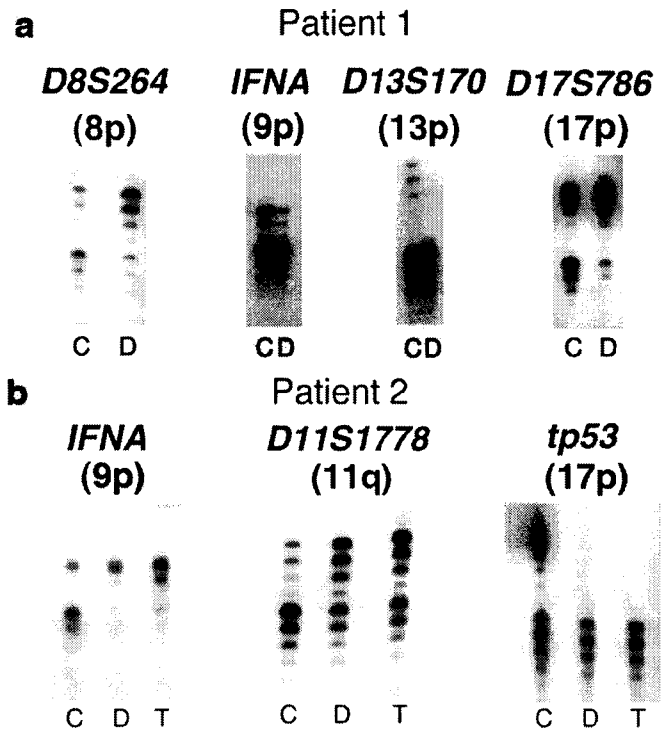

DNA was isolated from control stroma (C), dysplasia (D) or tumor (T) microdissected from lesion biopsies. Microsatellite markers, the chromosomal arm being assayed and patient numbers are indicated above each block. a: A rare mild dysplasia with multiple allelic loss: loss of lower allele at *D8S264;* upper allele at *IFNA;* upper allele at D*13S170*; and lower allele at *D17S786. b*: Patient with a mild dysplasia (D) that later progressed to a SCC (T). The mild dysplasia shows the same pattern of multiple allelic loss as the tumor: loss of the lower allele at *IFNA* and *D11S1778*; and upper allele at *tp53*

7.5. Clinical history of the lesions.

There was no significant difference between the progressing low-grade dysplasias and those without a history of progressing in terms of *gender distribution* (56% male in progressing cases vs. 57% of those without a history), *age distribution* (mean age 58 years in progressing cases vs 55 in those without a history), *site distribution, and smoking history* (of those with known habits, 78% of progressing cases vs. 85% of those without a history were smokers). However, on average non-progressing cases were monitored for over twice the duration (96 versus 37 months) to ensure that progression did not occur. (Table 9).

Table 9 Characteristics of patients with dysplasia

Features	Non-progressing	Progressing	P
Age (mean, years)	55	58	0.416
Sex (% male)	57	56	1
% with smoking history	85	78	0.170
Follow-up (mean, months)	96	37	0.0001

A history of recurrence was found for 2 of 6 progressive hyperplasias (compared with none of the 33 cases without a history of progression, $p = 0.0192$) and for 13 of 25 (52%) progressing low-grade dysplasia (compared to 4 of 55, or 7%, of dysplasias without a history of progression, $p < 0.0001$, Table 10 and 11). Furthermore, despite the fact that low-grade dysplasias in British Columbia are generally treated conservatively, 6 of the 25 progressive dysplasias had a further wide removal of their lesion (Table 10) probably because of their recurrence and progression.

Table 10 LOH frequencies and clinical history in progressing lesions

Id #	Age/ sex	Site	Diagnosis	Time (mo.)[a]	Chromosomal arms showing LOH[b]
405	43/M	Tongue	Hyperplasia	0	9p
			SCC	7	9p, **3p, 17p, 8p, 11q**
385	66/F	Tongue	Hyperplasia	0	3p
			SCC	16	3p, **17p, 11q, 8p, 4q**
406	68/M	Retromolar	Hyperplasia	0	9p, 17p, **11q**
			Hyperplasia	8	NA
			SCC	12	9p, 17p, **3p, 4q**
416	57/M	Retromolar	Hyperplasia	0	3p
			SCC	72	3p, **9p, 11q**
471	70/M	Gum	Hyperplasia	0	3p, 4q, 8p
			CIS	105	NA
363	70/F	Tongue	Hyperplasia	0	3p, 9p, 17p, 4q, 8p, 11q
			Hyperplasia	8	NA
			Moderate dysplasia	31	NA
			Hyperplasia	46	NA
			SCC	76	NA
173	74/M	Tongue	Mild dysplasia	0	3p, 9p, 8p, 11q, **13q**
			Mild dysplasia		NA
			SCC	16	3p, 9p, 8p, 11q, **17p**
122	56/F	Tongue	Mild dysplasia	0	3p, 9p, 8p, **11q, 17p**
			Mild dysplasia	15	NA[c]
			Severe dysplasia, removed with wide margin	32	NA
			SCC	99	*3p*, 9p, 8p, **4q, 13q**

223	29/ M	Tongue	Mild dysplasia,	0	9p
			Persistently recurring leukoplakia treated by multiple wide electrocauterization	NA	NA
			SCC	51	9p, **17p, 8p**
271	69/F	Floor of mouth	Mild dysplasia	0	3p, 9p, 17p, 11q, 13q
			Hyperplasia	4	NA
			CIS	10	3p, 9p, 17p, 11q, 13q, **4q**
293	47/ M	Tongue	Mild dysplasia	0	3p, 9p, 17p
			SCC	26	3p, 9p, 17p, **4q, 8p**
399	44/F	Tongue	Mild dysplasia	0	9p,17p
			Clinical recurrence and treated with bleomycin	8	NA
			SCC	10	9p, 17p, **3p**
365	80/F	Gum	Mild dysplasia	0	NA
			Mild dysplasia	11	9p
			Mild dysplasia	23	9p
			SCC (probably from VC)	26	9p
446	47/F	Floor of mouth	Mild dysplasia	0	8p, **9p**
			SCC (very inflamed)	60	8p
472	60/ M	Tongue	Mild dysplasia	0	3p, 9p, 4q, 8p, 11q
			Hyperplasia	2	NA
			SCC	85	3p, *9p*, 4q, 8p, 11q

185	50/ M	Tongue	Moderate dysplasia	0	9p, 4q
			Clinical recurrence of leukoplakia and all grossly visible lesion removed with margin (no bx submitted)	48	NA
			SCC	83	9p, 4q, **3p, 8p, 11q**
197	39/ M	Tongue	Moderate dysplasia	0	3p, 9p
			Moderate dysplasia	6	NA
			SCC	7	NA
377	52/ M	Cheek	Moderate dysplasia	0	3p, 4q
			Moderate dysplasia	17	NA
			Moderate dysplasia followed by wide laser excision	35	NA
			SCC	70	3p, 4q, **8p, 13q**
473	73/ M	Gum	Moderate dysplasia	0	3p, 8p, 11q
			Moderate dysplasia removed with wide margin	5	3p, 8p, 11q, **9p**
			SCC	11	8p, 11q, 9p, *3p*, **13q**
245	70/F	Cheek	Moderate dysplasia	0	3p, 9p
			SCC	56	3p, 9p, **8p, 4q, 13q**
281	53/ M	Tongue	Moderate dysplasia	0	3p, 9p, 17p, 4q, 8p, 11q
			SCC	52	3p, 9p, 17p, 4q, 8p, 11q

401	42/ M	Tongue	Moderate dysplasia	0	9p, 17p, 4q, 11q, 13q, **8p**,
			SCC	15	9p, 17p, 4q, 11q, 13q
286	65/ M	Cheek	Moderate dysplasia*	0	3p, 17p, 8p, 13q
			CIS	11	3p, 17p, 8p, 13q, **9p, 4q, 11q**
460	46/ M	Floor of mouth	Moderate dysplasia	0	3p, 9p, 4q, 11q, 13q
			Recurrence of leukoplakia but no further biopsy or treatment were given	NA	NA
			SCC	46	3p, 9p, 4q, 11q, 13q, **8p**
79	60/F	Tongue	Moderate dysplasia	0	3p, 9p ,17p, 4q
			CIS	29	NA
464	71/F	Tongue	Moderate dysplasia	0	3p, 17p, 8p
			SCC	27	3p, 17p, 8p, **11q**
121	80/F	Gum	Moderate dysplasia	0	9p, 8p
			Moderate dysplasia	4	NA
			SCC	29	9p, 8p, **3p, 13q**
470	46/ M	Lower lip	Moderate dysplasia	0	8p, 11q, 13q
			Moderate dysplasia	5	NA
			CIS	6	8p, 11q, 13q
95	76/F	Tongue	Moderate dysplasia	0	9p, **13q**
			CIS	32	9p

[a] Time between biopsies, with time of first biopsy set at 0.

[b] Chromosome arms that are bold are those showing LOH in 1 biopsy but not in the other; italicized arms have different alleles lost in consecutive biopsies

*Note: This patient had history of cancer in multiple organs prior to buccal mucosa dysplasia: (1) 11 years ago: cervical lymphoma treated with chemotherapy and prednisolone; (2) 6 years ago: Bladder

tumor treated with surgery; (3) 3 years ago: lung SCC treated with surgery; and (4) 1 year ago: prostate cancer treated with surgery and estrogen

Table 11 Allelic loss in recurrent premalignant lesions without a history of progression

Id #	Age/ sex	Site	Diagnosis	Time (mo.)*	Chromosomal arms showing LOH
26	65/M	Left anterior gingiva	Moderate dysplasia	0	No LOH
			Mild dysplasia	10	NA
88	68/F	Right floor of mouth	Mild dysplasia	0	3p, 9p, 17p, 8p, 13q, 14q, 8q
			Mild to moderate dysplasia	9	NA
			Mild dysplasia	15	NA
277	47/?	Floor of mouth	Hyperplasia	0	17p, 4q (non-informative for 3p)
			Mild dysplasia	13	
189	43/F	Soft palate	Moderate dysplasia	0	9p, 4q, 8p
			Moderate dysplasia	32	NA

*Time between biopsies, with time of first biopsy set at 0.

8. DISCUSSION

Over the last decade, genetic analysis of tumors has led to significant breakthroughs in our understanding of alterations in tissues that underlie tumorigenesis. One of the current research challenges is to begin to apply such technology to the earliest clinical lesions, both to improve our understanding of the genetic alterations that underlie early cancer development and, hopefully, to provide potential indicators of risk for such lesions.

8.1. High frequency of allelic loss characterized dysplastic lesions

This study showed that loss of regions of chromosomes containing presumptive tumor suppressor genes occurred early during oral carcinogenesis. A significant percentage of low-grade oral dysplasias showed allelic loss suggesting that loss of these regions may play an important role in the evolution and growth advantage of these premalignant clones.

The presence of histological evidence of dysplasia is presently the gold standard for judging malignant potential of oral premalignant lesions. This study showed that advent of dysplasia was accompanied by significantly increased frequency of LOH when compared to hyperplasias. When the patterns of loss among hyperplastic and low-grade dysplastic lesions were compared (Table 4), LOH was found in only 13 of 39 (33%) cases showing loss on any of the 7 arms studied in hyperplastic lesions. In contrast, such loss occurred in the majority of dysplastic lesions, 55 of 77 (71%) samples ($p < 0.001$). This increase in allelic loss in dysplastic lesions also was evident when the percentage of cases showing multiple arm loss was determined. While multiple losses among hyperplastic lesions was limited to 3 of 39 (7.7%) cases, 38 of 77 (49%) of low-grade dysplasias showed > 1 arm lost ($p<0.0001$). Our

results are consistent with Mao's: Lesions with dysplastic alteration had a higher rate of microsatellite alterations (3p14 and 9p21), 50% *vs* 31% (P = 0.08).

It is well accepted that presence of dysplasia has been associated with an increased risk of malignant transformation (van der Waal *et al,* 1997). The fact that the frequency of LOH was associated with the presence of dysplasia would suggest a cancer predictive value for LOH and also suggest that molecular changes may underline the dysplastic phenotypes.

8.2 Increased frequency of allelic loss in progressing lesions

Linkage of specific patterns of genetic alteration to disease progression is often limited by the difficulty of obtaining clinical specimens from the same lesion over time. In this study, microdissected early oral premalignant lesions from 116 patients with or without a history of progression into CIS or invasive SCC were analyzed for LOH at on 7 chromosomes in order to identify genetic differences between progressing and non-progressing lesions, and to identify genetic profiles that have predictive value for early premalignant lesions.

One of the more striking observations made in this study is markedly increased frequency of allelic loss in progressing lesions as compared to the non-progressing lesions. All such progressing lesions, both hyperplasias and dysplasias, showed loss on at least 1 arm. In contrast, hyperplasias and low-grade dysplasias without a history of progression had loss in 21% and 59% of cases respectively (Table 4). Furthermore, multiple arm loss (>1 arms lost) was absent in hyperplasias without a history of progression but present in 3 of 6 progressing hyperplasias. Also, the majority of progressing dysplasias had >1 arms lost (91% of cases compared to 31% of dysplasias without a history of progression) with 57% of cases having loss at >2 arms (compared with 20% of dysplasias without a history of progression).

These data support the hypothesis that progressing early lesions and those without a history of progression can appear morphologically or phenotypically similar, yet differ significantly at the genetic level. Furthermore, the data suggest that assaying hyperplasias and low-grade dysplasias for LOH frequencies might be of clinical use in differentiating between low-risk and high-risk lesions.

8.3. The pattern of allelic loss characterized progressing lesions

The earliest loss was at 3p and occurred before the advent of dysplasia. Even hyperplasia without a history of progression demonstrated 3p loss in 13% of the cases. This may suggest that TSGs at 3p, such as *FHIT*, may play an important role in early oral carcinogenesis.

The most common loss in low-grade dysplasia was at 9p (46%), supporting the hypothesis that p16 gene dysfunction plays important role in early oral carcinogenesis. The fact that the most common losses for both sets of cases were on 3p and 9p was consistent with results from previous studies that have shown that LOH at 3p14 and 9p21 (the regions studied in this paper) are frequent occurrences in oral premalignant lesions and likely to occur early in oral carcinogenesis (Zhang *et al,* 1996; Califano *et al,*1996; Mao *et al,* 1996a; Roz *et al,* 1996).

The loss at 3p &/or 9p was not only the earliest and most common event during oral carcinogenesis, it was also significantly higher in the progressing lesions (Table 5), with this trend apparent when 3p and 9p are considered separately, even more apparent when they are considered together. Virtually all progressing lesions (22/23, 96% in dysplasia and 6/6, 100% in hyperplasia) had loss on 3p &/or 9p, compared to 5 of 29 (17%) hyperplasias without a

history of progression and 30 of 54 (56%) of low-grade dysplasias without a history of progression. These data suggest that LOH at 3p &/or 9p is not simply one of those random genetic alterations but rather a prerequisite for progression of oral premalignant lesions.

From a clinical point of view, this would suggest that analysis of LOH at 3p and 9p may be used as an important initial screen for the malignant risk of leukoplakia. However, because of the high frequency of LOH at 3p and 9p in early lesions without a history of progression, especially in dysplasia (56%), these markers may not be the best markers for prediction of prognosis, at least not by themselves.

LOH on the other 5 chromosome arms (4q, 8p, 11q, 13q and 17p) occurred rarely or at low frequency in non-progressing lesions. In contrast, a significant number of progressing lesions including both hyperplasia and low-grade dysplasia showed LOH at these chromosome arms. LOH in these chromosome arms have also been reported to occur in oral premalignant lesions; however, such losses (especially for chromosome arm 4q, 8p, 11q and 13q) were generally seen in high-grade preinvasive lesions (severe dysplasia/CIS) or SCC (Califano *et al*, 1996; unpublished data from this lab). This would suggest that LOHs on these chromosome arms are relatively 'late' events in the preinvasive stages and should be rare or absent in hyperplastic or low-grade dysplastic lesions. This was indeed the case for the low-grade dysplasias without a history of progression in this study. In contrast, progressing low-grade dysplasias had increased frequencies of loss for these chromosome arms. Progressing low-grade dysplasias had significant increases for 8p ($p = 0.003$), 11q ($p = 0.01$) and 13q ($p = 0.002$) with the increase for 4q approaching significance ($p = 0.057$). There was also a doubling in the frequency of LOH on 17p (from 20% to 41% of cases); although this increase was not significant or only marginally significant.

The high frequency of LOH on these arms in high-risk advanced oral preinvasive lesions and in lesions with proven progression would suggest LOH on these arms indicates a higher cancer risk (than those with only 3p &/or 9p). In fact, when the percentage of cases that showed a combination of 3p &/or 9p loss with additional losses at any of the remaining arms was determined, this occurrence was shown to be present in 0% of hyperplasias without a history of progression compared to 50% of progressing hyperplasias and in 28% of dysplasias without a history of progression and 78% of progressing dysplasias, both are significantly different (Table 5). These results would suggest that additional losses on these chromosome arms indicate cancer risk.

8.4. LOH as markers to predict cancer risk - further statistic analysis

The present study showed that progressing and non-progressing lesions had significantly different LOH profiles. How could we use the study data for the evaluation of the cancer risk of oral premalignant lesions? Since loss at 3p &/or 9p was the most common and earliest event and seemed to a prerequisite for progression, it may be used as an initial screening for assessing cancer risk of oral premalignancies. If LOH at 3p &/or 9p had been used as an initial screening for our study set, without knowledge of LOH at other arms, those cases with 3p &/or 9p LOH (with or without LOH at other arms) would have had a 24-fold increase in the relative risk of cancer progression as compared to those without LOH at either 3p or 9p (Fig.4C, Table 7). This is consistent with the results of Mao *et al,* (1996a) who found LOH at 3p &/or 9p predicts cancer risk of oral leukoplakias. However, since there was a high frequency of allelic loss on these arms in non-progressors and the relative cancer risk for those with LOH at 3p &/or 9p but no other arms was only increased by 3.8-fold in the

relative risk of cancer progression as compared to those without LOH at either 3p &/or 9p (Fig.4D, Table 7), additional markers are essential for better prediction of prognosis.

The study results suggest that loss at any of the other 5 chromosomes (4q, 8p, 11q, 13q, and 17p) in addition to LOH at 3p &/or 9p seem to provide a better predictive value. Those cases with such losses had a 33-fold increased risk of progressing to cancer compared to cases that retained both of these arms (Fig 4D, Table 7). Furthermore, time-to-progression curves showed that lesions that had 3p &/or 9p loss with additional loss on at least one of the indicated arms had a significantly shorter progression time than those with 3p &/or 9p loss only ($p<0.01$, Fig. 4D).

To determine which of the additional losses (on 4q, 8p, 11q, 13q or 17p) would most significantly increase progression risk, the study separately compared those cases with 3p &/or 9p loss alone against those cases with 3p &/or 9p loss plus each of the additional losses (Figure 4E to I). A significantly shorter time-to-progression was observed when either 8p ($p\leq0.03$, by the logrank test), 11q ($p\leq0.05$) or 13q ($p<0.01$), LOH was present in addition to 3p &/or 9p LOH. Comparisons with 4q ($P = 0.09$) or 17p ($P = 0.08$) were not statistically significant, although a trend was observed.

For each premalignant LOH pattern, the probability of having no subsequent progression is summarized in Table 7. Forty to sixty percent of individuals with additional losses at 4q, 8p, 11q or 17p developed cancer within 5 years, corresponding to a 2.2-2.6-fold increase in relative risk of cancer progression as compared to those with LOH at 3p&/or 9p only. Moreover, cases with additional 13q loss had a 7-fold increase in risk of progression. Six of the 8 cases with loss on this arm had 5 years of follow-up and all showed progression within this timeframe.

In conclusion, although prospective studies involving large numbers of subjects over time are necessary to fully understand the relation between chromosomal loss and tumorigenesis, the study data do suggest that LOH patterns will facilitate the prediction of the malignant potential of low-grade premalignancies.

Can we use this information clinically?

In addition to being used for deletion mapping of tumor suppressor genes, the LOH assay has begun to be used to assist pathologists in screening for patients with premalignant lesions and cancer. Mao (1996c) analyzed LOH in urothelial cells obtained from urine sediments of cancer patients and correctly identified 95% of the patients with cancer. There have also been prognostic studies that attempt to correlate the degree of LOH and survival rate (Partridge *et al,* 1996; Scholnick *et al,* 1996; Nawroz *et al,* 1996; Field *et al* 1995). For example, Nawroz (1996) found that patients with LOH at any of their 12 markers all had advanced disease (stage III or IV), most had nodal metastases, and half of them died of disease. Recently, Califano (1999) tried to use detection of genetic alterations for molecular identification of the site of origin of the primary tumor; Harda (1999) and Ogawara (1998) both found LOH on 13q was significantly correlated with lymph node metastasis in oral SCC and HNSCC; Partridge (1999c) found that patients with allelic imbalance at 3p24-26, 3p13 and 9p21 have an approximately 25 times increase in their mortality rate relative to patients retaining heterozygosity at these loci. She suggested that it would be possible to develop a molecular staging system which will be a better predictor of outcome than conventional clinicopathological features, as the molecular events represent fundamental biological characteristics of each tumour; Matsuura (1998) found LOH of chromosome 9p21 and 7p31 is correlated with high incidence of recurrent in HNSCC. Finally, Mao (1998) has suggested that clinical and histologic assessments of the response to chemporeventive agents may be

insufficient to determine their efficacy and that critical genetic alterations could be used as independent biomarkers to augment the ability to evaluate the efficacy of such agents.

All these studies positively support our inquiry.

Our data suggest that LOH at 3p &/or 9p would place the patient into an at risk category since nearly all progressing cases in our cohort showed such alteration. Their relative risk increases with additional loss on other arms. Although additional losses on any of these arms is an indicator of probable progression, the loss of 13q might signal the need for active intervention with either traditional or novel forms of therapy such as chemoprevention.

8.5. Most progressed lesions may be derived by clonal outgrowth from the earlier lesions.

Comparing the LOH pattern of premalignant and malignant in patients that later progressed to CIS or SCC, we have found that most of LOH patterns in the premalignant lesions were found in their matched later lesions, although 14 of these cases showed additional losses on other chromosome arms and the remaining 8 cases showed an alteration in the pattern of loss in the tumor for some of loci that had LOH in the early biopsy (Fig.5 b and Table 8). However, in 3 of the latter cases this difference was restricted to a single arm out of 5 or 6 arms lost. For example, in case #173 the early lesion contained a LOH at 13q that was not found in the later lesion; however, the pair showed loss of the same alleles on 3p, 9p, 8p and 11q. Our analysis of lesions with progressed cases suggests that for most progressing lesions, the later cancer was derived by clonal outgrowth from the earlier lesions. In other words, the later cancer progressed from the early lesion.

8.6. Does evidernce of recurrence serve as a further indicator of cancer risk in premalignant lesions?

We obtained some clinical information for our subjects by tracking recurrent lesions as they appeared in our database and by following the case histories of treatment in hospital charts. With the information available, the data showed a significantly higher number of recurrences among progressing lesions (61% of progressing dysplasias vs. 7% dysplasias without a history of progression) (Table 10 and 11). Although there are some studies that correlated LOH and recurrence in head and neck cancer (Matsuura *et al,* 1998; Lydiatt *et al,* 1994 and 1998), no study showed the relationship between recurrence and cancer risk in premalignant lesions.

There are at least two possible explanations for our results: 1) the recurrence resulted from failure to totally remove these lesions and this failure was more prevalent among progressing cases; and 2) the recurrence reflected a more aggressive lesion with an elevated rate of genetic change.

The study does suggest that a large percentage of progressing lesions were not totally removed. In 17 of 25 (68%) progressing lesions, loci lost in the early lesions showed the same pattern of loss (upper versus lower allele) in the later lesion, suggesting that they were derived by clonal outgrowth from the earlier lesions. Interestingly, many of these lesions were considered to be totally eliminated using histological and clinical criteria. However, there is no evidence that treatment was less aggressive among progressing cases compared with those without a history of progression. In fact, in 6 of the 25 progressing dysplasias the decision was made to treat aggressively again, based on the recurrence and/or progression of the lesions (Table 10: #473, #122, #223, #399, #185 and #377). Despite wide removal of the

lesion or wide laser excision or multiple wide electrocauterization or treatment with bleomycin, the same site later still progressed into cancer.

Our data support the second probability that these progressing lesions were indeed more aggressive in nature, possibly due to the specific genetic alterations that they had undergone. The recurrence reflected a more aggressive lesion with an elevated rate of genetic change.

It is well known that many oral leukoplakias, which histologically consist of hyperplasia &/or dysplasia, will not progress into cancer even when left untreated. This would imply that incomplete removal is only important clinically when the premalignant lesion is a high-risk lesion (genetic profile more important). In a rare, long-term study, Banoczy (1977) followed 670 patients with oral leukoplakia for up to 30 years (average 10 years). The treatment for many of these lesions was described as 'removal of local irritants and conservative treatment'. A large percentage of these lesions either regressed (29.7%) or remained static (25.8%). It is possible that we did not see as many recurrent lesions without a history of progression as progressing lesions because the clones of genetically altered cells regressed or remained static in lesions without a history of progression, even if they were not totally removed during the incisional biopsy. The result that 3 of the 4 recurrent premalignant lesions without a history of progression had multiple losses (Table 11) supports the hypothesis that the recurrent lesions were biologically more aggressive and that this behavior was associated either directly or indirectly with the amount of genetic damage in the lesion. Moreover, whether or not the failure of these recurrent lesions to progress was a result of their complete removal or insufficient time for follow-up is still not clear although a significantly greater length of follow-up was observed for non-progressing lesions (progressing cases, 37

months *vs*. non-progressing, 96 months, P = 0.0001) (Table 9). We may pay more attention to the recurrent lesions clinically.

8.7. Summary

The results from this study suggest that LOH patterns will facilitate the prediction of the malignant potential of low-grade premalignancies. In this study, we have demonstrated the predictive value of allelic loss subsequent to 3p &/or 9p loss, especially with 13q loss which increases the relative risk in progression by 7 fold. We may more precisely predict the malignant potential of low-grade premalignancies if we combine LOH patterns with the predictive value of dysplasia and clinical attributes such as recurrence after treatment.

We are only beginning to understand the processes that control the malignant transformation of oral premalignancies. For example, despite the significant association between multiple LOH and cancer risk, the speed of the malignant transformation was not affected by the number of the LOH in a lesion (Table 10). Some premalignancies had a relatively low number of regions showing LOH and yet progressed into cancer rapidly while others, with numerous losses, seemed to 'sit' for a long time before SCC occurred. This suggests that other changes, either genetic or epigenetic, must control or influence the malignant transformation. Such changes could include not only allelic losses at other chromosomal regions but also mutations to proto-oncogenes and TSGs or even epigenetic changes such as DNA methylation or histone deacetylation (Bakin *et al,* 1999). Alternatively, the immune system or homeostatic regulation of premalignant cells by surrounding normal cells such as epithelial-mesenchymal interaction could also play a role in controlling outgrowth of such lesions.

Furthermore, the study also suggests that not all cells in the high-risk premalignancies were removed even though the margins appeared clinically and histologically clean. Previous studies have shown that the presence of genetically damaged cells at the margins of surgical resection of oral SCC could account for tumor recurrence, despite gross and histologically free surgical margins (Westra *et al,* 1998). The same principle might be applied to oral premalignant lesions. If so, the malignant transformation rate of oral premalignant lesions could be reduced significantly in the future if we guide our surgical margin not only by gross and histological criteria, but also by molecular markers, especially for those premalignant lesions designated as high-risk.

9. REFERENCES

1. Adamson R, Jones AS, Field JK: Loss of heterozygosity studies on chromosome 17 in head and neck cancer using microsatellite markers. Oncogene 1994, 9:2077-2082.
2. Ah-See K., Cooke T., Pickford I., Soutar D., and Balmain A. An allelotype of squamous carcinoma of the head and neck using microsatellite markers. Cancer Research, 54: 1617-21, 1994.
3. Alberts B., Bray D., Lewis J., Raff M., Roberts K., and Watson J. Molecular Biology of the cell (3rd Edition). Garland Publishing, Inc. New York & London. 1994
4. Armitage P and Berry G Statistical methods in medical research, Second Edition Blackwell Scientific Publications, 1987 Chapter 14, Survival Analysis, pp421-439
5. Bakin AV, Curran T: Role of DNA 5-methylcytosine transferase in cell transformation by fos. Science 1999, 283:387-390.
6. Banocy J: Follow-up studies in leukoplakia. J Max-fac Surg: 69-75, 1977
7. Boiocchi M: Chromosome 13q deletion mapping in head and neck squamous cell carcinomas: identification of two distinct regions of preferential loss. Cancer Res 1996, 56:1146-1150.
8. Bockmuhl, U., Schwendel, A., Dietel, M., and Petersen, I. Distinct patterns of chromosomal alterations in high- and low-grade head and neck squamous cell carcinomas. Cancer Research, 56: 5325-29, 1996.
9. Bouquot JE: The Pathology and Progression of Oral Premalignancy. Epithelial Dysplasia Symposium. 5th International Congress on Oral Cancer. Edited by Bouquot JE. Royal College of Physicians, London, United Kingdom, 1997.

10. Brennan JA and Mao L *et al* Molecular assessment of histopathological staging in squamous-cell carcinoma of the head and neck N Engl J Med 332:429-435, 1995

11. Brunette DM Critical thinking-understanding and evaluating dental research Edited by Patricia Bereck Weikersheimer. Quintessence Publishing Co, Inc 1996, p129.

12. Califano J, van der Riet P, Westra W, Nawroz H, Clayman G, Piatadosi, S, Corio R, Lee D, Greenberg B, Koch W, Sidransky D: Genetic progression model for head and neck cancer: Implications for field cancerization. Cancer Res 1996, 56:2488-2492

13. Califano, J., Westra WH., Koch, W., Meininger G, Reed A., Yip L., Boyle, JO, Lonardo, F and Sidransky D: Unknown primary head and neck SCC: Molecular identification of the site of origin J. Nati.Can Institute 91(7): 599-604, 1999

14. Dawson CD, Chang KW, Solt DB. MTS1 gene mutations in archival oral squamous cell carcinoma. J Oral Pathol Med., 25: 541-546, 1996.

15. Chap, T LE, Applied survival analysis John Wiley & Sons, Inc. 1997

16. Croce, C.M., Sozzi, G. and Huebner, K Role of FHIT in human cancer J Clin Oncol 17: 1618-1624, 1999

17. El-Naggar AK, Hurr K, Batsakis JG, Luna MA, Goepfert H, Huff V: Sequential loss of heterozygosity at microsatellite motifs in preinvasive and invasive head and neck squamous carcinoma. Cancer Res 1995, 55(12):2656-2659.

18. El-Naggar AK, Coombes MM, Batsakis JG, Hong WK, Goepfert H, Kagan J: Localization of chromosome 8p regions involved in early tumorigenesis of oral and laryngeal squamous carcinoma. Oncogene 1998, 16:2983-2987.

19. Emilion G, Langdon JD, Speight P, Partridge M: Frequent gene deletions in potentially malignant oral lesions. Brit J Cancer 1996, 73(6):809-813

20. Fearon, E. Human cancer syndromes: clues to the origin and nature of cancer. Science, 278: 1043-50, 1997.

21. Field, J., Kiaris, H., Risk, J., Tsiriyotis, C., Adamson, R., Zoumpourlis, V., Rowley, H., Taylor, K., Whittaker, J., Howard, P., Birne, J., Gosney, J., Woolgar, J., Vaughan, E., Spandidos, D., and Jones, A. Allelotype of squamous cell carcinoma of the head and neck: fractional allele loss correlates with survival. British Journal of Cancer, 72: 1180-8, 1995.

22. Gallo, O and Sardi., I. Multiple primary of the upper aerodigestive tract: is there a role for constitutional mutations in the p53 gene? Int. J. Cancer: 1999, 82:180-186.

23. Harada, H. and Tanaka, H et al. Lymph node metastasis is associated with allelic loss on chromosome 13q12-13 in esophageal squamous cell carcinoma. Cancer Research, 59:3724-3729, 1999.

24. Hu LF, Eiriksdottir G, Lebedeva T, Kholodniluk I, Alimov A, Chen F, Luo Y, Zabarovsky ER, Ingvarsson S, Klein G, Ernberg I. Loss of heterozygosity on chromosome arm 3p in nasopharyngeal carcinoma. Gene Chrom Cancer, 17: 118-126, 1996.

25. Ilyas, M & I.P.M. Tomlinson. Genetic pathways in colorectal cancer Histopathology 28: 389-399, 1996

26. Ishwad, C., Ferrell, R., Rossie, K., Appel, B., Johnson, J., Myers, E., Law, J., Srivastava, S., and Gollin, S. Loss of heterozygosity of the short arm of chromosomes 3 and 9 in oral cancer. International Journal of Cancer (Pred. Oncology), 69: 1-4, 1996.

27. Jares P and Nadal A *et al* Disregulation of *p16 MTS1/ CDK41* protein and mRNA expression is associated with gene alterations in squamous-cell carcinima of the larynx. Int. J. Cancer 81:705-711, 1999

28. Jiang W, Zhang Y-J, Kahn SM, Hollstein MC et al. Altered expression of the cyclin D1 and retinoblastoma genes in human esophageal cancer Proc. Natl Acad Sci USA 90: 9026-30,1993

29. Jordan RCK and Daley T Oral squamous cell carcinoma: new insights. Canadian Dental Association 63 (7) 517-525

30. King, RJB, Cancer biology. Addison Wesley Longman Limited, 1996

31. Lazar AD, Winter MR, Noguerira CP, Larson PS, Finnemore EM, Dolan RW, Fuleihan N, Chakravarti A, Zietman A, Rosenberg C: Loss of heterozygosity at 11q23 in squamous cell carcinoma of the head and neck is associated with recurrent disease. Clin Cancer Res 1998, 4:2787-2793.

32. Leis JF, Livingston DM. The tumor suppressor genes and their mechanisms of action. In Bishop JM, Weinberg RA ed, Molecular Oncology. Scientific Am., Inc. pp111-41, 1996.

33. Li X, Lee NK, Ye YW, Waber PG, Schweitzer C, Cheng QC, Nisen PD. Allelic loss at chromosomes 3p, 8p, 13q and 17p associated with poor prognosis in head and neck cancer. J Natl Cancer Inst., 86(20): 1524-1529, 1994.

34. Liggett WH and sidransky D Role of the p16 tumor suppressor gene in cancer Journal of Clinical Oncology 16(3)1197-1206, 1998

35. Lydiatt WM, Davidson BJ, Shah J, Schantz SP, Changanti RSK. The relationship of loss of heterozygosity to tobacco exposure and early recurrence in head and neck squamous cell carcinoma. Am J Surg, 168: 437-440, 1994.

36. Lydiatt, W., Davidson, B., Schantz, S., Caruana, S., and Chaganti, S. 9p21 deletion correlates with recurrence in head and neck cancer. Head and Neck, 20(2): 113-8, 1998.

37. Maestro, R., Gasparotto, D., Vukosavljevic, T., Barzan, L., Sulfaro, S., and Boiocchi, M. Three discrete regions of deletion at 3p in head and neck cancers. Cancer Research, 53: 5775-9, 1993.

38. Maestro R, Piccinin S, Doglioni C, Gasparotto D, Vukosavljevic T, Sulfaro S, Barzan L, Boiocchi M. Chromosome 13q deletion mapping in head and neck squamous cell carcinoma: identification of two distinct regions of preferential loss. Cancer Res., 56: 1146-1150, 1996.

39. Matsuura K and Shiga K *et al* Loss of Heterozygosity of Chromosome 9p21 and 7p31 is correlated with high incidence of recurrent Tumor in head and neck squamous cell carcinoma Anticancer Research 18:453-8, 1998

40. Matsuda H and Konishi N *et al* Alterations of p19/CDKN2, p53 and *ras* genes in oral squamous cell carcinomas and premalignant lesions. J Oral Pathol Med 25: 232-238, 1996

41. Merlo A and Herman JG *et al* 5' CpG island methylation is associated with transcriptional silencing of the tumour suppressor p16/CDKN2/MTS-1 in human cancers Nature Med 1:686-692, 1995

42. Mao, E., Oda, D., Haigh, W., and Beckman, A. Loss of the Adenomatous Polyposis Coli gene and human papillomavirus infection in oral carcinogenesis. Oral Oncology, European Journal of Cancer, 32B: 260-3, 1996.

43. Mao, L., Lee, J., Fan, Y., Ro, J., Batsakis, J., Lippman, S., Hittelman, W., and Hong, W. Frequent microsatellite alternations at chromosomes 9p21 and 3p14 in oral premalignant lesions and their value in cancer risk assessment. Nature Medicine, 2: 682-5, 1996a.

44. Mao L, Fan YH, Lotan R, Hong WK. Frequent abnormalities of FHIT, a candidate tumor suppressor gene, in head and neck cancer cell lines. Cancer Res., 56: 5128-5131, 1996b.

45. Mao, L and El-Naggar, AK et al Phenotype and Genotype of advanced premalignant head and neck lesions after chemopreventive therapy J. Nati. Can. Institute 90 (20): 1545-1551, 1998a

46. Mao L. Tumor suppressor genes: Does FHIT fit? J of the national cancer institute 90 (6) 412-414,1998b

47. Nakanishi, H and Wang, XL et al, Localization of a novel tumor suppressor gene loci on chromosome 9p21-22 in oral cancer Anticancer Research 19:29-34, 1999

48. Nawroz H, van der Riet P, Hruban RH, Koch W, Ruppert JM, Sidransky D: Allelotype of head and neck squamous cell carcinoma. Cancer Res 1994, 54(5):1152-1155.

49. Nowell PC. The clonal evolution of tumor cell populations. Science, 194: 23-28, 1976.

50. Ogawara K, Miyakawa A, Shiiba M, Uzawa K, Watanabe T, Wang XL, Sato T, Kubosawa H, Kondo Y, Tanzawa H. Allelic loss of chromosome 13q14.3 in human oral cancer: correlation with lymph node metastasis. Int J Cancer: 79: 312-317, 1998.

51. Ohta, M., Inoue, H., Cotticelli, M., Kastury, K., Baffa, R., Palazzo, J., Siprashvili, Z., Mori, M., McCue, P., Druck, T., Croce, C., and Heubner, K. The FHIT gene, spanning the chromosome 3p14.2 fragile site and renal carcinoma-associated t(3;8) breakpoint, is abnormal in digestive tract cancers. Cell, 84: 587-97, 1996.

52. Papadimitrakopoulou, V., Izzo, J., Lippman, S., Lee, J., Fan, Y., Clayman, G., Ro, J., Hittelman, W., Lotan, R., Hong, W., and Mao, L. Frequent inactivation of p16 in oral premalignant lesions. Oncogene, 14: 1799-803, 1997a.

53. Papadimitrakoulou V, Izzo J, Lippman SM, Lee JS, Fan YH, Clayman G, Ro JY, Hittleman WN, Lotan R, Hong, WK, Mao L. Frequent inactivation of p16/INK4a in oral premalignant lesions. Bri J Cancer, 14: 1799-1803, 1997b.

54. Partridge, M., Kiguwa, S., and Langdon, J. Frequent deletion of chromosome 3p in oral squamous cell carcinoma. Oral Oncology, European Journal of Cancer, 30: 248-51, 1994.

55. Partridge M., Emillion G., and Langdon J. LOH at 3p correlates with a poor survival in oral squamous cell carcinoma. British Journal of Cancer, 73: 366-71, 1996.

56. Partridge M. and Emillion G *et al* Allelic imbalance at chromosomal loci implicated in the pathogenesis of oral precancer, cumulative loss and its relationship with progression to cancer Oral Oncology 34:77-83, 1998

57. Partridge M., Emillion G., Falworth M, Hern RA, Phillips E Pateromichelakis S, and Langdon J Patient-specific mutation databases for oral cancer. Int. J. Cancer (pred. Oncol.): 84:282-292, 1999a

58. Partridge M, Head and neck cancer and precancer: can we use molecular genetics to make better predictions? Ann R Coll Surg Engl 81:1-11, 1999b

59. Partridge M., Emillion G., Pateromichelakis S, Hern RA, Phillips E and Langdon J The prognostic significance of allelic imbalance at key chromosomal loci in oral cancer. British Journal of Cancer, 79(11/12): 1821-7, 1999c.

60. Pennisi, E. New gene forges link between fragile site and many cancers. Science, 272: 649, 1996.

61. Perhouse MA, El-Naggar AK, Hurr K, Lin H, Yung WKA, Steck PA. Deletion mapping of chromosome 4 in head and neck squamous cell carcinoma. Oncogene, 14, 369-373, 1997.

62. Raybaud-Diogene, H., Tetu, B., Morency, R., Fortin, A., and Monteil R. p53 overexpression in head and neck squamous cell carcinoma: review of the literature. Oral Oncology, European Journal of Cancer, 32B(3): 143-9, 1996.

63. Rawnsley JD, Srivatsan ES, Chakrabarti R, Billings KR, Wang MB. Deletion analysis of the p16/CDKN2 gene in head and neck squamous cell carcinoma using quantitative polymerase chain reaction method. Arch Otolaryngol Head Neck Surg., 123: 863-867, 1997.

64. Regezi JA, Sciubba JJ: Oral Pathology. Clinical-Pathologic Correlations. Edited by Regezi JA, Sciubba JJ. Toronto, WB Sanders Company, 1989, pp. 94-99.

65. Rosin MP, Cheng X, Poh CF, Priddy R, Berean K, Nakamur H, Zhang L: Leukoplakias that progressed to cancer have specific patterns of allelic loss. Cancer Res 1999, 40:136, Abstract #905.

66. Roz L, Wu CL, Porter S, Scully C, Speight P, Read A, Sloan P, Thakker N: Allelic imbalance on chromosome 3p in oral dysplastic lesions: an early event in oral carcinogenesis. Cancer Res 1996, 56(6):1228-1231.

67. Rowley H and Jones A *et al*, Definition of a tumor suppressor gene locus on the short are of chromosome 3 in squamous cell carcinoma of head and neck by means of microsatellite markers. Arch Otolaryngol Head Neck Surg.:122:497-501, 1996

68. Sartor M and Steingrimadottir H *et al* Role of p16/MTS1, cyclin D1 and RB in primary oral cancer and oral cancer cell lines British Journal of Cancer 80(1/2)79-86, 1999

69. Sard L and Accornero P *et al.* The tumor-suppressor gene FHIT is involved in the regilation of apoptosis and in cell cycle control. Proc Natl Acad Sci USA, 96 (15):8489-92,1999

70. Selwyn, M.R. Principles of experimental design for the life sciences CRC Press, Inc. 1996

71. Scholnick SB, Haughey BH, Sunwoo JB, El-Mofty SK, Baty JD, Piccirillo JF, Zequeira MR. Chromosome 8 allelic loss and the outcome of patients with squamous cell carcinoma of the supraglottic larynx. J Natl Cancer Inst., 88(22): 1676-1682, 1996.

72. Schreiber G, Pitterle D, Kim Y and Bepler G Molecular Genetic analysis of primary lung cancer and cancer metastatic to the lung Anticcancer Research 19: 1109-1116, 1999

73. Scully, C. and Field, J. Genetic aberrations in squamous cell carcinoma of the head and neck (SCCHN), with reference to oral carcinoma (Review). International Journal of Oncology, 10:5-21, 1996.

74. Silverman S, Jr, Gorsky M, Lozada F: Oral leukoplakia and malignant transformation. A follow-up study of 257 patients. Cancer 53:563-568, 1984

75. Somers KD, Cartwright SL, Schechter GL. Amplification of the *int-2* gene in human head and neck squamous cell carcinoma. Oncogene, 5: 915-920, 1990.

76. Sozzi, G., Veronese, M., Negrini, M., Baffa, R., Cotticelli, M., Inoue, H., Tornielli, S., Pilotti, S., De Gregorio, L., Pastorino, U., Pierotti, M., Ohta, M., Heubner, K., and Croce, C. The FHIT gene at 3p14.2 is abnormal in lung cancer. Cell, 85: 17-26, 1996.

77. Sozzi G and Pastorino U *et al.* Loss of FHIT function in lung cancer and pervasive bronchial lesions. Cancer Res 58(22): 5032-7, 1998

78. Sunwoo JB and Holt MS *et al* Evidence for multiple tumor suppressor genes on chromosome arm 8p in supraglottic laryngeal cancer Genes Chromosomes Cancer 16(3): 164-169, 1996

79. Thiberville L, Payne p *et al.* Evidence of cumulative gene losses with progreaaion of premalignant epithelial lesions to carcinoma of the bronchus. Cancer Res:55 (22):5133-9, 1995

80. Todd, R., McBride, J., Tsuji, T., Donoff, R., Nagal, M., Chou, M., Chiang, T., and Wong, D. Deleted in oral cancer-1 (*doc-1*), a novel oral tumor suppressor gene. FASEB, 9: 1362-70, 1995.

81. Uzawa K., Suzuki H, Komiya A, Nakanishi H, Ogawara K, Tanzawa H, Sato K: Evidence for two distinct tumor-suppressor gene loci on the long arm of chromosome 11 in human oral cancer. Int J Cancer 1996, 67:510-514.

82. Uzawa N, Yoshida MA, Hosoe S, Oshimura M Amagasa T and Ikeuchi T: Functional Evidence for involvement of multiple putative tumor suppressor gene on the short arm of chromosome 3 in human oral squamous cell carcinogenesis. Cancer Genet Cytogenet 107:125-131, 1998

83. Van der Riet P, Nawroz H, Hruban RH, Corio R, Tokino K, Koch W, Sidransky D. Frequent loss of chromosome 9p21-22 early in head and neck cancer progression. Cancer Res., 54: 1156-1158, 1994.

84. Van der Waal I, Schepman K. P., van der Meij H. E.and Smeele L.E..: Oral leukoplakia: a clinicopathological review. Oral Oncology, 33 (5) 291-301, 1997

85. Venugopalan M, Wood TF, Wilczunski SP, Sen S, Peters J, Ma GC, Evans GA, Srivatsan ES. Loss of heterozygosity in squamous cell carcinomas of the head and neck defines a tumor suppressor gene region on 11q13. Cancer Genet Cytogenet, 104: 124-132, 1998.

86. Waber, P., Lee N., and Nisen P. Frequent allelic loss at chromosome arm 3p is distinct from genetic alterations of the Von-Hippel Lindau tumor suppressor gene in head and neck cancer. Oncogene, 12: 365-9, 1996.

87. Waber P, Dlugosz S, Cheng QC, Truelson J, Nisen PD. Genetic alterations of chromosome band 9p21-22 in head and neck cancer are not restrected to p16/INK4a. Bri J Cancer, JUN: 1699-1704, 1997.

88. Waldron CA and Shafer WG Leukoplakia Revisited—A clinicopathologic study 3256 oral Leukoplakias, Cancer 36:1386-1392, 1975

89. Westra WH, Sidransky D: Phenotypic and genotypic disparity in premalignant lesions: of calm water and crocodiles. JNCI 1998, 90:1500-1501.

90. WHO Collaborating Reference Centre for Oral Precancerous Lesions: Definition of leukoplakia and related lesions: an aid to studies on oral precancer. Oral Surg 1978, 46:517-39.

91. Wilke, C., Hall, B., Hoge, A., Pardee, W., Smith, D., and Glover, T. FRA3B extends over a broad region and contains a spontaneous HPV16 integration site: direct evidence for the coincidence of viral integration sites and fragile sites. Human Molecular Genetics, 5: 187-95, 1996.

92. Wu C L, Sloan P, Read A P, Harris R, Thakker N. Deletion mapping on the short arm of chromosome 3 in squamous cell carcinoma of the oral cavity. Cancer Res 1994, 54: 6484-6488.

93. Wu CL, Roz L, Sloan P, Read AP, Holland S, Porter S., Scully C, Speight PM, Thakker N. Deletion mapping defined three discrete areas of allelic imbalance on chromosome arm 8p in oral and oropharyngeal squamous cell carcinoma. Gene Chrom Cancer, 20: 347-353, 1997.

94. Yoo GH, Xu HJ, Brennan JA, Westra W, Hruban RH, Koch W, Benedict WF, Sidransky D. Infrequent inactivation of the retinoblastoma gene despite frequent loss of chtomosome 13q in head and neck squamous cell carcinoma. Cancer Res., 54: 4603-4606, 1994.

95. Zhang L, Michelsen C, Cheng X, Zeng T, Priddy R, Rosin MP: Molecular analysis of oral lichen planus: A premalignant lesion? Am J Pathol 1997, 8:323-327.

10. APPENDIX

Table 1. LOH Frequencies (%) in Head and Neck and Oral Cancers

Chromosome arm	Oral Cancer				Head and Neck Cancers					
	Wu 1994	Uzawa 1996	Roz 1996	Ishwad 1996	Ah-See 1994	Nawroz 1994	Adamson 1994	Field 1995	Maestroe 1996	El-Naggar 1995
1p	*				14	30		27		
1q					0	23		28		
2p					0	19		28		
2q					8	15		13		
3p	**52**		**50**	**58**	**44**	**67**		**52**		**47**
3q					0	50		13		
4p					12	38		8		
4q					**11**	**37**		**13**		
5p					11	19		17		
5q					43	25		29		
6p				7	0	38		21		
6q					5	23		25		
7p					8	23		8		
7q				11	0	29		7		
8p					**10**	**40**		**35**		**53**
8q					7	38		21		
9p				**48**	**24**	**72**		**62**		**72**
9q					35	13		20		35

10p					0	23		9		
10q					0	21		13		
11p					5	17		13		
11q		**56**		**6**	**45**	**61**		**23**		**33**
12p					7	18		14		
12q					12	25		15		
13p										
13q					**0**	**54**		**27**	**67**	
14p										
14q					5	39		11		
15p										
15q					6	5		12		
16p					0	10		13		
16q					0	10		13		
17p					**31**	**52**	**50**	**50**		
17q					19	31		30		
18p					0	27		16		
18q					0	23		49		
19p					0	32		0		
19q					0	40		29		
20p					0	30		0		
20q					7	9		9		
21p										
21q					5	26		8		
22p										
22q					16	29		0		

*Blanks indicate information not available.

Table 6 The time between initial biopsy and current date /the date on which a lesion has progressed to SCC

Groups	Case #	Arms with LOH	Arms with NI	# arms lost	Time between initial biopsy and current date/SCC (mo.)
Without progression set					
Mild dysplasia	108		4q	0	65
	180			0	122
	184			0	161
	186	3p,9p,17p,11q		4	164
	187	9p,4q		2	183
	188	9p		1	123
	191	3p,9p,11q		3	155
	201	9p		1	145
	206			0	130
	207			0	112
	209	9p		1	159
	233			0	103
	239			0	28
	240	9p		1	145
	241	9p	4q	1	127
	242	11q	9p	1	122
	246	3p,11q		2	135
	248			0	112
	256			0	112
	258	3p,9p,17p		3	103
	270	8p		1	110

	277	17p,4q	3p,11q	2	147
	12	3p		1	65
	21			0	66
	26			0	65
	51			0	52
	55	3p	4q	1	52
	60		8p	0	54
	64			0	41
	88	9p,17p,8p,13q	3p	4	42
	92	9p	8p,13q	1	40
Moderate dysplasia	143	3p,9p,17p,8p,13q		5	37
	163	3p,9p,17p,11q		4	37
	167	9p		1	141
	168	3p,9p,17p,8p	11q	4	62
	169	3p,9p		2	142
	176			0	164
	177	3p,9p,17p,8p		4	32
	189	9p,4q,8p		3	170
	190	3p,9p,17p,8p	4q	4	145
	214	3p,9p		2	105
	232	9p		1	147
	234	9p		1	109
	243			0	104
	257		8p	0	110
	274			0	28
	22	9p,17p		2	65
	25	4q		1	64

	27			0	50
	32	3p,9p,17p,11q	4q	4	44
	34	8p		1	47
	66			0	47
	71		4q,9p	0	59
	76			0	66
Hyperplasia	101			0	41
	102		4q	0	41
	103			0	41
	111		8p,11q	0	41
	127		3p	0	35
	129	3p		1	37
	130	3p		1	37
	131	13q		1	36
	132			0	36
	133			0	37
	134		3p	0	35
	135			0	38
	136			0	35
	137			0	36
	138	3p		1	41
	139			0	41
	140			0	37
	141			0	36
	142			0	42
	144			0	36
	146	9p		1	37
	148	11q		1	36

	149		13q	0	36
	150		4q	0	37
	151	3p		1	37
	152			0	36
	171		3p,8p,11q	0	34
	172		9p	0	34
	179			0	34
	183			0	34
	11			0	43
	23			0	42
	28			0	43
With progression set					
Mild and moderate dysplasia	173	3p, 9p, 8p,11q,13q		5	16
	122	3p,9p,17p,8p,11q		5	99
	223	9p		1	51
	271	3p,9p,17p,11q,13q	8p	5	10
	293	3p,9p,17p		3	26
	399	9p,17p		2	10
	365	9p		1	26
	446	9p,8p		2	60
	472	3p, 9p, 4q, 8p, 11q		5	85
	185	9p,4q		2	83
	197	3p,9p	4q,13q	2	7
	377	3p,9p		2	70
	473	3p,8p,11q		3	11

	245	3p,9p	17p	2	56
	281	3p,9p,17p,4q,8p,11q		6	52
	401	9p,17p,4q,8p,11q,13q	3p	6	15
	286	3p,17p,8p,13q		4	11
	460	3p,9p,4q,11q,13q		5	46
	79	3p,9p,17p,4q	13q	4	29
	464	3p,17p,8p		3	27
	121	9p,8p		2	29
	470	8p,11q,13q		3	6
	95	9p,13q	4q	2	32
Hyperplasia	405	9p	13q	1	7
	385	3p		1	16
	406	9p,17p,11q		3	12
	416	3p	13q	1	72
	471	3p,4q,8p		3	105
	363	3p,9p,17p,4q,8p,11q		6	76