

Rapid Hemostasis in a Sheep Model Using Particles That Propel Thrombin and Tranexamic Acid

James R. Baylis, BSc; Andres Finkelstein-Kulka, MD; Luis Macias-Valle, MD; Jamil Manji, MSc; Michael Lee, BSc; Elina Levchenko, BSc(c); Christopher Okpaleke, MPH; Salahuddin Al-Salihi, MD; Amin Javer, MD; Christian J. Kastrup, PhD

From the Michael Smith Laboratories and Department of Biochemistry and Molecular Biology, University of British Columbia, Vancouver, British Columbia, Canada (J.B., M.L., E.L., C.K.); St. Paul's Sinus Center, St. Paul's Hospital, Vancouver, British Columbia, Canada (A.F.-K., L.M.-V., J.M., C.O., S.A.-S., A.J.); Facultad de Medicina, Clinica Alemana Universidad del Desarrollo, Santiago, Chile (A.F.); and Hospital Español de México, Facultad Mexicana de Medicina, Universidad La Salle, Mexico City, Mexico (L.M.-V.).

Editor's Note: This Manuscript was accepted for publication October 10, 2016.

This work was presented to the American Rhinologic Society at the Combined Otolaryngologic Societies Meetings, Chicago, Illinois, U.S.A., May 19, 2016.

J.B. and A.F. contributed equally to this work. A.J. and C.K. contributed equally to this work.

This work was funded by Canadian Institutes of Health Research (PPP-136718, MOP-119426, and MSH-130166).

J.B. and C.K. have filed a patent application and are involved in commercialization activities related to self-propelling particles.

The authors have no other funding, financial relationships, or conflicts of interest to disclose.

Send correspondence to Amin Ramzanali Javer, St. Paul's Sinus Center, St. Paul's Hospital, 1081 Burrard Street, Vancouver, BC V6Z 1Y6, Canada. E-mail: sinusdoc@me.com

Objectives/Hypothesis: Bleeding during endoscopic sinus surgery and open surgeries can easily obstruct the surgeons' field of view and increase morbidity and risk of intraoperative complications. Intraoperative bleeding could potentially be addressed by a hemostatic agent that safely disperses itself through the escaping blood. We tested the safety and efficacy of a self-propelling formulation of thrombin and tranexamic acid (SPTT) in stopping bleeding in a paranasal sinus injury and in an open surgical carotid injury sheep model.

Study Design: Interventional animal study.

Methods: SPTT was tested in the sinonasal space following endoscopic injury to the inferior turbinate of six sheep, and to the common carotid artery following open surgical injury in eight sheep. In the nasal cavity, bleeding time and local inflammation were measured and compared to plain gauze. Following carotid arteriotomy, successful hemostasis and markers of thrombosis and coagulopathy were compared to Floseal.

Results: SPTT significantly decreased bleeding times in the sinonasal space compared to plain gauze (mean difference = 3.8 minutes, $P = .002$). All of the carotid bleeds (100%) were successfully controlled with SPTT after 10 minutes of application under pressure, compared to 25% with Floseal. No adverse events were noted, and there was no evidence of thromboembolism.

Conclusions: SPTT significantly reduced bleeding time in a sheep model of surgical sinus bleeding and successfully stopped bleeding following catastrophic carotid artery injury, with no adverse events observed.

Key Words: Functional endoscopic sinus surgery, hemostat, intraoperative bleeding, catastrophic bleeding, calcium carbonate, fibrinolysis.

INTRODUCTION

Poorly controlled intraoperative bleeding can lead to complications such as infection, procedural error death.¹ In endoscopic surgery, intraoperative bleeding is especially problematic, given the narrow field of view; even moderate bleeding can sufficiently obstruct the surgical field.² Intraoperative bleeding during functional endoscopic sinus surgery (FESS) can be reduced by perioperative measures, including preoperative corticosteroids, controlled hypotension, the reverse Trendelenburg position, vasoconstrictors, and warm saline irrigation.³⁻⁷ However, these techniques are limited and not suited for managing acute severe bleeding.

When inadvertent injury to the internal carotid artery, anterior or posterior ethmoid, or sphenopalatine artery occurs during FESS, management must be swift, as the patient can decompensate within minutes.⁸⁻¹⁰ Immediate tamponade with nasal packing can be applied in these scenarios, but this is associated with high morbidity and mortality if the ruptured vessel becomes stenosed or occluded.¹¹ Electrocauterization can also be effective, but is associated with severe unfavorable tissue reactions.¹² Recently, more powerful topical hemostatic agents such as Floseal matrix containing thrombin (Baxter International, Deerfield, IL), Surgicel (Ethicon; Johnson & Johnson, New Brunswick, NJ), chitosan gel, fibrin-based products, and muscle patches have been proposed as effective interventions with fewer adverse events.^{13,14} Fortunately, such bleeds are

rare, occurring in approximately 1% of patients undergoing pituitary surgery, and more frequently in complex skull base procedures.¹⁵

Topical hemostatic agents that contain thrombin, which is an endogenous coagulation enzyme, have emerged at the forefront for management of catastrophic surgical bleeding as well as intractable epistaxis.^{13,16} One of these agents, Floseal, is known to worsen long-term surgical outcomes, such as by increasing granulation tissue and adhesions, but these are often considered acceptable losses in the context of severe bleeding scenarios.^{17,18} However, the applicabilities of these agents are inherently limited during FESS or during severe epistaxis. These topical agents are indicated only when bleeding sites can be visualized, which is often difficult.² When blood loss is severe, conventional topical agents cannot reach the damaged vasculature due to the rapid outflow of blood. We hypothesize that a self-propelling hemostatic agent, which can move through flowing blood to the bleeding wounds, would be more effective than current static hemostatic strategies used in epistaxis, FESS, and cases of catastrophic bleeding.

We have developed a self-propelling hemostatic agent that vigorously effervesces upon contact with blood.¹⁹ This agent consists of calcium carbonate (CaCO_3) microparticles, thrombin, and tranexamic acid (TXA), which is an antifibrinolytic agent that is administered systemically. When applied to a wound, CaCO_3 propels and disperses thrombin and TXA against flow, thereby improving contact with the bleeding vasculature. This propulsion significantly reduced blood loss in multiple *in vivo* and *in vitro* models of hemorrhage; for example, when formulated upon gauze, it significantly increased survival in a swine femoral artery bleeding model of fatal junctional hemorrhage in combat settings.^{19,20} Here, we tested to see whether this agent, a self-propelling formulation of thrombin and TXA (SPTT), is safe and effective in producing hemostasis in a sheep model of minor and major surgical bleeding.

MATERIALS AND METHODS

Preparation of SPTT

SPTT for application to turbinate injuries was prepared based on previously described methods.¹⁹ To adsorb CaCO_3 and thrombin onto gauze, 188 mg of CaCO_3 microparticles (American Elements, Los Angeles, CA), 188 μL glycine-buffered saline (GBS; 40 mM glycine, 171 mM NaCl, pH 7.2), and 0.34 mg human thrombin (specific activity = $\sim 3,650$ U/mg; Haematologic Technologies, Essex Junction, VT) were coincubated on ice for 20 minutes. Suspensions were diluted by addition of 188 μL GBS, and pipetted onto 2.5 x 2.5-cm² pieces of Kerlix gauze (Covidien, Dublin, Ireland), which were then lyophilized. To load gauze with protonated TXA, 375 μL TXA solution (2 M, pH 4.3; Chem-Impex International, Wood Dale, IL) was applied to an equal amount of Kerlix gauze, which was then baked for 30 minutes at 120°C. CaCO_3 -thrombin gauze and TXA gauze were layered to form SPTT immediately prior to application to the turbinate.

SPTT for application to carotid injuries was prepared similarly; Kerlix gauze measuring 10 x 10 cm² was loaded with 6.5 g CaCO_3 and 0.34 mg (1,250 IU) human thrombin, and a separate gauze of equal dimensions was loaded with 3.9 g of protonated TXA.

Animal Preparation and Instrumentation

All procedures involving animals were approved by the University of British Columbia Animal Care Committee (protocol #A14-0172) and performed according to Canadian Council on Animal Care guidelines. Dorset cross sheep (average bodyweight = 51 kg) were induced using 4 to 6 mg/kg of intravenous propofol. Animals were then intubated and maintained on isoflurane anesthesia (2%–5%). Ketoprofen (3 mg/kg) was given subcutaneously to manage postoperative pain, and an esophageal tube was placed to prevent bloat. Heart rate, electrocardiogram, noninvasive blood pressure, expired carbon dioxide, inspired and expired isoflurane, oxygen saturation, and temperature were monitored throughout all procedures.

Initial Biopsy and Initiation of Hemorrhage

Six sheep were included in this part of the study. Nasal cavities were explored with a 08 rigid endoscope, and inferior turbinates were identified. Using right- and left-angled 3-mm through-cutting Toffel punches (Access 11-371, 11-372), a turbinate biopsy/injury was performed in the medial aspect of the middle third (posterior injury). SPTT gauze or plain gauze, which was deidentified to the operator, was applied to the site of the injury for 60 seconds using Blakesley forceps. After gauze removal, bleeding was monitored endoscopically for 10 minutes. Neither gauze contained any other agents to reduce nasal trauma during gauze removal. Attempts to quantify volumetric blood loss were unsuccessful, as suction could not be applied concomitantly with compression and endoscopic visualization of the injury site. Additionally, it was not

possible to quantify any blood that may have flowed posteriorly into the nasopharynx. This procedure was replicated to produce a posterior injury on the contralateral side. After bleeding from each posterior injury had abated, the posterior injury sites were covered with gauze to prevent anterograde flow of any SPTT residue. Following this, similar injuries were repeated anteriorly and placed 1 cm posterior to the head of the inferior turbinate (anterior injury). Four injuries were completed per animal, for a total of 24 injuries over six sheep. Following randomization of the first injury, the remaining three injuries were assigned such that each turbinate received both treatments, and treatment assignments on the contralateral turbinate were reversed anterior–posterior. Animals were recovered and monitored for 2 days.

To test whether SPTT was associated with any medium-term adverse events, four separate sheep were used. Bleeding was initiated and treated as described above, except that each turbinate received only one biopsy/injury (two total per sheep), and each sheep was treated with either SPTT containing 156 IU of thrombin or Floseal containing an equal dose of thrombin. Animals were recovered and monitored for 15 or 17 days for any changes to behavior or vital signs.

Carotid Artery Injury

Eight sheep were included in this part of the study. While anesthetized, a midline vertical neck incision was performed, and dissection was completed until identification of the strap muscles. The deep neck facial layers were followed until the right carotid sheath was identified. The common carotid artery was dissected away from surrounding tissues to obtain a minimum of 5 cm of artery exposure. The artery was clamped proximally and punctured using an 11-blade scalpel, to enable a standard arteriotomy using a 4-mm endoscopic mushroom punch. Punch injuries are regularly used for testing the efficacy of hemostatic agents in large animal models of hemorrhage, although a linear vascular injury could have been used to cause even greater bleeding.^{21,22} Clamps were released to initiate bleeding. After 3 seconds of free bleeding and with the operator blinded, SPTT gauze or gauze containing Floseal with an equal amount of thrombin (1,250 IU) was directly applied to the puncture site. Plain gauze pack was mounted above the SPTT or Floseal gauze, and 36 N (8 lb) of force was applied for 10 minutes. Local pressure to the internal carotid is a maneuver clinically accepted in neck surgery and endoscopic procedures; however, the magnitude and direction of pressure may differ between clinical scenarios. Bleeding was assessed after 10 minutes by releasing pressure, and visualizing the injury without removal of the SPTT or Floseal gauze. If hemostasis was achieved, the final gauze was removed and recurrence of hemorrhage was recorded. Carotid arteries were then ligated and animals were euthanized by sodium pentobarbital overdose (120 mg/kg intravenously). Once again, bleeding volumes could not be accurately measured in this model due to the high pressure and projectile nature of the bleed, which flooded the surgical field rapidly after injury.

Histology, Coagulation Analysis, and Necropsy

Biopsies of turbinate injury sites at baseline and at 48 hours post-treatment were examined histologically. These images were scored by a blinded, certified pathologist for inflammation, ulceration, infiltrate, and inflammatory debris using the following scale: 0 = normal microscopic findings, 1 = minimal, 2 = mild, 3 = moderate, 4 = severe. Blood was collected at baseline, 48 hours after turbinate injury, and approximately 20 minutes after carotid injury to measure semiquantitative fibrinogen concentration, D-dimer levels, hemoglobin, hematocrit, platelet count, prothrombin time (PT), and activated partial thromboplastin times (APTT). Following sacrifice, carotid arteries were excised and grossly examined for any vessel occlusion. Cadavers were necropsied, and brains, lungs, and hearts were grossly examined for ischemic or infarctive lesions.

Statistical Analysis

All statistical analyses were performed with Prism 5 (GraphPad Software, San Diego, CA). Bleeding times, pathologist scores, and coagulation parameters were compared by Mann-Whitney U test. When a group of baseline pathologist scores or semiquantitative fibrinogen concentrations were each the same value, comparisons were made with a Wilcoxon signed-rank test.

RESULTS

After turbinate injuries, sites receiving SPTT bled for 5.09 ± 2.25 minutes (mean \pm standard error), compared to 8.21 ± 2.16 minutes for plain gauze sites ($P = .002$, Fig. 1B). Four of the 12 control sites did not achieve hemostasis within 10 minutes, whereas all SPTT sites did. To confirm that the location of turbinate injury did not significantly affect bleed times, anterior and posterior sites that had received the same treatment were compared. Anterior and posterior SPTT sites were not significantly different, bleeding for 5.32 ± 2.85

minutes and 4.85 ± 1.70 minutes, respectively ($P = .76$). Similarly, anterior and posterior control sites were not significantly different, bleeding for 7.94 ± 2.26 minutes and 8.47 ± 2.22 minutes, respectively ($P = .43$). At baseline, all pathologist scores for ulceration, infiltration, inflammation, and inflammatory debris were 0 except for one inflammation score of 1 (Fig. 2). Two days after turbinate injury, mean scores for each parameter increased for SPTT and control sites; however, significant differences were only seen when comparing baseline inflammation with SPTT ($P = .01$) and baseline ulceration with control ($P = .05$; Table I). There were no significant differences in pathologist scores between SPTT sites and control sites.

Following carotid artery injury and compression, SPTT stopped bleeding in 100% (four of four) cases when dressings remained in place (Table II). When the dressings were fully removed, rebleeding occurred in 75% (three of four) of these injuries. Floseal stopped bleeding in 25% (one of four) injuries, and this injury did not rebleed when the dressing was removed. In animals that did not achieve hemostasis following removal of dressings, bleeding was severe and not expected to halt without further intervention.

Baseline hemoglobin concentrations were 93 ± 6 mg/mL, hematocrits were 0.28 ± 0.02 , and platelet counts were 266 ± 96 10⁹/L (Fig. 3). PT and APTT were 13.7 ± 0.9 seconds and 35.5 ± 6.5 seconds, respectively. Semiquantitative fibrinogen concentration was 1.0 mg/mL for each sample. D-dimer concentrations were 176 ± 78.7 ng/mL (Fig. 4). Two days following turbinate injury, no parameter changed significantly except hemoglobin. Additionally, D-dimer levels did not differ significantly between any time points or between sheep that received SPTT or Floseal to their carotid injuries ($P > .05$).

No occluded vessels were found in any animal postmortem. No signs of thromboembolism or ischemia were found during gross inspection and histopathology of heart, brain, and lungs. No animal showed any major changes in behavior or vitals within 15 or 17 days following turbinate injury.

DISCUSSION

During FESS and cases of epistaxis, mild to moderate bleeding is common and can be managed easily without long-term sequelae; however, profuse blood loss can be very difficult to manage and could increase morbidity and mortality. Various hemostatic agents have been developed for sinus surgery and primary epistaxis, but blood flow pushes these agents away from the bleeding site, decreasing their contact times and their ability to form stable clots. The sheep model used here was a remarkable replication of the most relevant clinical bleeding events faced by rhinologists. The turbinate injury model accurately represents common FESS bleeding and primary epistaxis events, whereas the carotid bleed model reflects the most catastrophic scenarios. Both injuries were easily induced and highly reproducible, and thus work is ongoing to validate this sheep model for research in FESS.^{23,24}

In this study, we show that SPTT stopped both protracted surgical epistaxis and massive carotid bleeding, and we detected no adverse events. Therefore, SPTT may become an invaluable agent to reduce bleeding and improve patient outcomes in a variety of FESS and difficult epistaxis scenarios where current treatments are slow or fail to achieve hemostasis.

In the turbinate injury model, SPTT significantly decreased and nearly halved bleeding times compared to controls that received only local pressure with plain gauze. In sinus surgery, SPTT could improve field of view to allow for more complete surgery while reducing operating time and incidence of complications associated with profuse and continued bleeding. Treatment of turbinate injuries with SPTT did not cause any more local tissue damage than plain gauze alone, even without irrigation or use of corticosteroids.²⁵ Some packing agents have been shown to increase granulation tissue and adhesions in patients, which require subsequent lysis.^{17,18} Specifically, gelatin-containing resorbable hemostatic agents, such as Floseal and Gelfoam (Pfizer, New York, NY), have been shown to worsen inflammation, elicit foreign body reactions, and cause fibrosis potentially leading to adhesions.^{26–28} Although some of these agents also contain thrombin, thrombin is suggested to be uninvolved in adhesion formation.¹⁸ Therefore, a thrombin-containing gelatin-free hemostatic agent, such as SPTT, which can achieve rapid hemostasis without causing increased inflammation, would be very desirable. However, further studies are required to determine how SPTT compares to other hemostatic agents regarding long-term sequelae relating to inflammation and healing, such as fibrosis or adhesions over months following application.

Powerful hemostatic agents, such as thrombin, carry risks of thrombosis, especially following application to major vessels such as carotid arteries.²⁹ To determine whether SPTT caused thrombosis, systemic D-dimer concentrations were measured. D-dimer concentrations are measured to clinically rule out thrombosis. D-dimer levels that can rule out thrombosis have not been established for sheep; however, all concentrations measured here are within normal ranges for sheep, humans, and other laboratory animals, such as dogs.^{30,31}

Furthermore, D-dimer concentrations at 48 hours after turbinate injury did not differ significantly from baseline, suggesting no incidence of thromboembolism.³² Similarly, of the other blood count parameters measured, only hemoglobin significantly differed between baseline and 48 hours post-application. No signs of pain or adverse events were observed up to 17 days after treatment. Together, these results suggest that no significant thrombotic events occurred and that the risk of thrombosis associated with paranasal application of SPTT is low. However, further preclinical studies involving larger numbers of animals are required to demonstrate this rigorously, and to translate this technology for use in humans.

In this model, SPTT also effectively stopped bleeding from the common carotid artery, which is a high-flow, high-pressure bleed that is a catastrophic complication of surgery. There have been conflicting reports regarding which hemostatic agent should be used in the event of an endoscopic carotid artery bleed. One study, which used a live sheep endoscopic carotid artery injury model, concluded that the U-clip and the muscle patch

are superior to Floseal, oxidized regenerated cellulose, and chitosan gel.³³ However, a systematic review that included different endoscopic and open surgical approaches showed that Floseal was superior in reducing blood loss.¹³ Given that our carotid injury model was an open approach, we chose to compare SPTT to Floseal. When clot disruption was avoided, by allowing the gauze to remain adhered to the bleeding site, SPTT achieved hemostasis in more sheep than Floseal. This strongly suggests that SPTT may be an effective clinical treatment of catastrophic intraoperative bleeding. However, further studies are required to demonstrate SPTT's efficacy and superiority to clinical standards, such as the muscle patch, and to optimize SPTT's formulation and method of application.

No signs of thromboembolism were seen by gross inspection or histopathology of heart, brain, and lungs in any animals treated with SPTT or Floseal. However, additional studies that investigate long-term embolic, thrombotic, or ischemic risks associated with using SPTT for major arterial bleeds are required. These studies are especially pertinent to test SPTT's safety in carotid injuries, as the model presented here did not allow recovery of the animals or time for neurological deficits and secondary ischemic strokes to manifest.³⁴

CONCLUSION

This study has demonstrated that self-propelling thrombin- and TXA-loaded particles can effectively treat bleeding in an endoscopic sinus surgery and open carotid injury model. Following turbinate injury, SPTT achieved hemostasis significantly faster than standard gauze packing. There was no indication that SPTT caused any local tissue damage or systemic thrombosis. Moreover, SPTT remarkably stopped catastrophic bleeding following carotid artery injury and preliminary results suggest its efficacy is comparable or superior to clinical standards for managing severe bleeding. Although this self-propelled particle-based hemostatic agent was efficacious and did not have adverse effects in this model, further preclinical studies are required to fully understand its longer-term safety risks prior to clinical testing.

Acknowledgment

The authors thank J. H. Yeon, University of British Columbia (UBC) Animal Care Services, and the UBC Centre for Comparative Medicine for helpful suggestions.

BIBLIOGRAPHY

1. Marietta M, Facchini L, Pedrazzi P, Busani S, Torelli G. Pathophysiology of bleeding in surgery. *Transplant Proc* 2006;38:812–814.
2. Athanasiadis T, Beule A, Embate J, Steinmeier E, Field J, Wormald PJ. Standardized video-endoscopy and surgical field grading scale for endoscopic sinus surgery: a multi-centre study. *Laryngoscope* 2008;118:314–319.
3. Wright ED, Agrawal S. Impact of Perioperative systemic steroids on surgical outcomes in patients with chronic rhinosinusitis with polyposis: evaluation with the novel Perioperative Sinus Endoscopy (POSE) scoring system. *Laryngoscope* 2007;117:1–28.
4. Boonmak S, Boonmak P, Laopaiboon M. Deliberate hypotension with propofol under anaesthesia for functional endoscopic sinus surgery (FESS). *Cochrane Database Syst Rev* 2013;(6):CD006623.
5. Hathorn IF, Habib A-RR, Manji J, Javer AR. Comparing the reverse Trendelenburg and horizontal position for endoscopic sinus surgery: a randomized controlled trial. *Otolaryngol Head Neck Surg* 2013;148:308–313.
6. Lee TJ, Huang CC, Chang PH, Chang CJ, Chen YW. Hemostasis during functional endoscopic sinus surgery: the effect of local infiltration with adrenaline. *Otolaryngol Head Neck Surg* 2009;140:209–214.

7. Gan EC, Alsaleh S, Manji J, Habib AR, Amanian A, Javer AR. Hemostatic effect of hot saline irrigation during functional endoscopic sinus surgery: a randomized controlled trial. *Int Forum Allergy Rhinol* 2014;4:877–884.
8. Pepper JP, Wadhwa AK, Tsai F, Shibuya T, Wong BJF. Cavernous carotid injury during functional endoscopic sinus surgery: case presentations and guidelines for optimal management. *Am J Rhinol* 2007;21:105–109.
9. Chin OY, Ghosh R, Fang CH, Baredes S, Liu JK, Eloy JA. Internal carotid artery injury in endoscopic endonasal surgery: a systematic review. *Laryngoscope* 2016;126:582–590.
10. Weidenbecher M, Huk WJ, Iro H. Internal carotid artery injury during functional endoscopic sinus surgery and its management. *Eur Arch Otorhinolaryngol* 2005;262:640–645.
11. Anand VK, Alemar GO, Sanders TS. Management of the internal carotid artery during carotid-body tumor surgery. *Laryngoscope* 1995;105:231–235.
12. Jensen SS, Yazdi PM, Hjorting-Hansen E, Bosshardt DD, von Arx T. Haemostatic effect and tissue reactions of methods and agents used for haemorrhage control in apical surgery. *Int Endod J* 2010;43:57–63.
13. Echave M, Oyagueez I, Casado MA. Use of FloSealVR, a human gelatine-thrombin matrix sealant, in surgery: a systematic review. *BMC Surg* 2014;14:111.
14. Padhye V, Valentine R, Sacks R, et al. Coping with catastrophe: the value of endoscopic vascular injury training. *Int Forum Allergy Rhinol* 2015;5: 247–252.
15. Solares CA, Ong YK, Carrau RL, et al. Prevention and management of vascular injuries in endoscopic surgery of the sinonasal tract and skull base. *Otolaryngol Clin North Am* 2010;43:817–825.
16. Oz MC, Cosgrove DM, Badduke BR, et al. Controlled clinical trial of a novel hemostatic agent in cardiac surgery. *Ann Thorac Surg* 2000;69:1376–1382.
17. Chandra RK, Conley DB, Haines GK, Kern RC. Long-term effects of FloSeal(TM) packing after endoscopic sinus surgery. *Am J Rhinol* 2005;19: 240–243.
18. Chandra RK, Conley DB, Kern RC. The effect of FloSeal on mucosal healing after endoscopic sinus surgery: a comparison with thrombin-soaked gelatin foam. *Am J Rhinol* 2003;17:51–55.
19. Baylis JR, Yeon JH, Thomson MH, et al. Self-propelled particles that transport cargo through flowing blood and halt hemorrhage. *Sci Adv* 2015;1:e1500379.
20. Baylis JR, St. John AE, Wang X, et al. Self-propelled dressings containing thrombin and tranexamic acid improve short-term survival in a swine model of lethal junctional hemorrhage. *Shock* 2016;46(3 suppl 1):123–128.
21. Kheirabadi BS, Arnaud F, McCarron R, et al. Development of a standard swine hemorrhage model for efficacy assessment of topical hemostatic agents. *J Trauma* 2011;71(1 suppl):S139–S146.
22. Padhye V, Valentine R, Paramasivan S, et al. Early and late complications of endoscopic hemostatic techniques following different carotid artery injury characteristics. *Int Forum Allergy Rhinol* 2014;4:651–657.
23. Acar B, Gunbey E, Babademez MA, Karabulut H, Gunbey HP, Karasen RM. Utilization and dissection for endoscopic sinus surgery training in the residency program. *J Craniofac Surg* 2010;21:1715–1718.
24. Gardiner Q, Oluwole M, Tan L, White PS. An animal model for training in endoscopic nasal and sinus surgery. *J Laryngol Otol* 1996;110:425–428.
25. Shoman N, Gheriani H, Flamer D, Javer A. Prospective, double-blind, randomized trial evaluating patient satisfaction, bleeding, and wound healing using biodegradable synthetic polyurethane foam (NasoPore) as a middle meatal spacer in functional endoscopic sinus surgery. *J Otolaryngol Head Neck Surg* 2009;38:112–118.
26. Clapp B, Santillan A. Small bowel obstruction after FloSeal use. *JSLs* 2011;15:361–364.
27. Antisdell JL, Janney CG, Long JP, Sindwani R. Hemostatic agent microporous polysaccharide hemospheres (MPH) does not affect healing or intact sinus mucosa. *Laryngoscope* 2008;118:1265–1269.
28. Caglar M, Yavuzcan A, Yildiz E, Yilmaz B, Dilbaz S, Kumru S. Increased adhesion formation after gelatin-thrombin matrix application in a rat model. *Arch Gynecol Obstet* 2014;290:501–506.
29. Kheirabadi BS, Mace JE, Terrazas IB, et al. Safety evaluation of new hemostatic agents, smectite granules, and kaolin-coated gauze in a vascular injury wound model in swine. *J Trauma* 2010;68:269–278.
30. Jain NC. *Schalm's Veterinary Hematology*. Philadelphia, PA: Lea & Febiger; 1986.
31. Ota S, Wada H, Nobori T, et al. Diagnosis of deep vein thrombosis by plasma-soluble fibrin or D-dimer. *Am J Hematol* 2005;79:274–280.
32. Orunc Kilinc O, Goz Y, Yuksek N, Basbugan Y, Yilmaz AB, Atas AD. Determination of serum cardiac

biomarkers and plasma D-dimer levels in anemic sheep with babesiosis. *Turk J Vet Anim Sci* 2015;39:606–610.

33. Valentine R, Boase S, Jervis-Bardy J, Cabral J-DD, Robinson S, Wormald PJ. The efficacy of hemostatic techniques in the sheep model of carotid artery injury. *Int Forum Allergy Rhinol* 2011;1:118–122.
34. Karnecki K, Jankowski Z, Kalisz M. Direct penetrating and indirect neck trauma as a cause of internal carotid artery thrombosis and secondary ischemic stroke. *J Thromb Thrombolysis* 2014;38:409–415.

FIGURES AND TABLES:

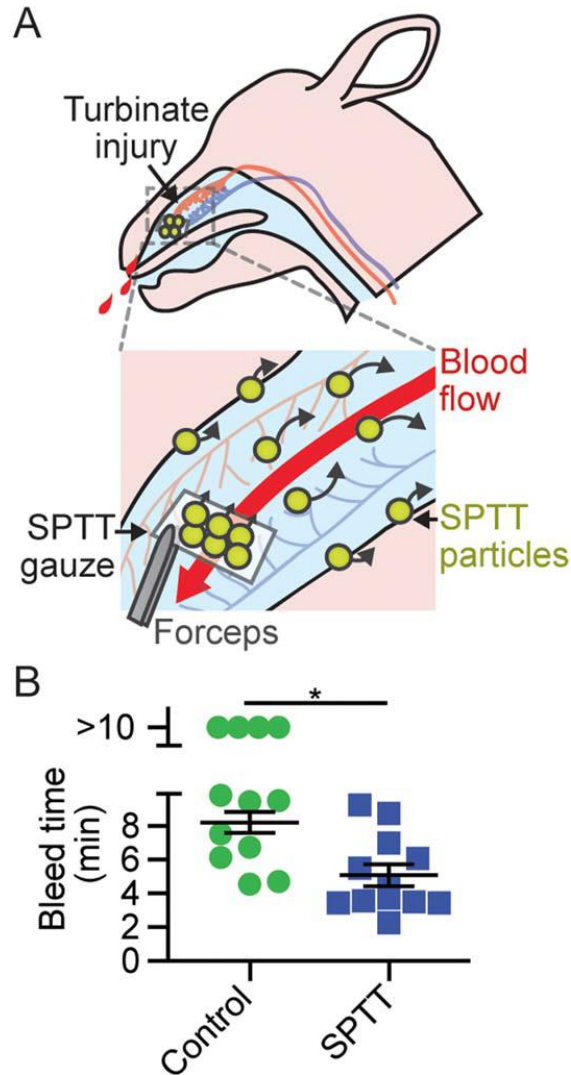


Fig. 1. Self-propelling formulation of thrombin and tranexamic acid (SPTT) decreases bleed times following turbinates injury. (A) Schematic showing SPTT-loaded gauze being applied paranasally and SPTT particles rapidly delivering cargo through blood flow. (B) Bleed times following turbinates injury and application of hemostatic agent. $n = 12$. $*P < .01$. Error bars represent standard error of the mean. [Color figure can be viewed in the online issue, which is available at www.laryngoscope.com.]

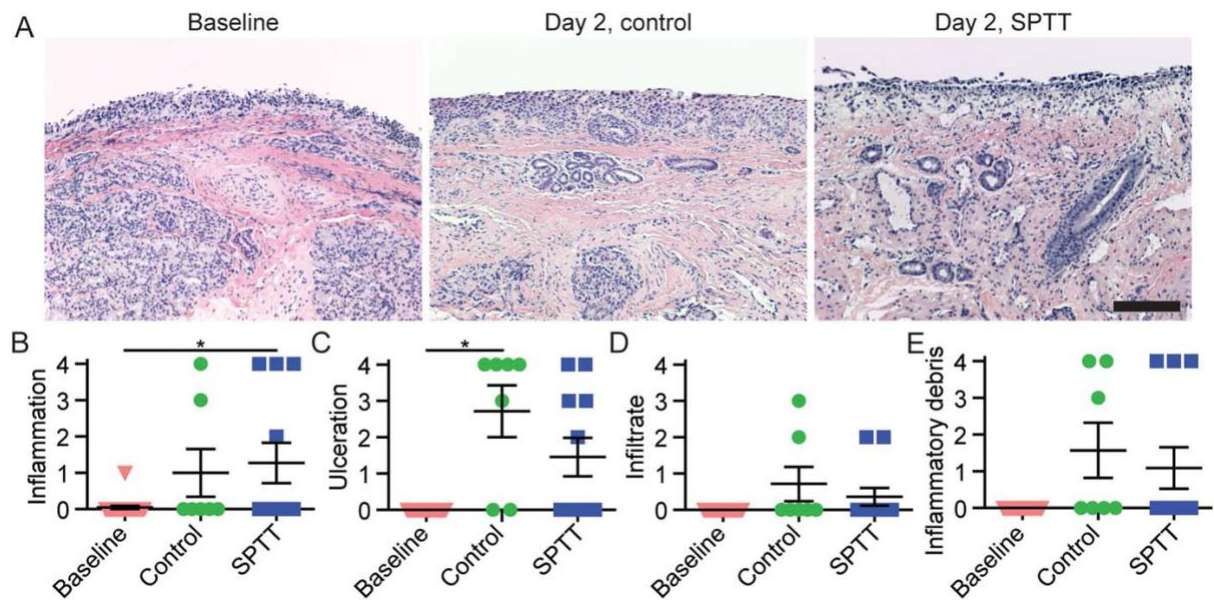


Fig. 2. Assessing self-propelling formulation of thrombin and tranexamic acid (SPTT)'s local tissue damage in the inferior turbinate following injury and treatment. (A) Representative histopathological images of turbinate epithelium at baseline and 2 days postinjury. Scale bar = 150 μ m. (B–E) Pathologist scores for inflammation, ulceration, infiltrate, and inflammatory debris of turbinate biopsies 2 days postinjury. Error bars represent standard error of the mean. $n = 7-23$. $*P < .05$. [Color figure can be viewed in the online issue, which is available at www.laryngoscope.com.]

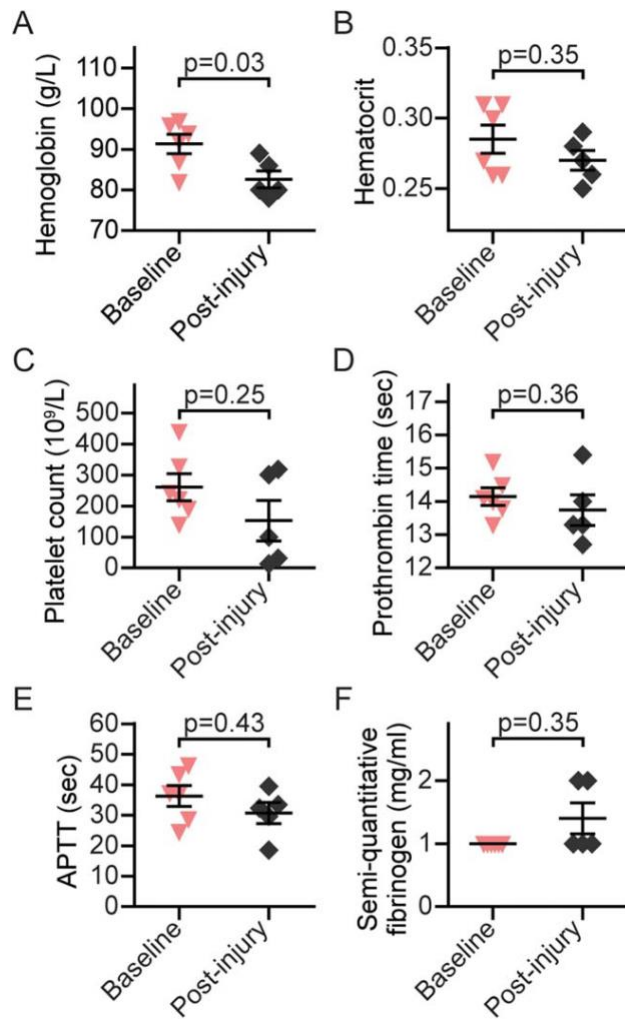


Fig. 3. Hematological analysis of venous blood samples at presurgical baseline and 48 hours after turbinate injury and hemostatic treatment, including hemoglobin, hematocrit, platelet count, prothrombin time, activated partial thromboplastin time, and semi-quantitative fibrinogen. Error bars represent standard error of the mean. $n = 5-6$. SPTT = self-propelling formulation of thrombin and tranexamic acid. [Color figure can be viewed in the online issue, which is available at www.laryngoscope.com.]

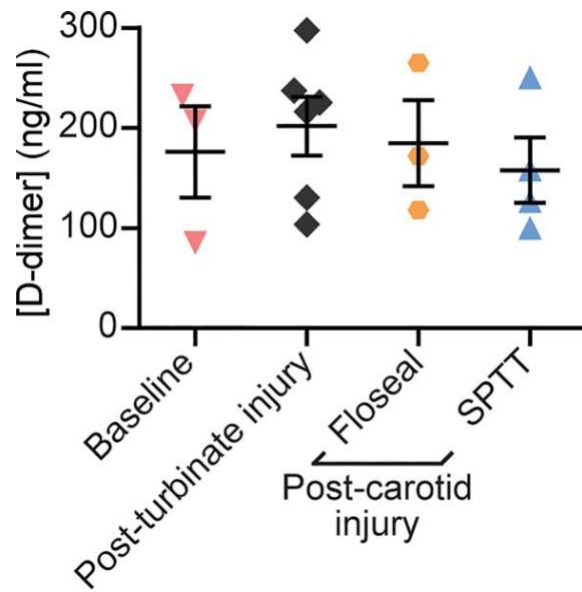


Fig. 4. D-dimer concentrations in venous blood samples at baseline, 2 days following turbinate injury, and 20 to 30 minutes following carotid injury and hemostatic treatment. Error bars represent standard error of the mean. $n = 3-6$. SPTT = self-propelling formulation of thrombin and tranexamic acid. [Color figure can be viewed in the online issue, which is available at www.laryngoscope.com.]

TABLE I.
Probability Values Comparing Pathologist Scores of Turbinate Biopsies at Baseline and 2 Days After Injury Was Treated.

	Baseline vs. Control	Baseline vs. SPTT	SPTT vs. Control
Inflammation	.06	.01	.74
Ulceration	.05	.06	.15
Infiltrate	.50	.35	.57
Inflammatory debris	.17	.15	.66

SPTT = self-propelling formulation of thrombin and tranexamic acid.

TABLE II.
The Proportion of Carotid Artery Injuries That Achieved Hemostasis Within 10 Minutes of Treatment.

	Dressing on Wound		Dressing Removed	
	SPTT	FLOSEAL	SPTT	FLOSEAL
Achieved hemostasis	100% (4/4)	25% (1/4)	25% (1/4)	25% (1/4)

Each agent was loaded onto gauze and compressed in the wound with 36 N of pressure. SPTT = self-propelling formulation of thrombin and tranexamic acid.