The Effect of The Mode of Reconstruction of The CBCT on The Orthodontic Diagnosis and Treatment Planning of Impacted Teeth

by

Sharifa Alebrahim

MSc., McGill University, 2014

BDS, King Saud University, 2007

A THESIS SUBMITTED IN PARTIAL FULFILLMENT OF

THE REQUIREMENTS FOR THE DEGREE OF

MASTER OF SCIENCE

in

THE FACULITY OF GRADUATE AND POSTDOCTORAL STUDIES

(Craniofacial Science)

THE UNIVERSITY OF BRITISH COLUMBIA

(Vancouver)

August 2019

The following individuals certify that they have read, and recommend to the Faculty of Graduate and Postdoctoral Studies for acceptance, the thesis entitled:

The Effect of The Mode of Reconstruction of The CBCT on The Orthodontic Diagnosis and Treatment Planning of Impacted Teeth

submitted by Sharifa Alebrahim in partial fulfillment of the requirements for

the degree of Master of Science

in Craniofacial Science

Examining Committee:

Dr. David MacDonald, Oral Biological & Medical Sciences

Supervisor

Dr. Edwin Yen, Oral Health Sciences

Supervisory Committee Member

Dr. Jolanta Aleksejuniene, Oral Health Sciences

Supervisory Committee Member

Dr. David Kennedy, Oral Health Sciences

External Examiner

Abstract

Introduction: Cone-beam computed tomography (CBCT) became commercially available 20 years ago and has been applied to almost every area of dental practice. This is due to its better spatial resolution, lower radiation dose, and smaller footprint than computed tomography (CT). However, the current CBCT unit still has much higher radiation dose than the standard conventional 2D dental imaging. Since there is no known safe lower radiation dose limit, radiation must be 'as-low-as-reasonably-achievable' (ALARA).

Aims: To profile the orthodontic patient pool since the inception of the Orthodontics Graduate Program at UBC to determine the number and the reason for whom CBCTs were prescribed. To compare the orthodontic diagnostic efficiency of two different 3D reconstruction methods of the CBCT images.

Methods: Ethics was approved for a retrospective review of orthodontic cases and for review by orthodontic instructors of randomized *multiplanar reformatting* (MPR) and curved CBCT image sets. 15 datasets of similar appearing impacted maxillary canines were reconstructed into MPR and curved screenshots. The instructors were asked to disclose their length of orthodontic service and prior experience reviewing CBCT datasets. They were asked to review the screenshots to determine factors that could affect treatment such as the position of the impacted canine, presence of root resorption and dilacerated roots.

Results: The review revealed 35 prescribed CBCTs that were mostly taken to investigate impacted teeth (29 cases). Of the 15 orthodontists, although the 6 females had on average 16

years of experience to their 9 male colleagues (on average of 26 years), this was not significant (P = 0.142). Furthermore, they all have some experience at reviewing MPR reconstructions which was almost identical for either sex, around 6 years; 2 males and 2 females had considerably more experience. All appeared more comfortable with the MPR rather than the curved reconstructions.

Conclusions: The number of prescribed CBCT images is low because the program policy follows the "Image Gently" guidelines and the ALARA principles. So far, orthodontists are more comfortable with the MPR rather than the more panoramic-like curved reconstruction. This simply may reflect the fact that the former is the default reconstruction for most CBCT units.

Lay Summary

A portion of the patients seeing orthodontists had teeth that did not erupt on time. When x-ray images are taken to see the location of these teeth, the orthodontist could see them diverted away from their correct location. Special 3D x-rays might be needed for some cases to see the exact location and condition of these teeth and if they eroded the roots of the neighboring teeth. This problem could be managed with exposing these teeth surgically then bringing them to the correct location by braces. This research aimed to measure how much these 3D x-rays are used in the Orthodontic Department at UBC and to measure the familiarity of the orthodontists with the use of these special x-rays. We found that the use of these special x-rays is very low in UBC to decrease the amount of radiations to the patients.

Preface

This retrospective research was conducted by me under the valuable guidance and support of my supervisor Dr. David MacDonald and my committee members Dr. Edwin H.K. Yen and Dr. Jolanta Aleksejuniene.

I collected and reviewed the data for Objective 1 and for Objective 2 of this study. I also obtained the images and conducted the surveys for Objective 3.

Objective 1 mainly was an audit of CBCT cases prescribed by the Orthodontic Department (UBC) and analysis of their parameters and the reasons for obtaining them.

Objective 2 included the orthodontics cases of the impacted teeth sent for CBCT examination. I reviewed all the cases from the electronic patient record in the study thoroughly. Dr. MacDonald provided me the guidance and direction in reviewing the images, whenever I was in doubt.

Objective 3 included taking representing images of each case with two 3D reconstruction methods and then conducting a survey to compare the effect of using either method. Dr. MacDonald and Dr. Yen provided me with their valuable guidance and support in constructing the method used.

All the statistical analysis was performed under the guidance of Dr. Aleksejuniene.

Ethics approval certificate was granted for this study, which was done in two parts, from UBC Clinic Research Ethics Board (Certificate number: H18-00271 and H18-01660).

Table of Contents

List of Tables

List of Figures

List of Abbreviations

2D: two dimensions

3D: three dimensions

AAO: American Association of Orthodontists

ALARA: as-low-as-reasonably-achievable

CBCT: Cone Beam Computed Tomography

CEJ: cementoenamel junction

CT: Computed Tomography

DICOM: Digital Imaging and Communications in Medicine

EPR: electronic patient record

FOV: field of view

HU: Hounsfield units

MDCT: multidetector CT

MPR: multiplaner reformatting

SD: standard deviation.

TMJ: temporomandibular joint

UBC: University of British Columbia

Acknowledgements

In The Name of God, The Most Beneficent, The Most Merciful

"This is by the Grace of my Lord - to test me whether I am grateful or ungrateful! And whoever is grateful, truly, his gratitude is for (the good of) his own self, and whoever is ungrateful, (he is ungrateful only for the loss of his own self). Certainly! My Lord is Rich (Free of all wants), Bountiful" [The Holy Quraan, An-Naml: 40]

I would like to express my deepest gratitude to my supervisor Dr. David MacDonald for his guidance, advice, support, and tremendous patience. His understanding, encouragement, motivation and opened heart added a great value to my graduate experience. I would like also to extend my appreciation to my committee members, Dr. Edwin H.K. Yen and Dr. Jolanta Aleksejuniene for their valuable assistance, advice and suggestions.

My special thanks and appreciation goes to all the Orthodontics Department's instructors who participated on the survey of this study.

The great thanks go to my parents for their support and endless love. Big thanks to all my big family for their great help in taking care of me and my baby girl during my study. Special thanks to my great friends who took care of me and my daughter when I needed them, Dr. Bingshuang Zou, Dr. Kiran Heda, Mrs. Michele Wong and Dr. Mahtab Nori. Finally, great thanks to my dear Feras whom I would not reach here without his love and tremendous support.

"And say, My Lord, increase my knowledge." [The Holy Quraan, Ta-ha: 114]

Dedication

To my precious daughter, Fatima, my dear husband, Feras, and my beloved family.

I am blessed with your unconditional love and continuous support.

Chapter 1: Introduction to Orthodontic Imaging

1.1 Radiology in Dentistry:

In order for orthodontists to diagnose their patients, they need radiographic imaging in addition to the clinical assessment. Over the years, different modalities were developed and used.

Dr. Otto Walkoff took the first intraoral radiographs (similar to bite wings) within weeks of the discovery of x-rays by Roentgen in 1895 [1]. In 1949, Paatero presented a new tomographic method and his aim was to capture a radiographic image of curved surfaces [2]. This was the start toward the panoramic radiography in dentistry in the 1960's. The panoramic radiography became popular throughout practices in the 1970s and 1980s. This technique gave an overview of both the teeth and the jaws in a single image [3, 4]. Then, it was followed by the use of extraoral imaging, such as cephalometric radiography.

20 years ago, first commercial CBCT was introduced in the clinical dental practice mainly for pre-implant planning then for orthodontics. However, it only gained popularity in the last few years [4]. Since then, it has been used in almost all disciplines in dentistry [5].

1.2 Conventional Radiography:

1.2.1 Limitations of Conventional Radiographs:

All intraoral and extraoral radiographic procedures are limited by the fact that they are two-dimensional (2D) representation of a three-dimensional (3D) anatomical structure. These limitations are magnification and distortion of the

image, and superimposition of the anatomical structures [3]. More details about these limitations are in the following:

Magnification of the image: The radiography depends on the projection of the x-ray beams from a source to pass through the object of interest until they reach the sensor. In the conventional radiography, the x-ray source is far from the object and the anatomic areas of interest are at different levels of distance from the film resulting in a distortion in the image itself. Moreover, there is no additional processing of the image by a computer to eliminate the distortion and thus the operator needs to take this distortion into account when viewing the image [6-8].

Superimposition of anatomy: The conventional radiography represents the 3D anatomy by 2D image. Therefore, when the x-ray beam passes through the region of interest, all the anatomy in between is superimposed in the sensor or film. Therefore, if there is any abnormality, it could be concealed by the other structures or it could appear as abnormality when it is not because of the superimposition [4, 8].

1.3 Advanced Imaging in Orthodontics:

1.3.1 Cone-Beam Computed Tomography:

Since the beginning of the 2000's, CBCT became one of the most attractive imaging modalities in dentistry due to its high-quality, thin-slice images and its ability to provide a 3D image of the structure of interest [3, 4].

The CBCT has a lower radiation dose than the fan-beam CT because its primary x-ray beam is cone-shaped. This cone-shaped beam is able to cover most of the area of interest thus the machine need only pass around the patient once to

acquire the images [4, 9]. Many modern units e.g. Carestream require only at least at a minimum a 180° arc of rotation. This reduces further the radiation dose.

In addition, the 3D images in the CBCT are reconstructed directly from cuberilles – cuboidal voxels - each with its own attenuation coefficient; whereas fan-beam CT - particularly the most modern multidetector CT (MDCT) - creates its own "cuberilles". It first creates voxels from which cuberilles secondary are created – unfortunately - all with the same attenuation coefficient of the same parent voxel. The voxels are cubes in the CBCT and this makes the images from the CBCT machine more superior since they have better spatial resolution in the Z plane (patient's long axis) –unlike the MDCT. The best MDCT can create small "cuberilles" by their 320 to 640 x-ray head detector pairs and impart an exceptional high radiation dose. Moreover, the voxel size of the CBCT is smaller 0.076 to 0.09 mm in comparison to 0.35 mm (the best of MDCT) [9-11].

The voxels of both the CT and the CBCT are assigned a grey value, which is represented by the darkness (attenuation coefficient) of the voxels as it appears in the screen. In the MDCT, this is called Hounsfield Units (HU), and it is explained by the relative x-ray absorption of a voxel. The higher HU value, the more x-ray absorbed by the material. The HU is used to classify the trabecular bone for implant placement and diagnose various lesions [12].

However, the CBCT grey value is not as precise and cannot be compared to the MDCT's HU due to the presence of excessive scattered radiation, the possibility of the influence of other structures outside the field of view (FOV), and the limitations of currently applied reconstruction algorithms [9, 12, 13].

After acquiring the images, the volume is exported as "Digital Imaging and Communications in Medicine" (DICOM) files to a third-party software where the operator could reformat and analyze the dataset [4].

1.3.1.1 The Advantage of Using CBCT in Orthodontics:

The introduction of CBCT in dentistry revolutionized the imaging techniques. With this technique, the imaging is not only used for diagnosis but also to plan and guide restorative and surgical procedures [3]. CBCT use in dentistry mostly resulted in improving the diagnosis by providing more valuable information with relatively low radiation dose and low cost [4]. This would lead to better diagnosis and treatment planning resulting in a better treatment outcome to the patients [4]. More details about the advantages of CBCT are in the following:

Requires a smaller footprint: the CBCT imaging machine requires a smaller physical space in compare to the MDCT [3]. All currently manufactured CBCT units occupy a space similar to that taken by the panoramic radiography unit and do not require strengthening of the floor [9].

Lower cost: the CBCT is less costly than the MDCT and it is easy to install and use. This made it available in many general dentists and specialists offices [3, 9, 11].

Rapid scan time: because of the shape of the beam (cone-shaped), the CBCT machine is able to acquire the image in a single rotation or less making the scanning time shorter thus decreasing the artifact caused by movement of the patient [3, 14].

Less radiation: large number of CBCT units allows the operator to choose a small FOV by the collimation of the CBCT primary x-ray beam directing the x-rays to the area of interest [3, 9]. Moreover, because of the cone-shaped beam, the machine is able to

produce a large volume of radiation in a single rotation or less than the MDCT, which needs many more rotations to cover the same volume of the patient [9, 11].

Better spatial resolution and image accuracy: the spatial resolution is the ability to detect two separate points with similar contrast factor that are very close to each other. Opposite to the MDCT, the CBCT has better spatial resolution making it able to differentiate the fine details between high-contrast structures such as bones and teeth [3, 9]. In addition, CBCT have a voxel resolution ranging from 0.076 mm to 0.4 mm which produce images with sharper edges and are precise enough to be used for measurement in all dimensions, such as implant site assessment and orthodontic analysis [3, 9, 14].

Elimination of structures superposition: since the CBCT allows the viewer to go through slices of the area of interest. The problem of superposition faced in the conventional radiography is eliminated making it more accurate to derive a diagnosis from these images [4].

1.3.1.2 The Disadvantages of Using CBCT in Orthodontics:

Although the introduction of CBCT in dentistry resulted in better images than the other imaging modalities, it is not perfect and it comes with several disadvantages.

High radiation dose: this imaging modality uses higher radiation doses than conventional radiography. Due to the availability of the CBCT machines in many dental offices, some use CBCTs as a tool to make panoramic reconstructions instead of the conventional panoramic machine. However, if that is the only use then it will increase the radiation dose unnecessarily to the patient [4, 11]. Ludlow *et al* in their meta-analysis found that the radiation dose of the CBCT varies based on the size of the FOV, the resolution and the type of the CBCT machine [15]. However, on average it is more like

10 times the radiation dose when compared to the conventional panoramic radiography [9, 15]. This can be reduced by selecting a small FOV and confining the area to the oral cavity putting it anatomically below the eyes and above the thyroid gland [9, 12].

Lower special resolution than conventional radiography: in comparison with intraoral radiography, the spatial resolution of the CBCT is poorer even with the elimination of the superimposition of the structures [9, 16].

Presence of metallic artifact: these artifacts are caused by restorations or implants. Although CBCT are less affected in creating artifacts in comparison to the MDCT, artifacts are still produced. An example is a black line around a large amalgam restoration resembling recurrent caries or a black line beside an endodontic fillings resembling vertical root fracture [4, 9].

High healthcare costs: since this technique needs its machine and a powerful computer to manipulate the data sets, the costs of acquiring and maintaining these will be passed to the patient [4, 11].

Need time and a powerful computer for data reconstruction: However, the read time varies ranging from 1-20 minutes. This depends on several factors such as the size of the FOV, resolution, and the reconstruction algorithm that is used [3].

Need more training to the dentist: training is needed to be able to use the machine and the software. This is especially important when using a large FOV and interpreting the results. Large FOV will extend to the cranial structures superiorly and to the neck structures inferiorly and from the facial structures anteriorly to the spinal area posteriorly. The viewer should be familiar with the various osseous or soft tissue abnormalities to detect them in these regions and that increases liability to the dentist [4, 9, 17].

1.3.1.3 The Use of CBCT in Orthodontics:

Due to the high accuracy of the CBCT images, the orthodontists are able to use them to measure and analyze the relations of the structures similar to what is performed in the cephalometric analysis; the new terminology for this is the 3D cephalometry. In addition, the 3D reconstruction could be printed using 3D printers and used as surgery simulation in orthognathic surgery cases and in craniofacial anomaly cases such as cleft lip and palate and facial cleft. The data could be also used to produce surgical guides for the surgery cases [3, 4, 9]. However, the routine use of the CBCT as equivalent to the lateral cephalometric radiography is discouraged as it gives the same information of the conventional lateral cephalometric radiograph but with higher radiation dose to the patient and requires a large FOV [9, 15, 18, 19]. Guidelines about the appropriate use of CBCT in the child dental patient as in “Image Gently” guidelines have been published [20].

One of the current uses of CBCT in orthodontics is the diagnosis of impacted teeth including their positions and the health of the structures around them. These teeth and their surroundings are examined for the presence of signs of infections, cysts, or tumors [3, 4, 19]. This last use of the CBCT is the scope of this study. The CBCT is usually prescribed to evaluate the impacted teeth: 1) when the parallax conventional radiography technique using conventional intra-oral radiographs was equivocal, 2) when there is a suspected resorption of the adjacent teeth, 3) when there is a need to identify the best path for orthodontic movement [6, 9, 11, 19, 21].

1.3.1.4 The CBCT Image Reconstruction:

After acquiring the images by the CBCT machine, the data must be processed or reconstructed. This process consists of several steps and complicated techniques and thus requires a complex computerized processing [3]. To further explain the reconstruction process, we can divide it into two steps:

Step One: The Acquisition:

When the images are acquired, several elements play a role. These are the varying physical properties of the photodiodes and the variations in the conversion efficiency of the scintillator layer. Moreover, there are inherent pixel imperfections and defects similar to what is seen in the CT. Moreover, the CBCT images have high level of noise sometimes from the structures adjacent to the field of interest. There is also the presence of scattered radiation that could negatively affect the image quality. Moreover, if there is metal object in the field, that could result on the formation of an artifact in the field [3, 9]. Because of these elements, the acquired images will require “corrections” before the reconstruction process [3]. This correction might include the use of different algorithms – and thereafter different reconstruction method - to achieve the best possible outcome [9].

Step Two: The Reconstruction:

After correcting the images in the previous step, the program stitch them to each other making a “sinogram"; i.e. an image relating the rows of each projection image. Then, an algorithm filters are applied to the sinograms making them a 2D CT slice. Then, the software combines all the slices together to make the 3D volume [3].

1.3.1.5 CBCT 3D Reconstruction Modes:

One of the most important advantages of CBCT is that the images obtained in 2D can be reconstructed into 3D images. This enables the viewer to see the full anatomy of the area of interest and appreciate how the adjacent structures relate to each other.

There are several reconstruction methods developed over the years, and they differ based on the type of algorithm used by each one. The goal is to improve the imaging techniques to reach a high level that could be compared with the level reached by the best MDCT. This is mostly done by improving the software technology [10]. The concept behind the image reconstruction could be summarized in three categories: filtered back projection, algebraic reconstruction techniques, and statistical methods [12].

Beside the use of algorithms to get the 3D reconstructed image, several algorithms were developed to improve the image quality and reduce the artifacts developed during the imaging. These artifacts are caused by the presence of dental restoration, crowns and implants in the patient oral cavity that result in beam hardening and scattered radiation [9, 22, 23].

Several reconstruction methods were developed as in the following:

1. **Multiplanar reformation (MPR):** this is displayed in three planes of space; which are axial, sagittal, and coronal [9]. An example of this can be found in **Figure 19.**
2. **Curved:** The reconstruction of the 3D CBCT is made following the line of the arch. The three planes used are: panoramic, axial and transaxial [3, 9, 14, 24]. An example of this can be found in **Figure 20.**

1.3.1.6 Why Do We Need Different Reconstruction Modes?

Clinicians need to have the optimal view of the clinical feature in question to provide the best possible treatment. However, during the various steps that go into the process of obtaining the CBCT, artifacts occur that could - in extreme cases - render the image undiagnostic. Barrett *et al* defined the ***artifact*** as "any systematic discrepancy between the CT numbers in the reconstructed image and the true attenuation coefficients of the object" [14]. The artifacts are divided into four different groups:

1. Physics-based: occur in the acquisition process.
2. Patient-based: occur due to patient movement or due to the presence of metallic materials in the x-ray path.
3. Scanner-based: occur due to an error in the scanner function.
4. Artifacts occurring due to the image reconstruction process [14, 25].

In order to decrease the effect of these artifacts, several methods were developed to use computarized algorithms designed to reduce the artifacts' effect [6]. However, these algorithms are not optimal or error-free. For this reason, in this project, we used two different reconstruction methods to get as much information from each image as possible.

1.4 Comparison Between The CBCT and The Conventional Radiography:

Article	Comparison	No. of cases	No. of participants	Conclusion
Bjerklin et al, 2008 [26]	Pano + intraoral + clinical status Vs. Medical- CT	3 cases	157 orthodontists	1. Variations in the treatment plan of eruption disturbances of maxillary canines. 2. Lack of consensus can have negative implications for patients.
Botticelli et al, 2010 [27]	2D (pano, L. Ceph, and PA) Vs. 3D (CBCT)	27 cases	8 dentists	1. Difference in the localization of the impacted canines. 2. The increased precision in the localization obtained with CBCT resulted in a difference in diagnosis and treatment planning.
Haney et al, 2010 [6]	2D (pano, occ, and 2 PA) Vs. 3D (CBCT).	18 cases	4 orthodontists 3 surgeons	2D and 3D images of impacted maxillary canines can produce different diagnoses and treatment plans.
Wriedt et al, 2012 [28]	Pano + study casts Vs. CBCT+ study casts.	21 cases	26 dentists of various specialities	Small volume CBCT may be need in these cases: 1. panoramic X-ray canine inclination > 30° 2. Suspected root resorption of adjacent teeth. 3. The canine apex is not clear in the panoramic X-ray (i.e. dilaceration)
Lai et al, 2013 [29]	Pano (2D) Vs. CBCT (3D).	60 cases	5 orthodontists 5 oral surgeon	1. Orthodontists more likely to diagnose the labiopalatal position of impacted canines using panoramic views only. 2. Oral surgeons more often indicated the need for further 3D imaging.
Eslami et al, 2017 [8]	CBCT Vs. conventional radiography	No data available. This is a review article (no meta analysis due to heterogeneity).		1. Different information obtained that might affect treatment planning. 2. "Although there is still a lack of strong evidence, CBCT is more effective than conventional radiography in evaluating cases that are difficult to diagnose".

Table 1: Current available literature comparing the conventional radiography with the CBCT. **Pano:** *panoramic radiograph*, **L Ceph:** *lateral cephalometric radiograph*, **PA:** *periapical radiograph*, **Occ:** *occlusal radiograph*.

Chapter 2: Introduction to Orthodontic Diagnosis and Treatment of Impacted Teeth

2.1 Diagnosis of Orthodontic Problems:

Obtaining the correct diagnosis of an orthodontic patient should result in reaching the correct treatment outcome. This could be achieved by examining the patient and collecting the appropriate data. Then, the collected data is combined together to formulate a problem list and a final diagnosis [11].

2.1.1 Questionnaire and Interview:

2.1.1.1 Establish The Patient's Chief Concern:

This includes the major reason why the patient or the parents are seeking consultation and treatment**.** This could include the concern about impaired dentofacial appearance, impaired function, and impaired oral health [11].

2.1.1.2 Medical and Dental History:

The orthodontist needs to ask questions searching for any abnormality in the patient's development, the long-term use of medications, and if the patient had a history of previous serious illness such as cancer or bone metabolic disease [11].

2.1.1.3 Physical Growth Evaluation:

The orthodontist needs to evaluate whether the patient is going into growth spurt, in the middle of the spurt or already finished growing. During this evaluation, the doctor will decide what kind of treatment can be used in this patient [11].

2.1.1.4 Social and Behavioral Evaluation:

The orthodontist needs to evaluate the motivation for the treatment to determine if the patient will be cooperating with the instructions or not during the course of the

treatment. Moreover, the clinician needs to evaluate the parenting style in children to determine how much they can enforce the treatment instructions at home [11].

2.1.2 Clinical Evaluation:

The evaluation should include three different categories:

2.1.2.1 Oral Health:

The oral cavity includes both the soft and hard tissues and any active disease needs to be either eliminated or controlled. In the hard tissue evaluation, the dentist needs to examine in detail the health of the tissues. In addition to that, the number of teeth should be noted to detect any supernumeraries, missing or impacted teeth – this is the scope of this study. During the soft tissue evaluation, special emphasis should be put on the status and health of the gingival tissues and the pulp pathologies. This evaluation could be done both clinically and radiographically [11]. In this study, we are evaluating the further need of radiography in diagnosing and treatment planning of impacted teeth cases.

2.1.2.2 Jaw and Occlusal Function:

In order to evaluate the oral function, the orthodontist needs to evaluate four aspects: mastication, speech, presence or absence of sleep apnea related to mandibular deficiency and to the possibility of temporomandibular joint (TMJ) problems [11].

2.1.2.3 Facial and Dental Appearance:

In order to have a correct diagnosis and therefore an appropriate treatment plan, facial and dental appearance should be evaluated through examining these structures systematically. The clinician needs to evaluate the following:

1. Facial proportions in all three planes of space. Examples of that include the assessment of facial asymmetry and upper or lower jaws deficiency.
2. The relation between the dentition and the face. Examples include the display of the teeth at rest, the smile and the size of the buccal corridors.
3. The relationship between the teeth. Examples of this include tooth proportions in height or width and gingival shape or contour [11].

2.1.3 Diagnostic Records:

The reason for taking diagnostic records is to have a record of the starting point for treatment, and to collect more information to support the clinical examination.

The current recommended records in orthodontics include:

1. **Facial photographs:** they have been standard records for diagnosis. The orthodontists usually take a minimum of three photographs, frontal at rest, frontal smile, and profile at rest.
2. **Dental casts:** could be physical or digital casts and are used to evaluate the symmetry of the arch, the alignment of the teeth, and the teeth size analysis.
3. **Panoramic radiograph:** to examine the teeth, jaw bones, and the TMJ. From this radiograph the clinician will evaluate if extra information is needed and if so, what kind of record is required. A condition that commonly requires more radiographs is the presence of impacted teeth. If the position of the tooth is difficult to specify, or if there is a suspected resorption of the adjacent teeth, it is recommended to use 3D method to evaluate i.e. CBCT.
4. **Cephalometric radiograph:** the lateral cephalometric radiographs are always indicated in comprehensive orthodontic treatment cases. The cephalometric radiograph evaluates

the skeletal relation of the jaws together and to the base of the skull, the growth pattern and the effect achieved by the orthodontic treatment. Posterior-anterior cephalometric radiographs are indicated in cases where there is facial asymmetry [11].

2.2 The Impacted Teeth:

Impaction of a tooth is described as "A condition that describes the total or partial lack of eruption of a tooth well after the normal age for eruption" (American Association of Orthodontists (AAO) Glossary 2012). In some cases, teeth become impacted or unerupted and their diagnosis and treatment require the cooperation from the general practitioner, the pediatric dentist, the oral surgeon, and the periodontist, besides the orthodontist [6, 30]. These teeth are treated by either exposure to recover, extraction or no treatment. The treatment decision depends on several factors that include the tooth type, location of the tooth, prognosis of the impacted tooth or adjacent teeth, the ease of surgery to expose or extract, the type of malocclusion, and the possible surgical complications [6].

2.2.1 The Maxillary Canine Impaction:

The incidence of maxillary canine impaction ranges from 0.92% to 3% and of those 8% have bilateral impaction. After the third molar, maxillary canine is the most commonly impacted tooth. It is twice as common in females compared to males [6, 30-32]. The palatally impacted canines represent 85% of the impacted maxillary canines [6].

2.3 Causes of Impaction:

The maxillary canine impaction could occur due to several local causes. One or more of the following causes could result in the impaction:

1. Tooth size-arch length discrepancies.
2. Early loss or retention of the deciduous canine.

3. Abnormal location of the tooth bud itself.
4. Cases with alveolar cleft.
5. Ankylosis of the impacted tooth.
6. The presence of pathology such as a cyst or neoplasm in the eruption path.
7. The presence of dilaceration of the impacted tooth root.
8. No apparent possible cause [30].

Around 85% of the palatally impacted maxillary canines tend to have enough space to erupt in the dental arch. However, they become impacted palatally and they stay impacted most of the time. Not erupting into the palate spontaneously could be attributed to the presence of thick cortical bone and thick mucosa. These teeth are commonly positioned oblique or horizontal [30]. Two theories have been suggested as an etiology for the canine impaction. They are the guidance theory and the genetic theory. Guidance theory suggests that the canine needs the roots of the adjacent teeth to guide it to the correct position; whereas the genetic theory suggests that there is a genetic factor behind the impaction and the patient is born with it [32]. Applying the guidance theory, Bertl *et al* found an association between the reduction in the length and the volume of the root of the adjacent maxillary lateral incisor and the impaction of the canine palatally. Despite this, they could not comment on if it is the cause of this problem or not [31]. In addition, it was found that the patients with palatally impacted canines have smaller teeth compared to non impacted cases [32].

Around 83% of labially impacted maxillary canine cases have arch length deficiency. However, they could erupt without help high on the sulcus. These teeth are often positioned on a favorable vertical direction, but the difficulty in these cases is to manage the soft and hard tissue around them when trying to align because they are in aesthetic area [30].

2.4 Diagnostic Imaging of Impacted Teeth:

2.4.1 Conventional:

In 1987 study, Ericson *et al* found that the clinicians are able to locate accurately the impacted canines with periapical films in 92% of the cases. Lateral incisors can be projected free from the canines using intraoral radiographs only in 55% of the cases [33]. Using conventional radiographs, they also found that they were able to detect root resorption in the incisors in 12% of the impacted canine cases [34, 35]. Conventional radiographs cannot diagnose the resorption in the roots of the maxillary incisors when it happens in the buccal or lingual aspect of the root [33, 34, 36, 37].

2.4.2 3D Imaging:

Before the invention of the CBCT, CT was used as a 3D imaging technique for the impacted teeth cases. Ericson *et al* extracted the resorbed incisors after taking a CT image. They found that the CT was the most effective technique to check the presence of root resorption when compared with intraoral films [35]. When CT was used, the detection of resorption increased by 53% for the lateral incisors compared to conventional radiography. They also found that it is the best to assess the position of the impacted teeth and their relationship to adjacent structures [34].

With the advances in radiology and the current introduction of CBCT in the field of orthodontics, new challenges came in the picture with the 3D. The research is still in the process of catching-up with this rapid development. New standards and guidelines are required to embrace this new way of diagnosing the impacted teeth. For example, to localize the impacted tooth in the 3D images, San Martín *et al* developed a new system to localize the impacted tooth in all the three planes of space [38].

2.5 Management of Impacted Teeth:

When it comes to the treatment of impacted maxillary canines, the treatment depends on the timing (the age of the patient and stage of tooth development at initial examination), the potential for spontaneous eruption, and whether there is enough space in the arch. If it is detected early, then extracting the deciduous canine and making a space in the arch might allow the tooth to correct its position and erupt in the arch [39]. If the tooth does not correct its position after the extraction of the primary tooth or if the patient already passed the stage where the tooth can erupt spontaneously, the management of the impacted tooth starts by exposing the tooth surgically by opening the tissues and removing only enough bone to place an attachment. During the bone removal, the clinician performing the surgery should not expose the cementoenamel junction (CEJ) intentionally [30].

2.5.1 Management of Palatally Impacted Teeth:

Different methods have been developed and the two most common methods are:

2.5.1.1 Surgical Exposure, Allowing Natural Eruption:

This method is mainly used when the canine has normal position and normal inclination. After the exposure, the canine eruption should be monitored by using the adjacent structures as references in panoramic radiographs. The eruption could take from six months up to one year then orthodontic treatment can be started. However, this method could be slow since it depends on the slow and spontaneous eruption which increases the treatment duration and the orthodontist cannot change the path of eruption [30].

2.5.1.2 Surgical Exposure With Placement of an Auxiliary Attachment:

In this technique, there is no waiting for the tooth to erupt spontaneously and instead an attachment is bonded to the tooth during the exposure to aid in moving the tooth orthodontically. The bonding of the attachment can wait until the surgical site heals for around 3-8 weeks. The other approach is to bond the attachment during the surgery. After uncovering the palatally impacted tooth and bonding an attachment, the tissue could be left open or the tissue could be closed over the attachment. The advantages of opening the site is the orthodontist can see the tooth movement and adjust the force direction accordingly [30].

2.5.2 Management of Labially Impacted Canines:

Those teeth are usually located in a favorable vertical position but high in the alveolar bone and sometimes above the level of attached gingiva. Without the attached gingiva, the exposure of the tooth could cause inflammation of the periodontal tissues and loss of alveolar bone [30].

In the cases where there is no band of attached gingiva around the tooth, the surgical procedure should include providing the impacted tooth with a band of attached gingiva through the use of partial-thickness apically or laterally repositioned flap or free gingival graft. The orthodontic attachment could be placed immediately after the surgery or the clinician could wait for 7-10 days [30].

2.6 Resorption of Adjacent Teeth:

Ericson *et al*, in their 1987 article, estimated that the resorption of the lateral incisors, in the impacted teeth cases, by around 12% when intraoral radiographs were used [33, 40]. However, after the introduction of the 3D imaging, the root resorption was detected in 38% of

lateral incisors and 9% of central incisors [34, 40]. The resorption was found to reach the pulp in 60% of the lateral incisors and 43% of the central incisors [30, 34]. The most common areas for resorption were found to be in the apical and middle thirds in 64% of the lateral incisors and 57% of the centrals [34]. The resorption process is very rapid, and there is an urgent need to start the treatment immediately to stop the destruction. When the impacted tooth is moved away from the resorbed root, the resorption process stops and the tooth can be moved orthodontically without added risk of further resorption. Long term observation of the severely resorbed roots showed that they did not have increased mobility or discoloration, and they did not require root canal treatment [40].

Chapter 3: Objectives

Objective 1: To profile the orthodontic patient pool since the inception of the Orthodontics Graduate Program at UBC to determine:

1. Sex and age of patients.
2. Reasons for prescribing CBCT.
3. Type of impacted tooth for which CBCT was prescribed.
4. The prescribed CBCT parameters (FOV).

Objective 2: To compare how the orthodontic diagnosis of impacted teeth changes when conventional 2D radiographs (periapical, panoramic and lateral cephalograms) are supplemented by CBCT.

Objective 3: To compare the diagnostic efficiency of two different 3D reconstruction methods of the CBCT images: MPR (the standard default reconstruction) and curved (following the line of the arch and generally used by implantologists).

Chapter 4: Hypotheses

Hypothesis 1:

Can CBCT change the diagnosis and treatment plan previously determined by conventional 2D radiographs in impacted teeth?

Null Hypothesis- CBCT examination cannot change the diagnosis and treatment plan previously determined by conventional 2D radiographs in impacted teeth.

Alternate hypothesis- CBCT examination can change the diagnosis and treatment plan previously determined by conventional 2D radiographs in impacted teeth.

Hypothesis 2:

Can the 3D reconstruction method change the diagnosis of impacted teeth?

Null Hypothesis- the 3D reconstruction method does not change the diagnosis of impacted teeth.

Alternate hypothesis- the 3D reconstruction method changes the diagnosis of impacted teeth.

Chapter 5: Objective 1 Materials, Method and Results

5.1 Materials and Method:

5.1.1 The CBCT:

The Oral Health Centre's database was searched by extracting the data from the *electronic patient record* (EPR; Romexis software). The data in the patients' records were entered by the graduate students during the course of the treatment. The data collected for this study were from September 1, 2010 until January 26, 2018 for all the patients who were investigated by CBCT by the Graduate Orthodontic Program. The CBCTs were prescribed by the graduate students and approved by the supervising credentialed orthodontists.

5.1.2 Method:

1. Obtain ethics approval (**Ethics Certificate: H18-00271).**
2. Sample collection was performed by reviewing the Oral Health Centre's database from September 1, 2010 until January 26, 2018 for all the patients who were investigated by CBCT by the Graduate Orthodontic Program. The CBCTs were prescribed by the graduate students and approved by the supervising already credentialed orthodontists teaching at UBC.
3. Determine the patients, sex and age to whom CBCT was prescribed.
4. Identify the reasons for the CBCT prescription by the Graduate Orthodontic Program.
5. Identify the exposure parameters (e.g. FOV) for the CBCT prescribed by the Graduate Orthodontic Program.

5.2 Results:

A total number of 1691 patients attended the Graduate Orthodontic Program. **Table 2** represents the specific numbers and sexes of these patients.

	Female	Male	Total
No. of patients	979	712	1691

Table 2: The number of patients treated in the UBC Graduate Orthodontic Program.

After analysis of the patients' information, we found that the majority of the Orthodontics Department patients' ages are between 11-30 years of age. **Figure 1** shows the distribution of sexes according to the decades of age for patients treated in UBC Graduate Orthodontic Program.

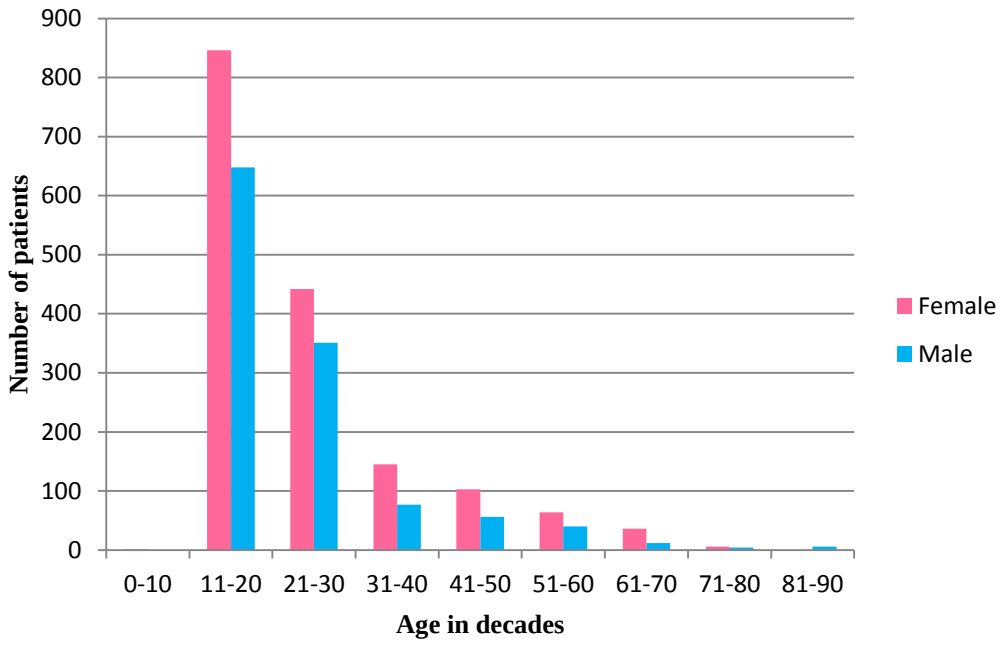

Figure 1: Chart representing the ages of the patients per year divided according to their sexes.

Out of the 1691 patients, only 35 cases (11 females: 24 males) were prescribed CBCT radiography by the department of orthodontics. **Table 3** shows the number of CBCT prescribed cases divided by the reason of prescription from September 1, 2010 up to January 26, 2018.

Most of the CBCT cases prescribed by the Graduate Orthodontics Program at UBC were to evaluate impacted teeth. Out of 35 CBCT cases of impacted teeth, there are 20 impacted canine cases. **Table 4** shows the types of impacted teeth that were found in the CBCT sample from the Graduate Orthodontics Program at UBC from September 1, 2010 up to January 26, 2018.

Reasons for prescription	Number of patients
Evaluate impacted teeth	29
Periapical lesions	2
Orthognathic surgery	1
Other	3
Total	35

Table 3: The number of prescribed CBCT cases divided by the reasons of prescription from the Graduate Orthodontics Program at UBC (September 1, 2010 up to January 26, 2018).

Type of Impacted Tooth	Number of patients	
	Maxillary	Mandibular
Central Incisor	3	0
Canine	19	1
Premolar	2	0
Molar	1	3
Total	25	4

Table 4: The types of impacted CBCT cases from the Graduate Orthodontics Program at UBC (September 1, 2010 up to January 26, 2018).

Further analysis of the CBCT data showed that most of the CBCT images were obtained with a small FOV (5 x 5 cm) just to evaluate the impacted tooth and the tissues surrounding it. If there was a bilateral impaction, a larger FOV was used to include both teeth (5 x 10 cm). **Table 5** shows the number of cases divided by the size of the FOV.

Field of View (FOV) (in cm)	Number of patients
5 x 5	30
10 x 5	3
8 x 8	1
10 x 10	1
Total	**35**

Table 5: The Field of View (FOV) size used by the Graduate Orthodontics Program (September 1, 2010 up to January 26, 2018).

Chapter 6: Objective 2 Materials, Method and Results

6.1 Method:

1. Obtained a diagnosis from each case conventional radiographs (periapical radiographs -if available-, panoramic radiograph and lateral cephalogram) using the below criteria for the impacted teeth and the surrounding structures. Then, any extra information obtained from the CBCT's two reconstructions was added. The difficult cases were checked and diagnosed by both me and Dr. MacDonald.
2. Obtained a diagnosis from each case from the MPR and curved CBCT reconstructions separately using the below criteria for the impacted teeth and the surrounding structures. Then, the difficult cases were checked and diagnosed by both me and Dr. MacDonald. The information obtained were compared together.
3. For the above 1 + 2 the following criteria were analyzed:
    a. Position of the impacted tooth in buccolingual dimension.
    b. Vertical level of impaction in relation to the adjacent teeth.
    c. Presence of root resorption on the adjacent tooth.
    d. Amount of adjacent tooth root resorption.
    e. Presence of dilacerations of the impacted tooth.

6.2 Results:

Comparing the cases where CBCTs were prescribed to supplement the conventional radiography, the orthodontists prescribed CBCT for the following reasons:

1. There was a visible root resorption on the adjacent tooth and they wanted to examine the extent of the resorption and the prognosis of the resorbed tooth.

2. They suspected a resorption in the adjacent tooth and the conventional radiography failed to provide a definitive diagnosis.
3. There was a possible ankylosis of an impacted tooth they wanted to confirm.
4. The root apex of the impacted tooth was not clear in the conventional radiography due to its position in an area where there is superimposition of several structures (e.g. root apex at the level of the hard palate and the maxillary sinus floor) which obscured a possible dilaceration.
5. There is difficulty in diagnosing the exact position of the impacted tooth in relation to the adjacent structures. This needed to be precisely determined in order to decide on the best orthodontic path to move the tooth into the arch.
6. The impacted tooth appears very close to vital structures in the conventional radiography and they wanted to determine the precise relationship.
7. There was a large bone defect suspected around the impacted tooth. The extent of this defect was needed to determine where and how much bone graft is needed prior to orthodontic tooth movement.

The comparison between the information given by the conventional radiographs and the information given by the additional CBCT showed that, in 14 out of 29 impacted teeth cases, the CBCT gave us more information in the following categories:

1. **<u>Resorption of the adjacent teeth roots:</u>**

   The conventional radiography is a 2D presentation of a 3D structure. For this reason, if the resorption occurred at the buccal or lingual surfaces of the tooth, it will not be detected. **Figure 2** shows an example of a case where the resorption was detectable in the buccal surface of the root when CBCT was used.

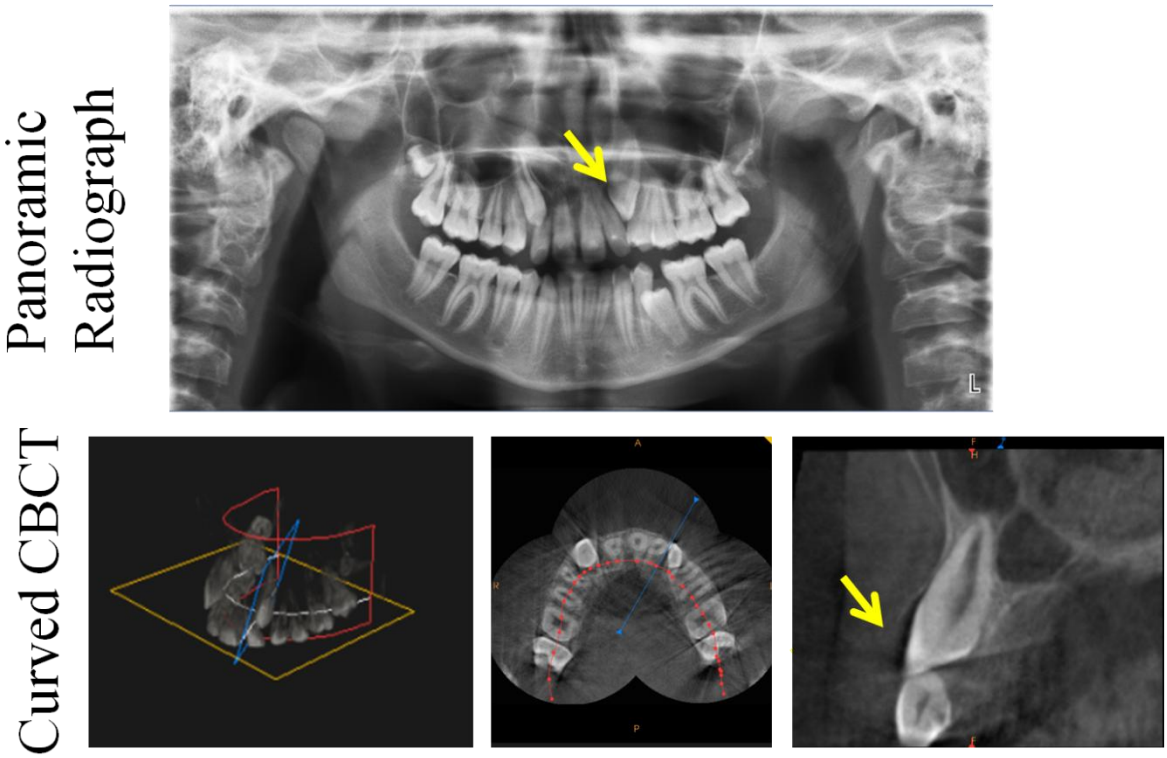

Figure 2: The curved CBCT reconstruction shows the presence of root resorption in the adjacent lateral incisor. The yellow arrow in the panoramic radiograph shows that it was not detectable in the conventional radiography.

2. **<u>The presence of internal resorption in the impacted tooth:</u>**

The conventional radiography has the disadvantage of having all the structures superimposed above each other. On the other hand, the CBCT reconstructions give us the ability to look through the whole 3D volume of the area of interest. Thus, CBCT enables us to detect any abnormality in a specific structure – in this case internal root resorption. **Figure 3** shows the presence of internal resorption in the upper right canine that is only visible on the CBCT.

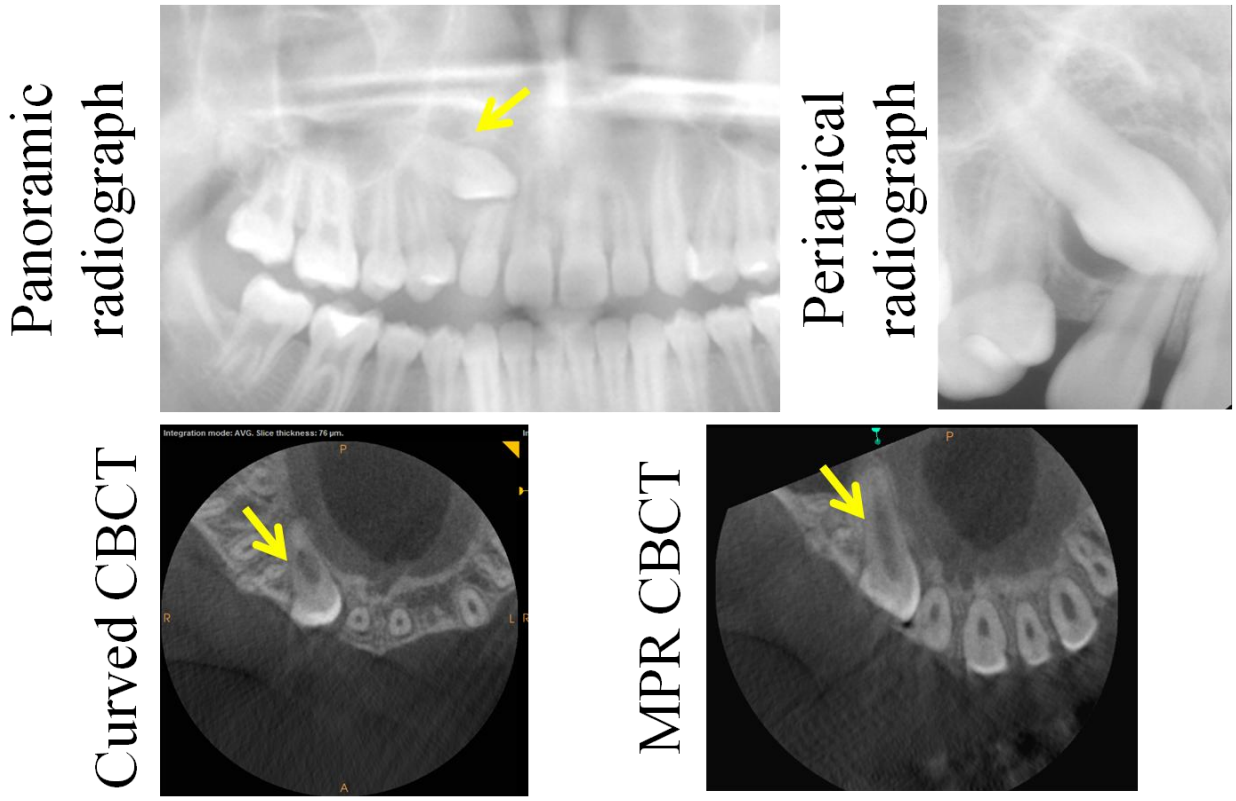

Figure 3: Both the curved and the MPR CBCT reconstructions show the presence of internal root resorption in the impacted right canine. This information was masked in the conventional radiography due to the angulation and the structural superimposition that is an inherited feature of this technique.

3. **<u>Ankylosis of the impacted tooth:</u>**

The conventional radiography shows that some teeth did not erupt as expected. However, since it represents a 2D image of the 3D structure, any ankylosed point in the areas not seen in the 2D representation will not be detected. Therefore, looking at the root from all dimensions in the CBCT gives a better chance to detect any ankylosed area. In such cases, the high spatial resolution image of the CBCT allows the viewer to see all the fine detail and if there is only one point contact it will be visible. In contrast, low resolution images will be undiagnostic in such a situation. **Figure 4** shows an ankylosed lower molar in the CBCT.

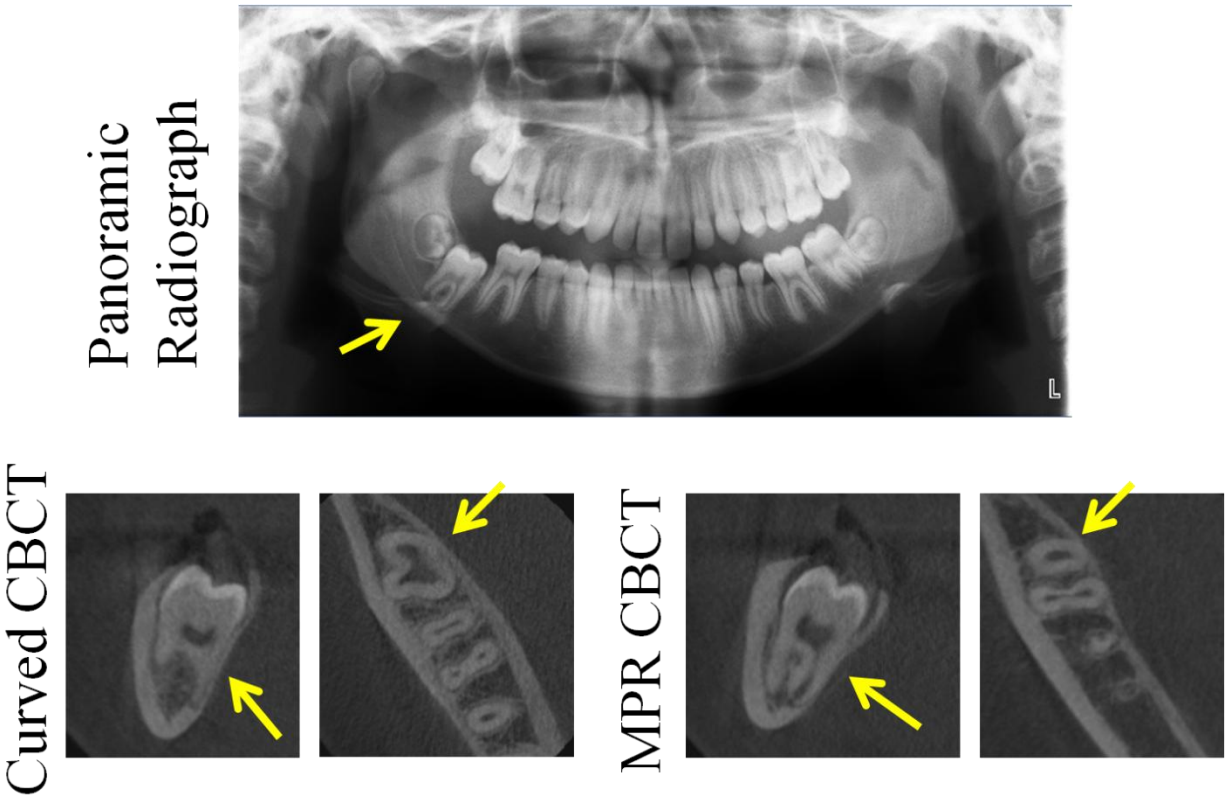

Figure 4: The panoramic radiograph shows that the lower right second molar is delayed in eruption compared to the contralateral side, but it is not clear if it is ankylosed. Both the curved and the MPR CBCT reconstructions show ankylosis (no periodontal ligament space and the bone is fused with the tooth root).

4. <u>Root dilacerations of the impacted tooth:</u>

The presence of a dilaceration pointing toward the mesial or distal side of the root is easier to detect in the conventional radiography. However, if the dilaceration is toward the buccal or lingual side, then it will not be easy to detect by the conventional 2D radiographs due to the superimposition by the root itself. The CBCT gives us the ability to examine the root from all sides allowing us to detect any dilacerations. **Figure 5** shows the dilacerations in the apical third of the canines.

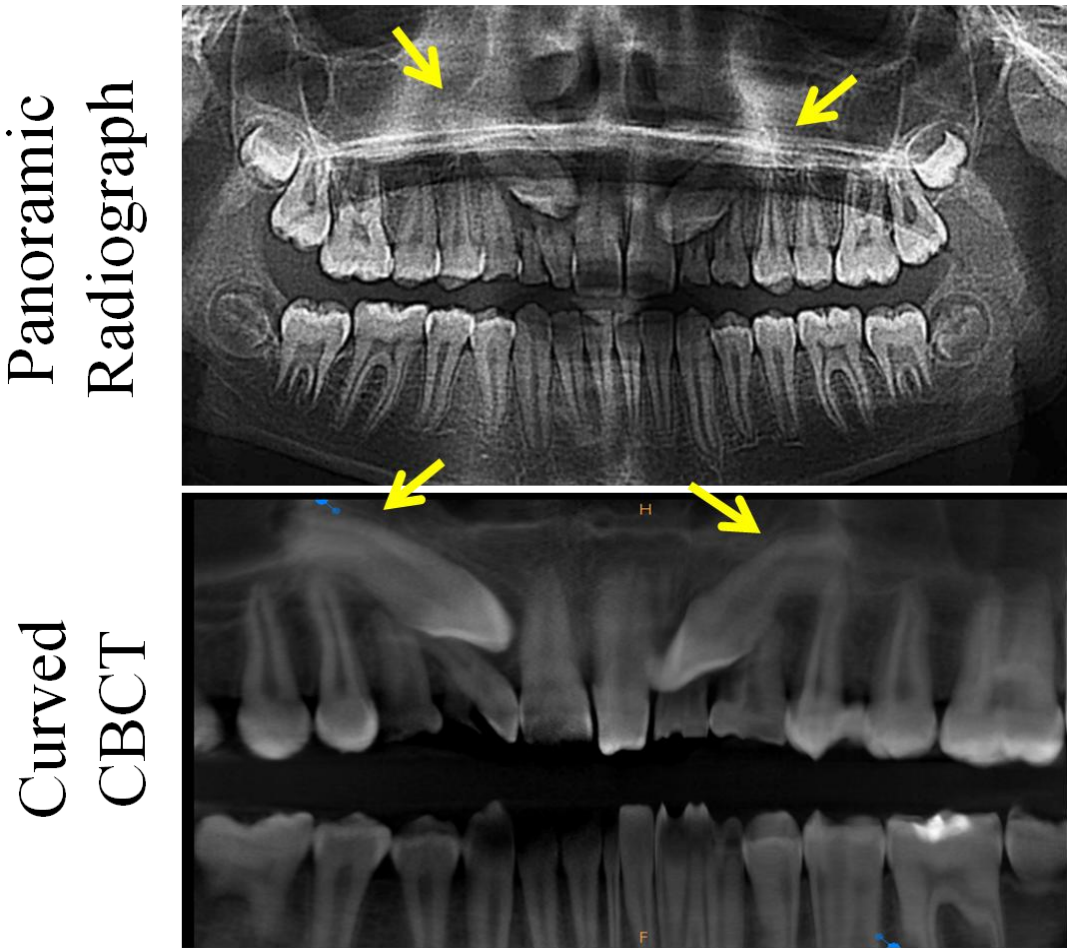

Figure 5: Although these two images appear to be the same, the path of the reconstruction of the CBCT allows us to have a curved plane. Thus, we can see the dilacerations at the apical third of the canines' roots without the superimposition in the panoramic radiograph.

5. **<u>The presence of roots in the maxillary sinus:</u>**

In the impacted tooth cases, there are three treatment options available. Those include extracting the impacted tooth, exposing the tooth and moving it into the arch orthodontically, and the last one is no treatment. Most of the impacted teeth are maxillary canines and due to their long roots and ectopic position, their roots could be in the maxillary sinus. Extracting the teeth or exposing them could result in opening a connection between the oral cavity and the sinus cavity which could lead to the formation

of oro-antral fistula. Failing to recognize the presence of fistula might result in the spread of infection into the sinus. For this reason, it is critical to know the exact position of the impacted tooth and plan the treatment accordingly. **Figure 6** shows the presence of the root tip of the maxillary canine in the maxillary sinus.

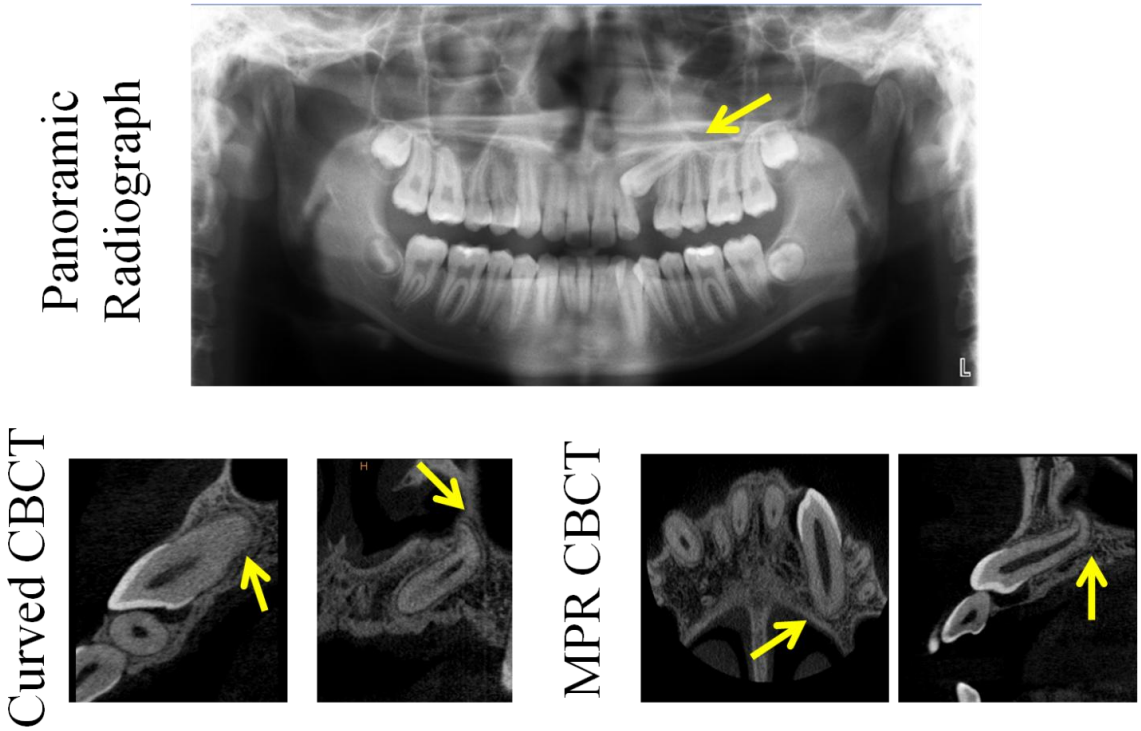

Figure 6: In the conventional radiograph, it appears that there is a bone surface separating the impacted canine from the maxillary sinus. However, when the CBCT volume was analyzed, it showed that its root is dilacerated and it is in the maxillary sinus.

6. **<u>The extension of bone defects in 3D:</u>**

As disclosed earlier, the conventional radiograph is a 2D representation of a 3D structure. Therefore, the borders of any bone defect will be concealed by the superimposition of the structures. **Figure 7** shows the extent of the bone defect in the CBCT.

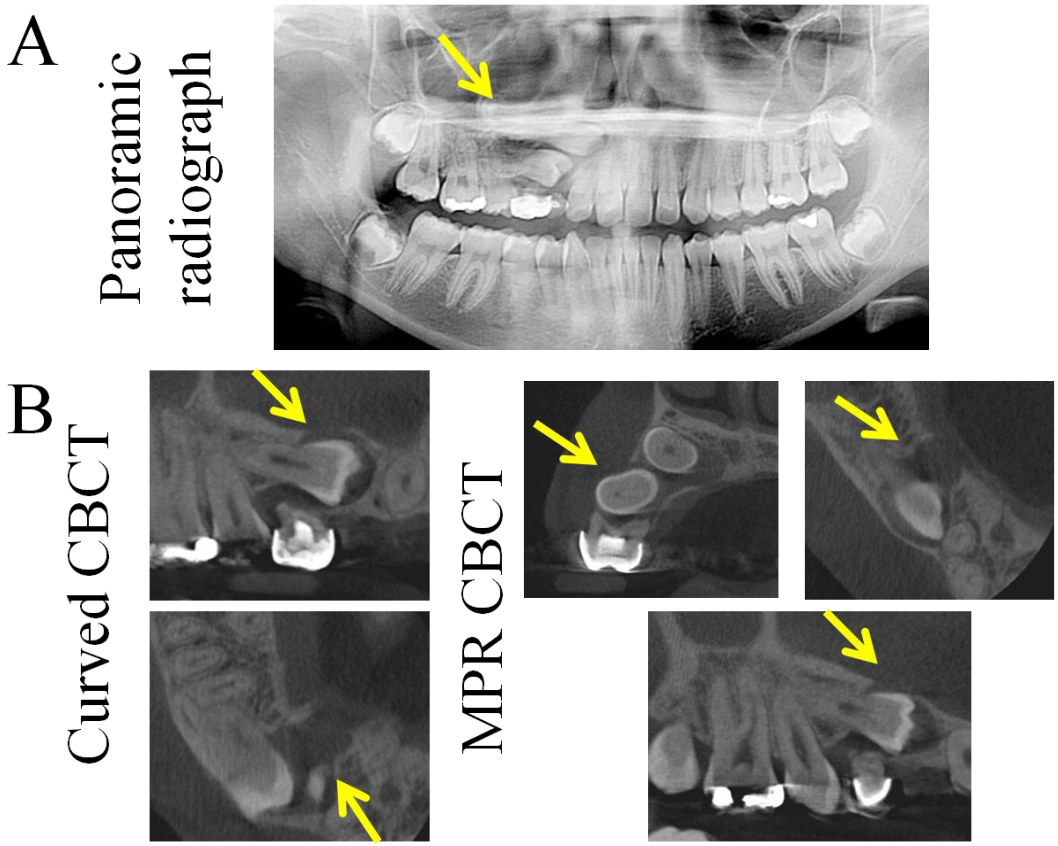

Figure 7: A: The panoramic radiograph shows that there is a bony defect around the impacted teeth. However, because of the superimposition of the area by the palatine bone both above and behind the teeth, the limits of the defect cannot be determined. **B:** The CBCT reconstructions show that the defect extends to include the buccal and lingual bones beside the floor of the sinus.

7. <u>Root fusion:</u>

In conventional radiography, especially the panoramic radiograph, the images of the teeth overlap each other due to their superimposition. This superimposition of the teeth may mask any fusion between them. On the contrary, the CBCT gives the orthodontist the ability to go through different slices of the volume and thus facilitates the detection of such fusion. **Figure 8** shows the fusion between the upper maxillary molars clear in the CBCT. Moreover, it shows also the extent of the cervical resorption of the fused first molar.

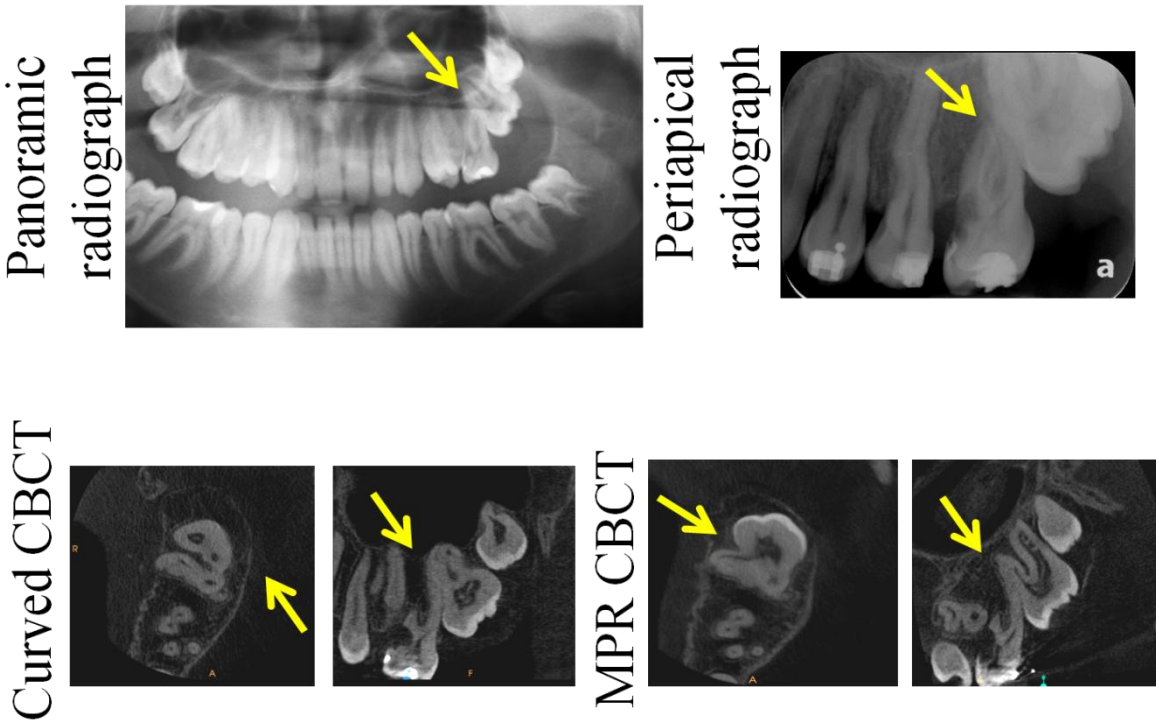

Figure 8: The conventional radiography shows that the eruption of the second molar in the left is delayed and it is overlapping the apical third of the first molar root. However, looking at the teeth at different planes in the CBCT shows that the first and second molars are fused together and that is the cause of the delayed eruption. Note the presence and the extent of the cervical root resorption in the first molar.

The comparison between the information given by the two methods of CBCT 3D reconstruction showed that, in 5 out of 29 impacted teeth cases, the one method of the CBCT gave us more information in the following categories:

1. **<u>Resorbed roots of the adjacent teeth:</u>**

The resorption of the adjacent teeth roots is one of the important criteria that could have an effect in the decision to extract the tooth with the resorption or not. However, it is difficult to detect buccal and lingual resorption in the conventional radiography. Since the CBCT is a 3D volume and we have the ability to reconstruct the dataset into different slices and to examine the structure of interest. In some cases, one of the two methods of the 3D reconstructions showed superiority over the other to detect the resorption but close examination of each case did not reveal any possible superiority of one mode of the 3D reconstruction over the other mode. See **Figure 9-10** below.

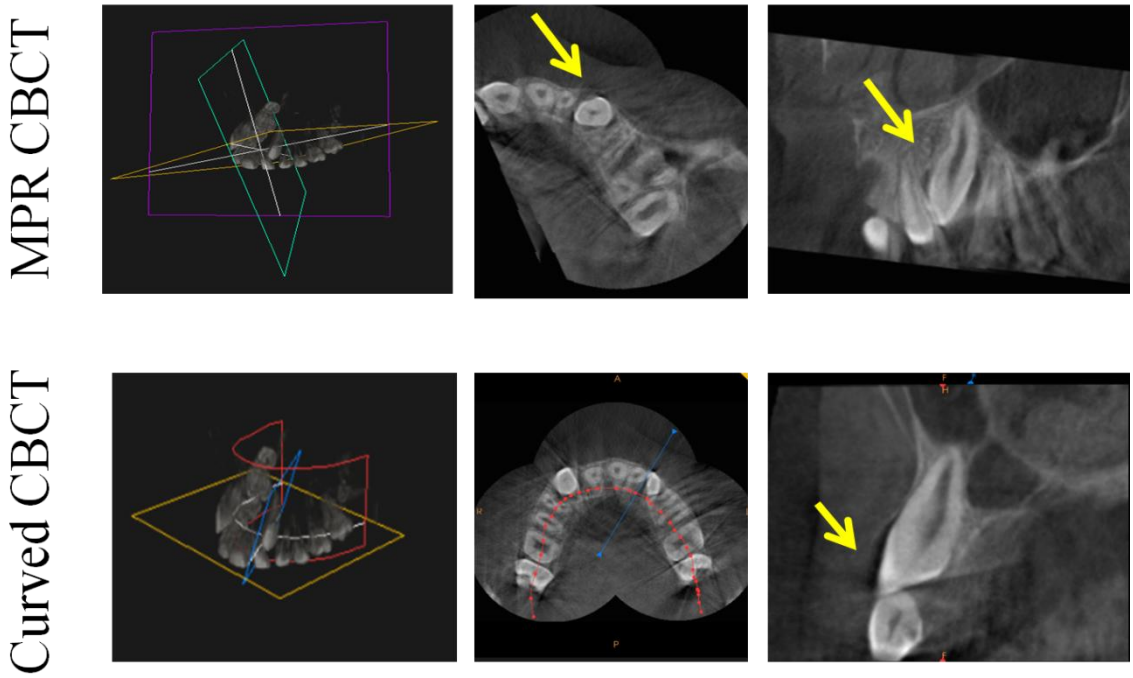

Figure 9: In this case, we can see that the resorption of the lateral incisor is visible in both reconstructions but it is clearer in the curved CBCT. For untrained viewer, it will be more difficult to detect the resorption in the MPR in compare with the curved.

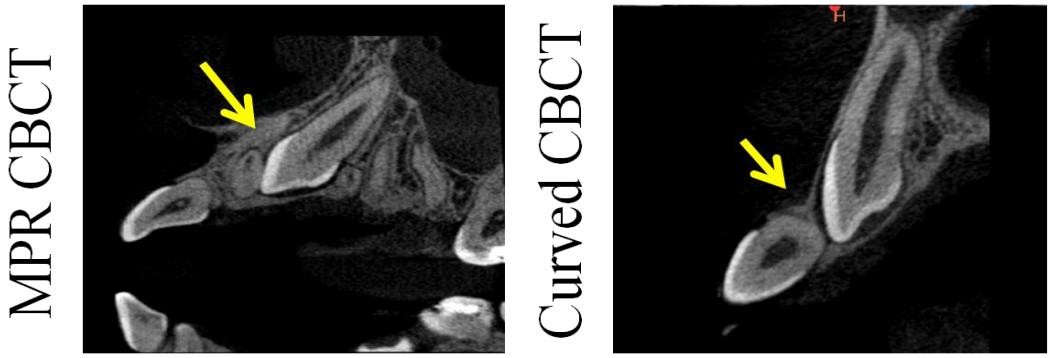

Figure 10: In this case, we see slight resorption in the MPR reconstruction but not clear in the curved.

2. **<u>Root dilacerations:</u>**

The presence of a dilaceration, especially if it was severe, could have a negative effect in the orthodontic tooth movement, extraction and any potential endodontic treatment. The ability to detect the root dilacerations in the diagnosis stage gives us a chance to decide on the future treatment of the tooth. Thus, the CBCT reconstruction should be able to detect the presence and the severity of the dilaceration. See **Figure 11.**

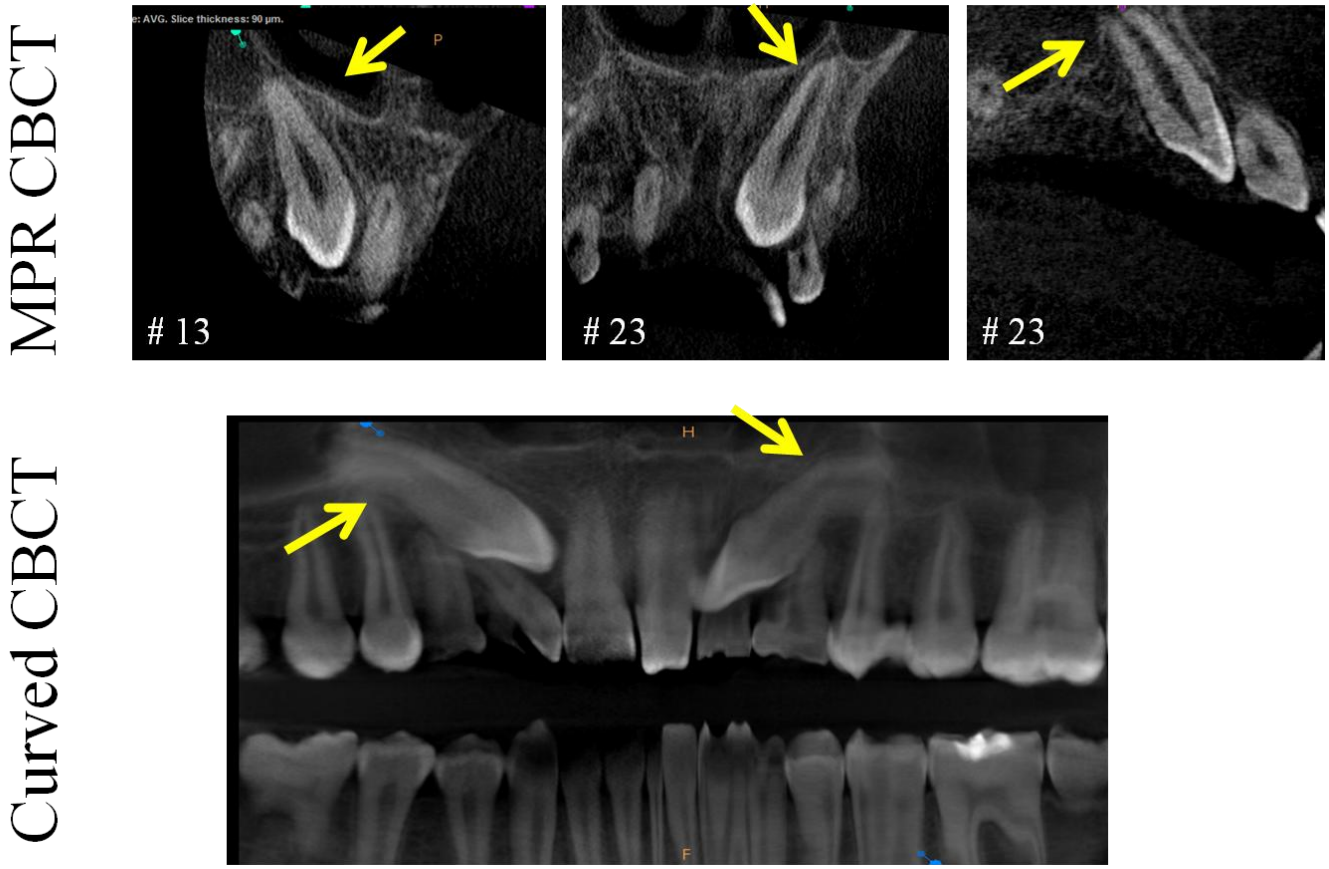

Figure 11: In the MPR images, the angulation in which the plan of reconstruction of each image was taken does not give us a clear image of the dilaceration in the root tip. In tooth # 13, the root looks within normal, but in tooth # 23, the tip of the root looks blunted and the opening in the apex looks wide. These criteria in # 23 could indicate that there could be a dilacerations in the root but it could also mean that the root formation was not completed yet and thus the apex opening is not closed yet.

3. **<u>Visualization of the bone defects:</u>**

The extent of the bony defect in any lesion in the dentoalveolar area determines the mode of reconstructive treatment of the lost bone. If the defect is too large, grafting the defect might prove to be challenging and difficult to achieve. For this reason, the extent of any bone defect due to the impaction of the teeth should be clearly evaluated to determine the future treatment. Careful consideration should be given as to whether the area needs a graft prior to attempting any orthodontic movements. Such consideration at

that stage is likely to enhance the quality of the final esthetic and functional outcomes of treatment. See **Figure 7 B.**

4. **<u>Roots in the maxillary sinus:</u>**

The presence of the root in the maxillary sinus needs to be detected early in the treatment. This will help us to determine the best treatment option - extract or expose and orthodontically align it into the arch – and decrease any possible side effect. **Figure 12** shows the presence of the canine root in the maxillary sinus.

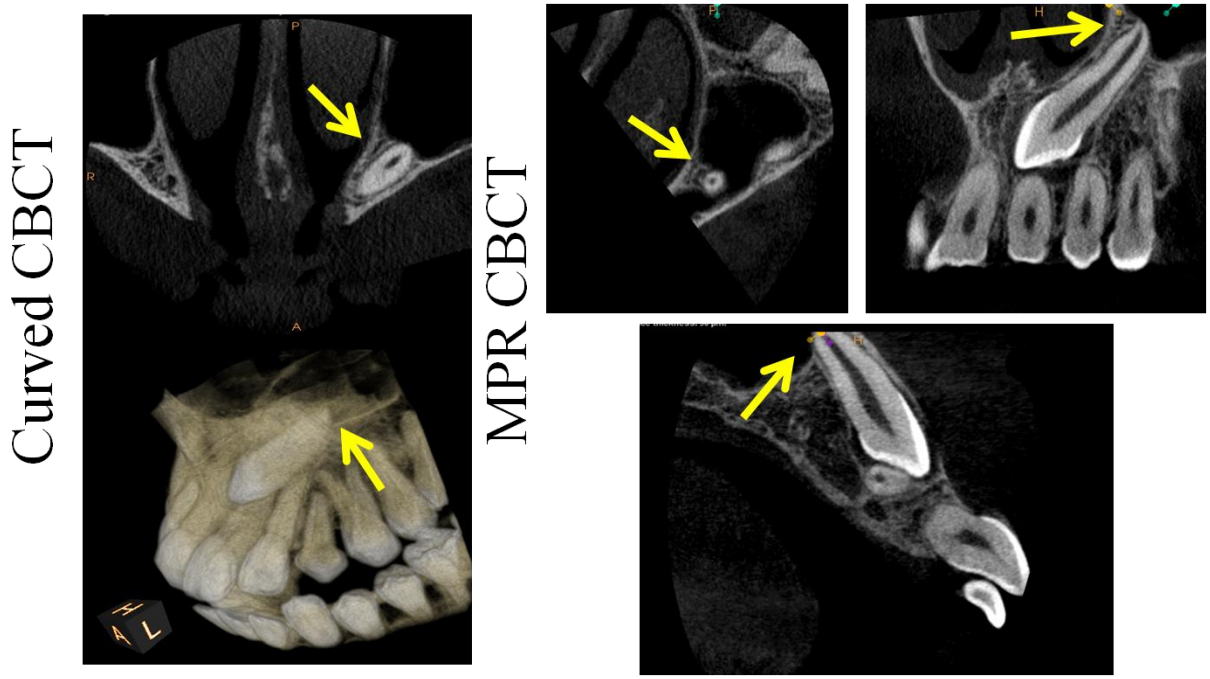

Figure 12: In this case, the MPR shows that the tip of the maxillary canine root is present in the maxillary sinus as the yellow arrow points. In the curved CBCT, it appears that the root tip is in the maxillary sinus, but not to the large extent that the MPR shows.

Chapter 7: Objective 3 Materials, Method and Results

7.1 Materials and Analysis:

7.1.1 The Sets:

For each patient's CBCT, the images were reconstructed using both the MPR and the curved techniques. From these reconstructions, screenshots of five different representative images were collected and put in a power point presentation as a set. Thus, for each case there is two sets and in each set there is five images. Examples of screenshots of the sets from the survey are in **Figure 19-43.**

7.1.2 The Consent Form:

Each participant was required to sign a consent form before starting the process. See **Appendix A**.

7.1.3 The Instructions:

Written instructions were given to the participants and those instructions were also explained to each one before starting the survey. See **Appendix B.**

7.1.4 The Survey:

For each CBCT set, the participant filled out a survey questionnaire. See **Appendix C.**

7.1.5 The Statistical Analysis:

The inter-examiner reliability was tested using the Kappa analysis. Significant differences in continuous variables such as years of practice and experience were tested by an independent sample t-test or its non-parametric equivalent (interval scale measurement). Significance in tests was defined when $p < 0.05$ and it was two-tailed. The level of agreement among the results of the survey (ordinal scales) between the two

CBCT reconstructions for the same scenarios was tested by Chi square test (categorical scales), while the certainty of the duplicate answers was tested by intra-class correlation coefficient (interval scale measurement).

7.2 Method:

1. Obtain ethics approval (**Ethics Certificate: H18-01660)**.
2. Obtain five different screenshots of each case for each of the two 3D reconstruction (curved + MPR) methods. This resulted in 10 screenshots in total for each of the 15 impacted canine cases.
3. Randomize the sets into two groups one time before the start of the surveys using block randomization method (the number of cases in both groups is the same). Then, the same order was used for each participant. After that, the sets were put into power-point presentations. Each group of power-point presentations was accessed by each participant on two separate sessions. There was a time gap of at least one week in between the two viewing sessions.
4. An email was sent to all the registered credentialed orthodontists teaching at the Orthodontic Department at UBC (23 orthodontists in total) by the program director asking for volunteers to participate in this study. See **Appendix D**.
5. The student approached each instructor in person, when that instructor was in the clinic and invited to participate in the study.
6. Each participant signed a consent form. See **Appendix A**.
7. The participating credentialed orthodontists were asked to fill up a questionnaire for each set to disclose the following in the questionnaire. See **Appendix C.**
    a. Prior experience reviewing CBCT dataset.

b. Disclose their length of orthodontic service.

c. Indicate the dental criteria specific for the case and provide possible treatment plan.

8. Compare the information obtained from the MPR and curved CBCT reconstructions.
9. Compare the orthodontist's familiarity with the MPR and curved CBCT and its impact in the diagnosis and treatment planning using surveys.

7.3 Results:

15 out of the 23 (65%) volunteered to participate in the survey. The reasons to decline included not having enough time to participate in the survey, and three said that they depend on the radiologists reports when they use CBCT.

During taking the surveys, the participants commented on the process and the questions:

1. 5 out of 15 said that they wanted to go through the whole volume and then answer the surveys. They suggested doing few cases but going through the whole volume to answer the surveys. However, they were concerned about the length of time that each case will take.
2. 7 out of 15 said they use CBCT in less than 2 cases per year or less and they usually depend on a radiologist, surgeon or periodontist to review the CBCT dataset for them.
3. All the 15 participants use the MPR method.
4. 7 out of 15 participants knew how to read the curved CBCT method.

After the survey, inter-examiner reliability was conducted and the results show that there is no significant difference between the 1st and 2nd times they did the surveys as shown in **Figures 13-17.** Generally, they scored the same answer in the two times they reviewed the same dataset.

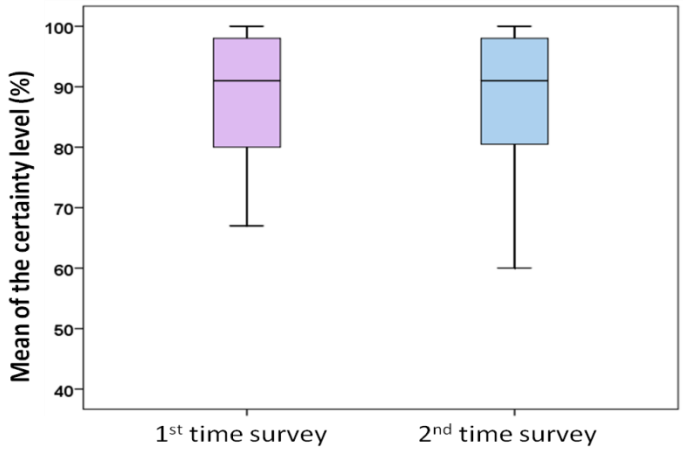

Figure 13: Inter-examiner reliability regarding the level of impaction level of certainty.

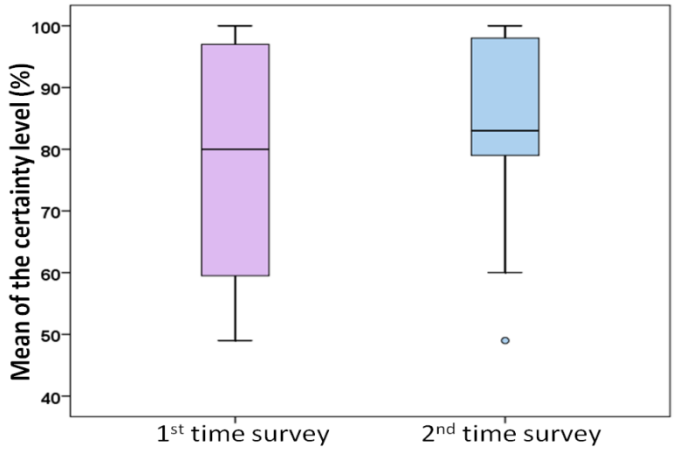

Figure 14: Inter-examiner reliability regarding the adjacent tooth root resorption level of certainty.

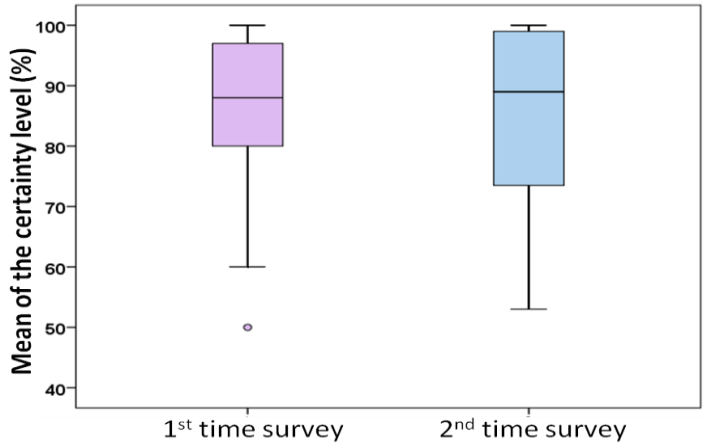

Figure 15: Inter-examiner reliability regarding the presence of dilaceration level of certainty.

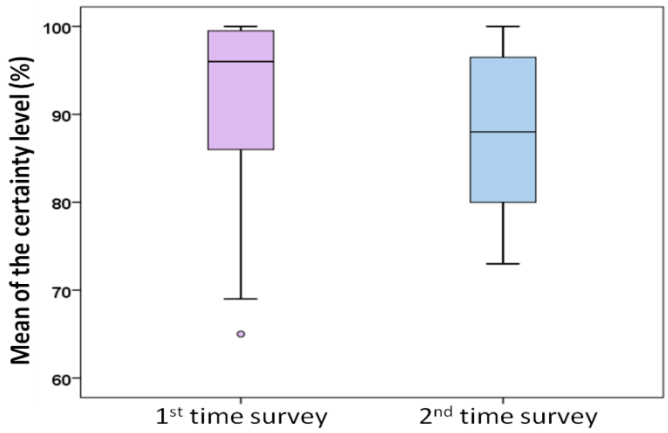

Figure 16: Inter-examiner reliability regarding the presence of a cyst level of certainty.

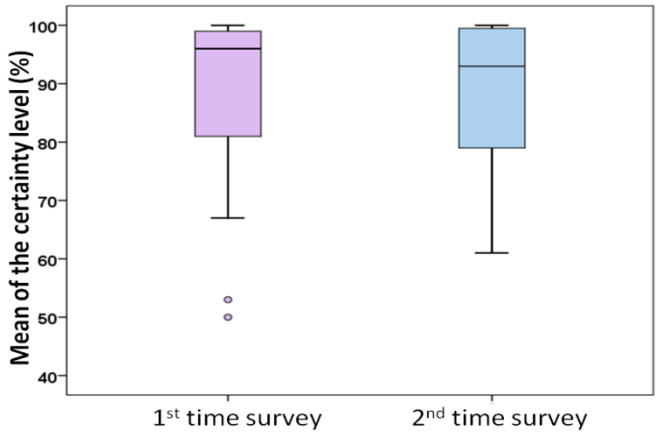

Figure 17: Inter-examiner reliability regarding the ankylosis of the impact tooth level of certainty.

For this study, we had 15 participants (6 females: 9 males). The survey revealed that the females on average have almost 10 years of experience less than their male colleagues but that was not statistically significant. The participants experience in both the MPR and curved is comparable between the two groups with lesser years of experience in the curved. This information is summarized in **Table 6**.

Sex	Females (6) mean ± SD	Males (9) mean ± SD	P value
Years of practice	15.5 ± 11.5	26.4 ± 14.3	0.142
Experience in MPR CBCT in years	5.8 ± 4.0	6.9 ± 4.0	0.627
Experience in curved CBCT in years	1.7 ± 3.2	3.7 ± 3.9	0.301

Table 6: Participants experience represented by years, note that the years of experience in the MPR is more than that of the curved, $P < 0.05$ is considered significant. **SD:** standard deviation.

Analyzing the level of agreement between the survey answers showed that most of the criteria have above 70% level of agreement except for three: the level of impaction, the resorption in the adjacent tooth root, and the presence of dilacerations of the impacted tooth. This means that in 70% of the time the participants have the same answer when they looked at the same variable in both reconstruction methods (curved and MPR). This information is summarized in **Table 7 and Figure 18.**

Variables	Average (%)	SD
Position of the impacted tooth	73.3	23.8
Level of impaction	56.4	12.8
Adjacent tooth root resorption	48. 9	23.3
presence of dilaceration	64	17.2
Presence of a cyst	72.4	16.5
Ankylosis of the impacted tooth	83.5	10
Need for different image modality	71.6	8.5
Recommended treatment plan	73.3	21.5

Table 7: The average level of agreement between the survey answers when the CBCT 3D reconstruction methods were viewed. **SD:** standard deviation.

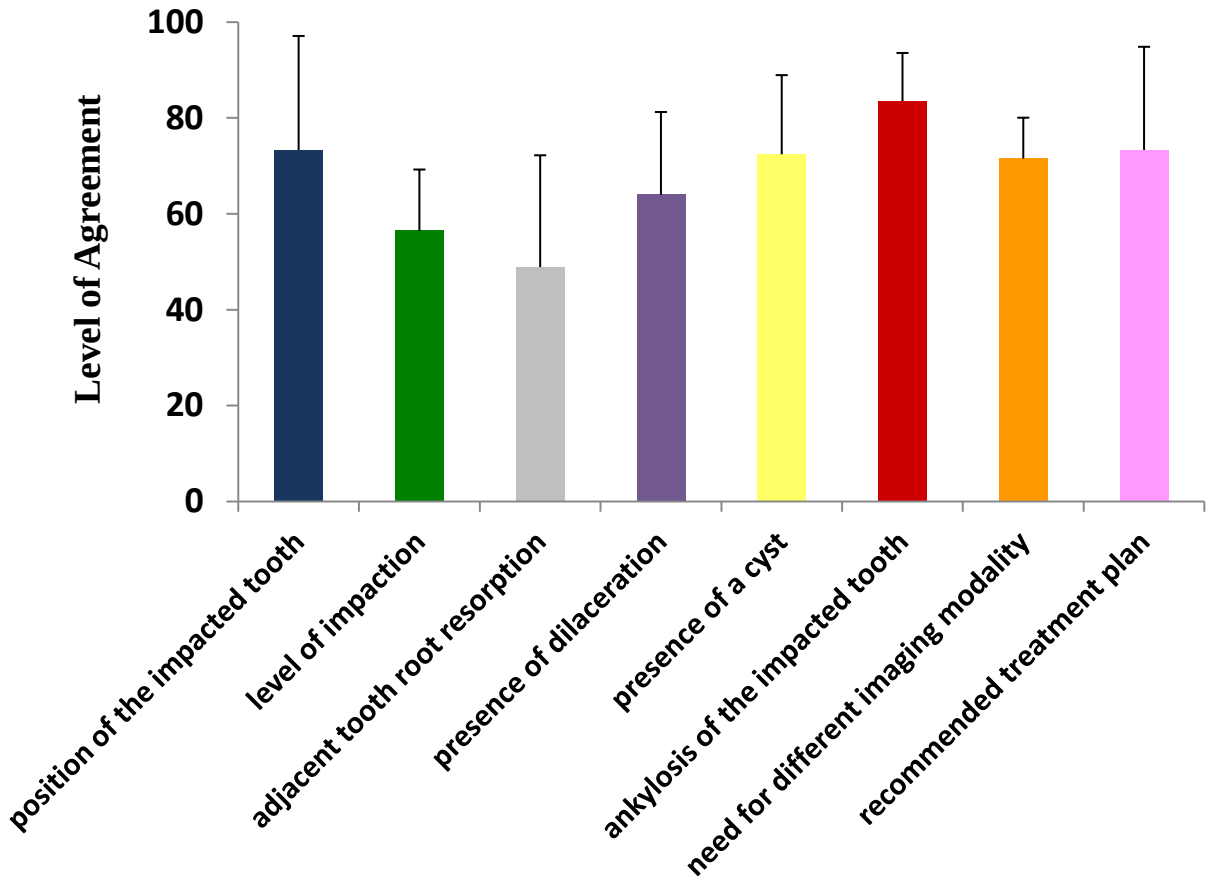

Figure 18: Chart representing the level of agreement between the responses of the same participant when comparing the MPR and the curved CBCT reconstructions.

Examining the certainty level of the answers between the two methods shows that the examiners have mostly high certainty level of their answers between the two methods. Although almost half of the participants reported that they do not have experience in the curved CBCT, their certainty of the answers between the MPR and the curved looks comparable for each case. The box plots - following the screenshot for each case - represent the certainty level of the answers. The line inside each box represents the median of the answers. The colored box represents 50% of the numbers between the 1st percentile to the 3rd percentile. The upper whisker represents the highest 25% percentile of data and the lower whisker represents the lowest 25%

percentile of the data. The dots in the chart represent the outliers. When we examine all the box plots, we find that for some cases, the confidence level of the participant is high and for other cases it is low. The confidence levels vary depending on the difficulty of the case. The MPR and curved reconstructions and the results of their reviews are set out in **Figures 19 - 63.**

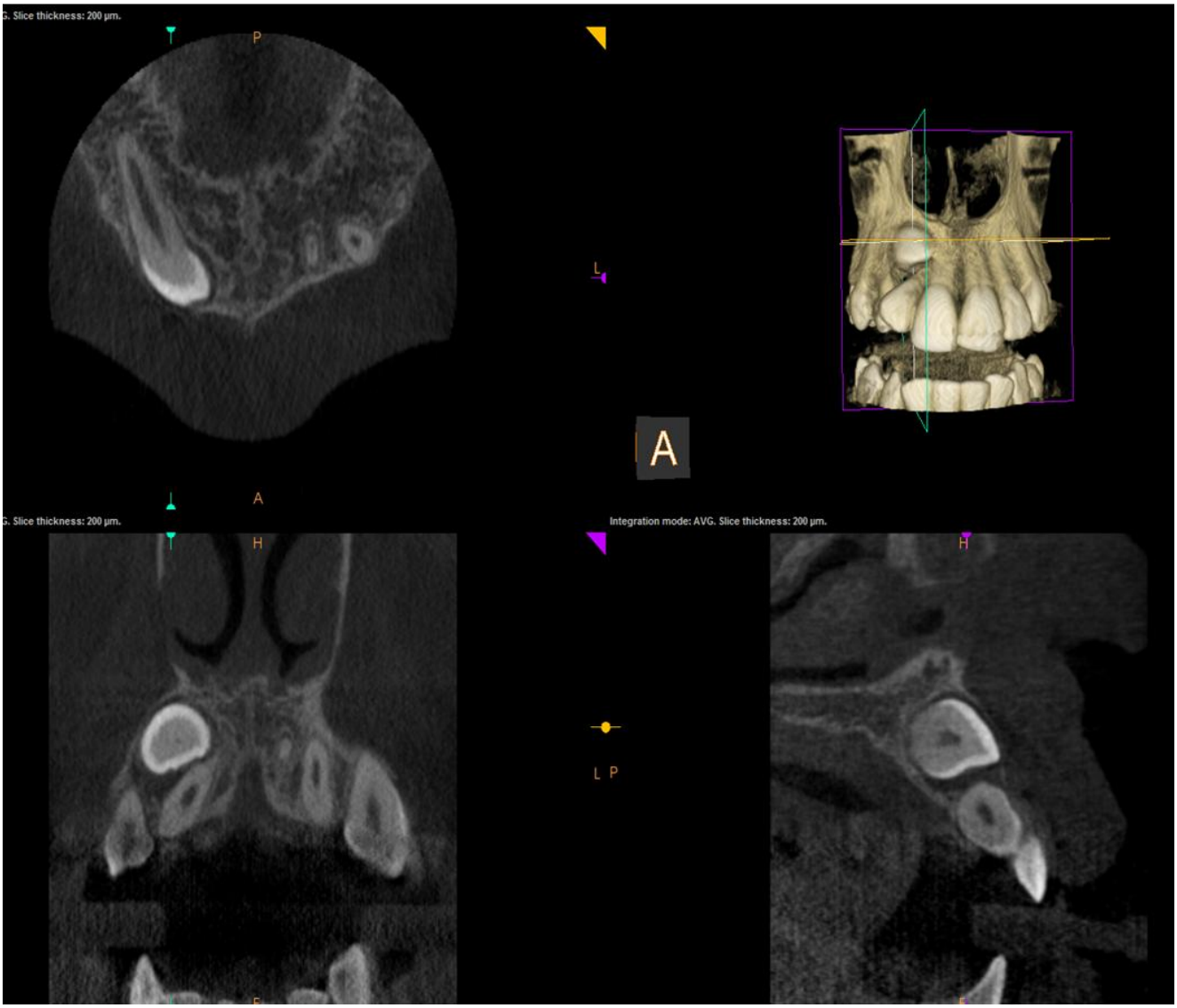

Figure 19: Example of a screenshot of MPR reconstruction from case 1.

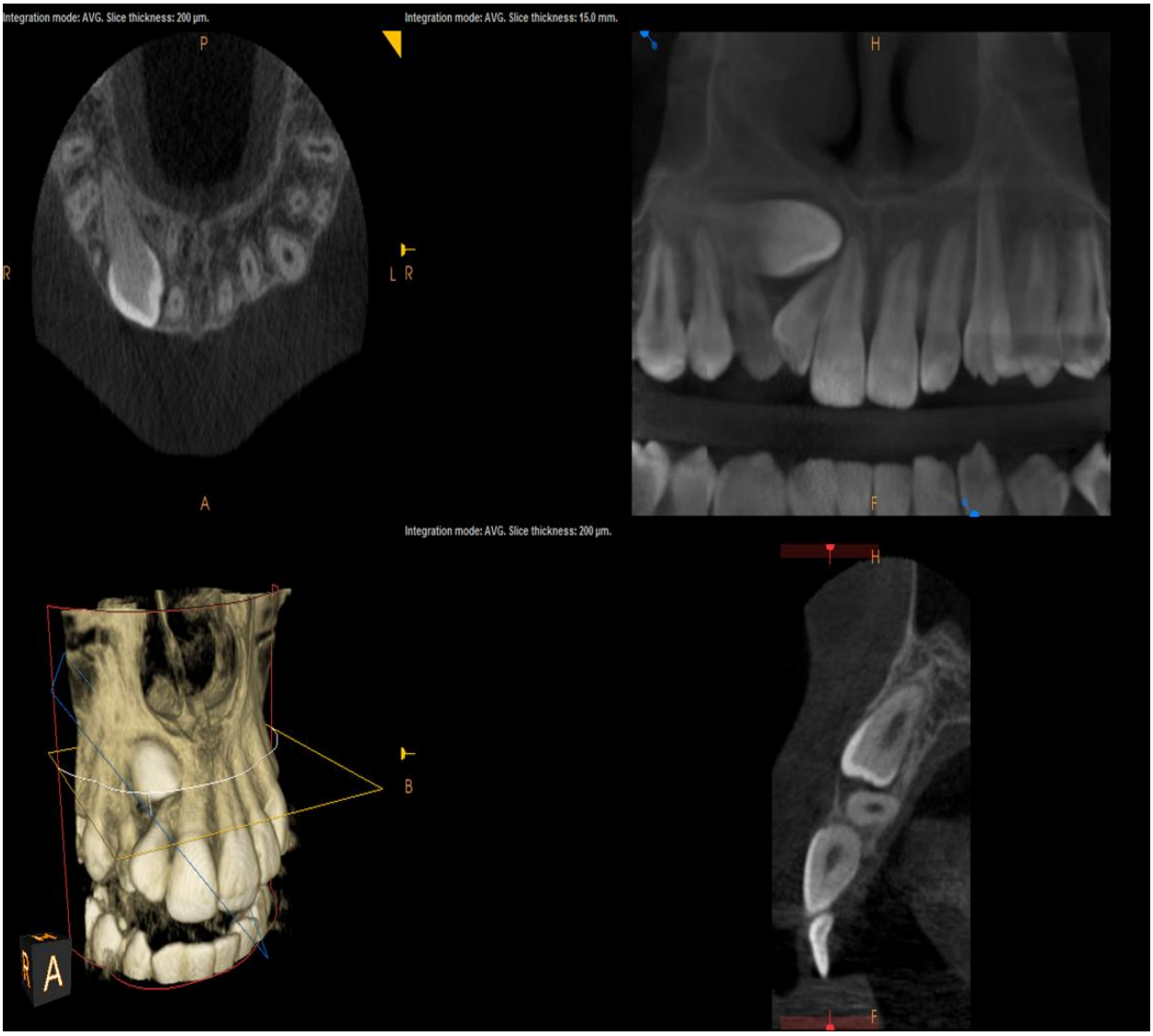

Figure 20: Example of a screenshot of curved reconstruction from case 1.

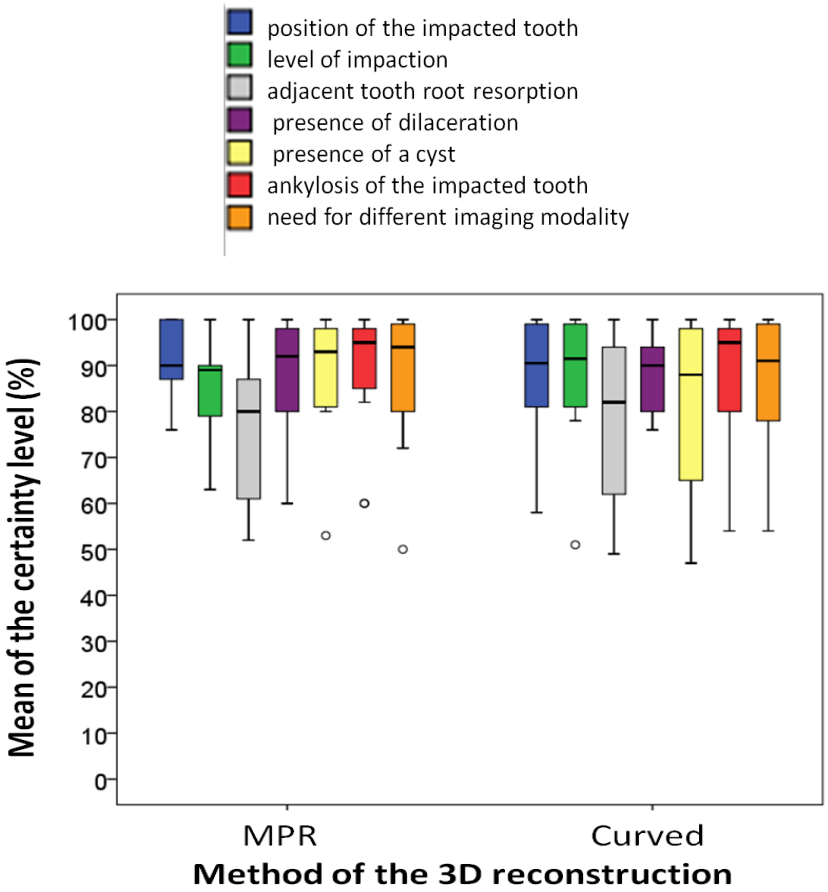

Figure 21: Level of certainty in case 1.

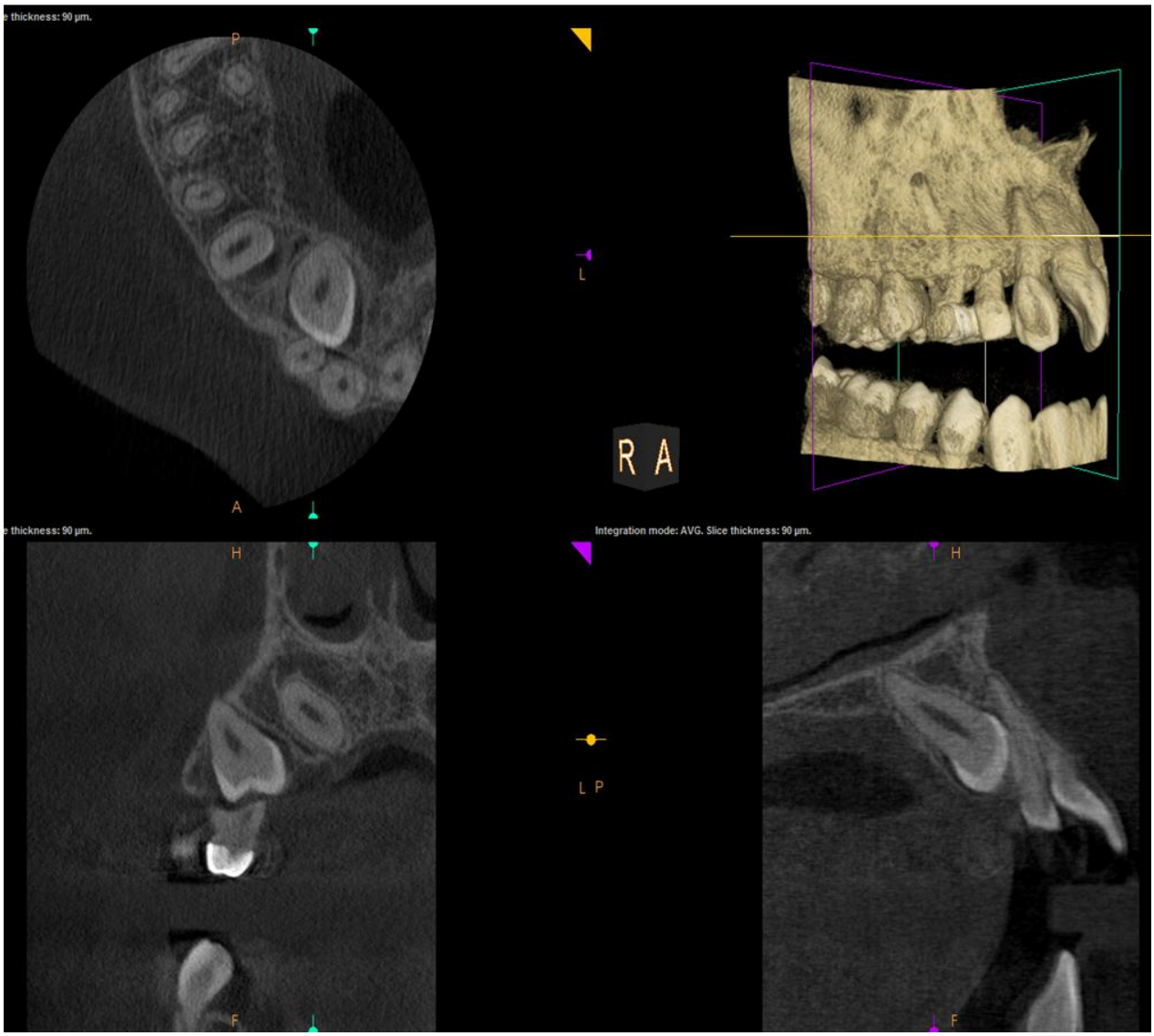

Figure 22: Example of a screenshot of MPR reconstruction from case 2.

Figure 23: Example of a screenshot of curved reconstruction from case 2.

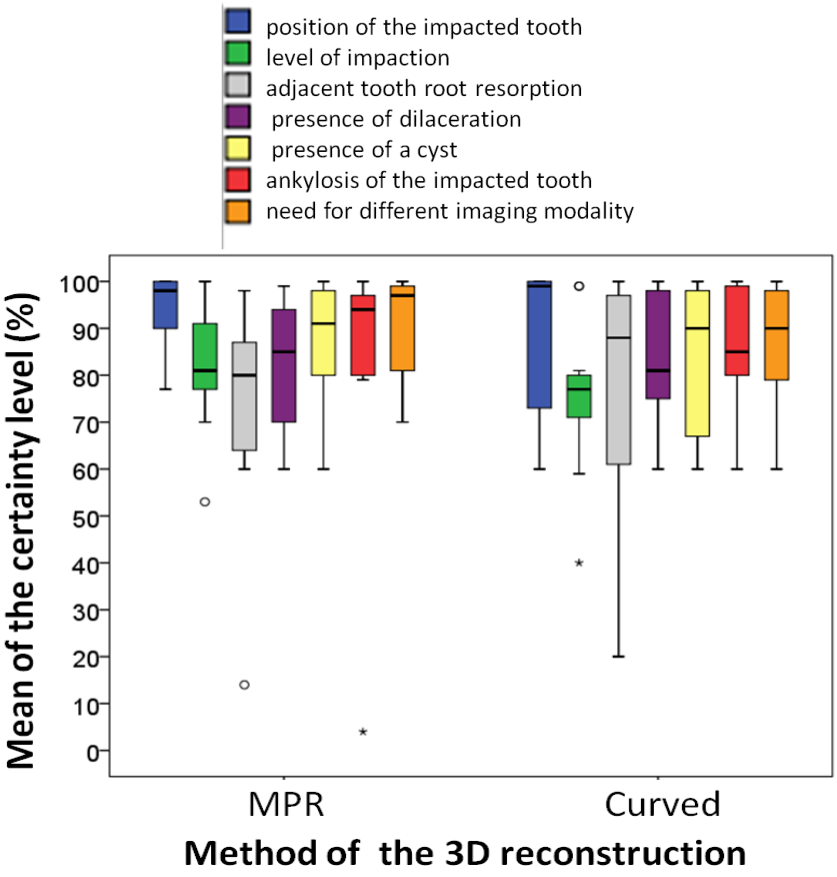

Figure 24: Level of certainty in case 2.

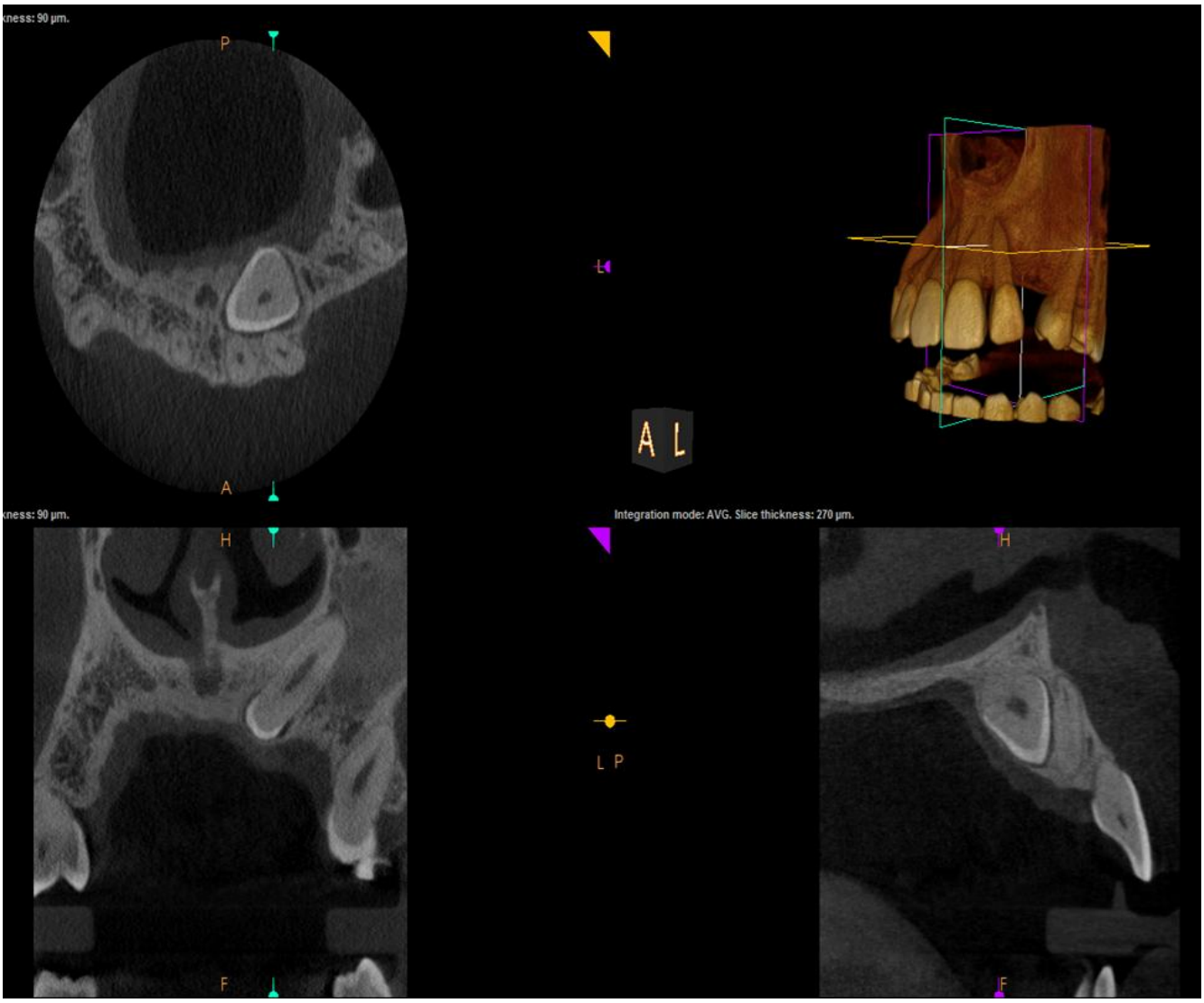

Figure 25: Example of a screenshot of MPR reconstruction from case 3.

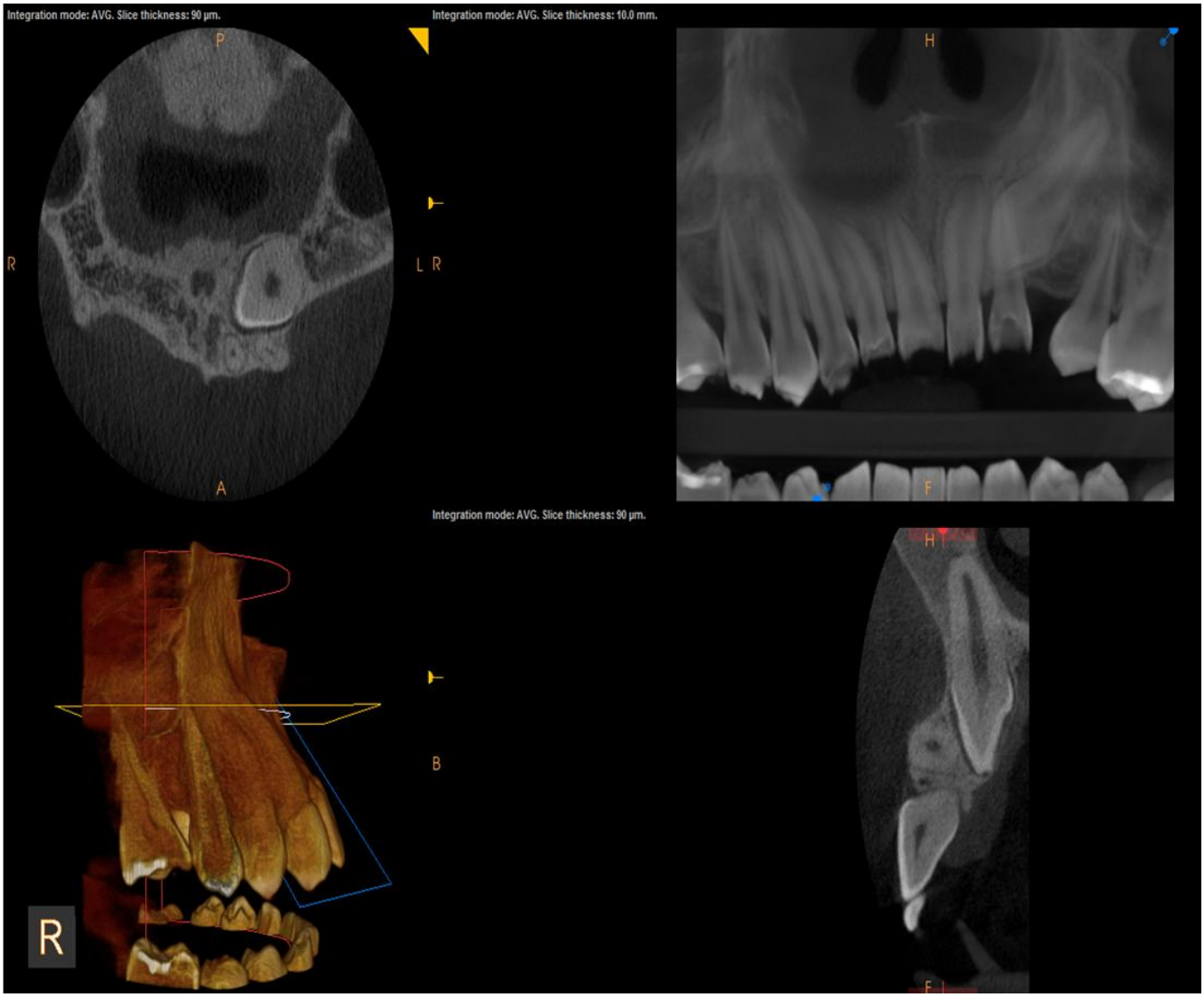

Figure 26: Example of a screenshot of curved reconstruction from case 3.

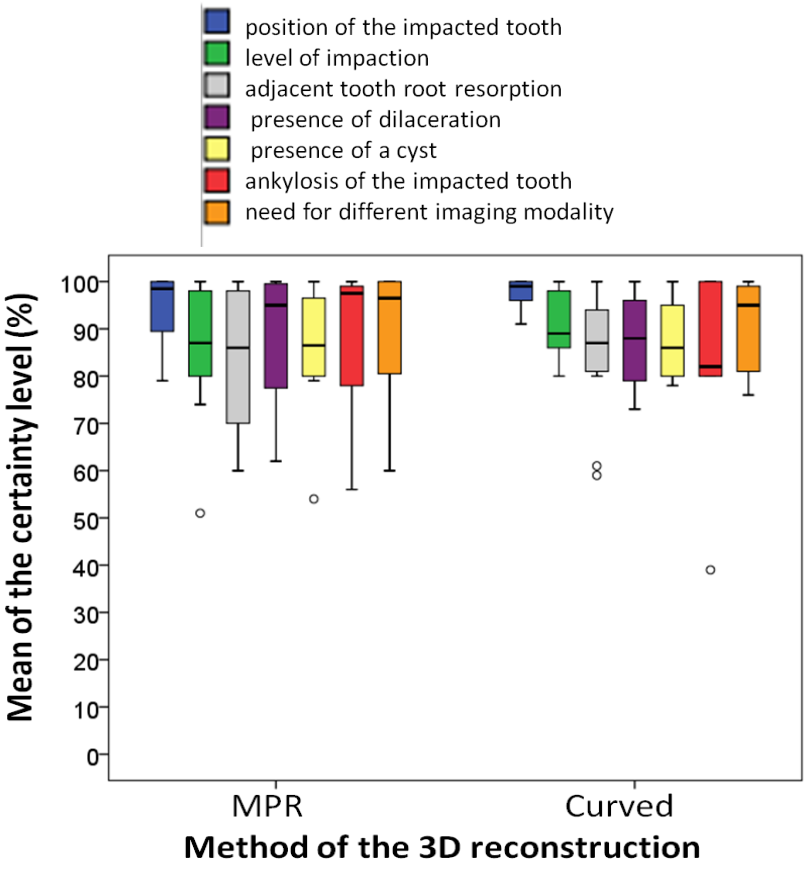

Figure 27: Level of certainty in case 3.

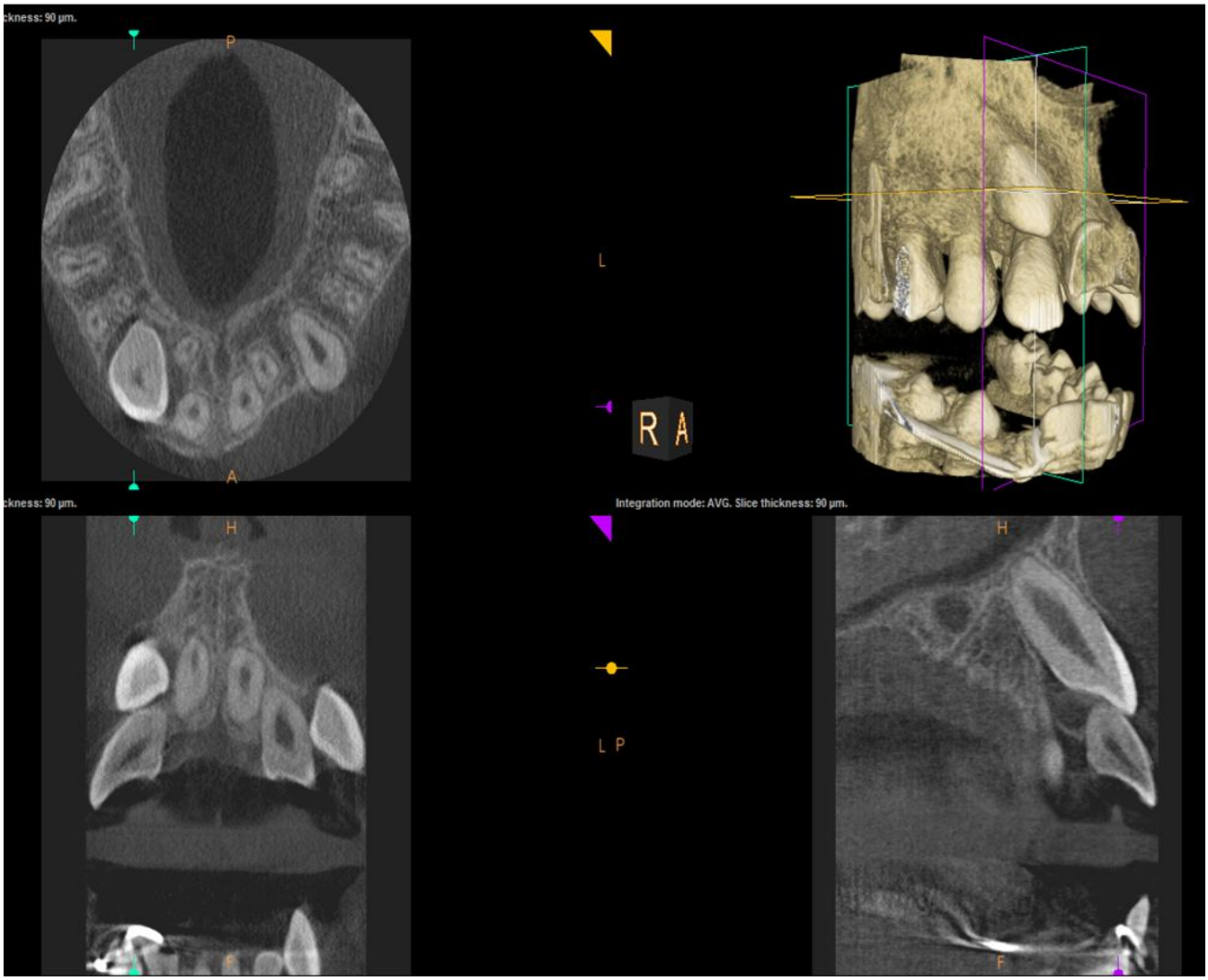

Figure 28: Example of a screenshot of MPR reconstruction from case 4.

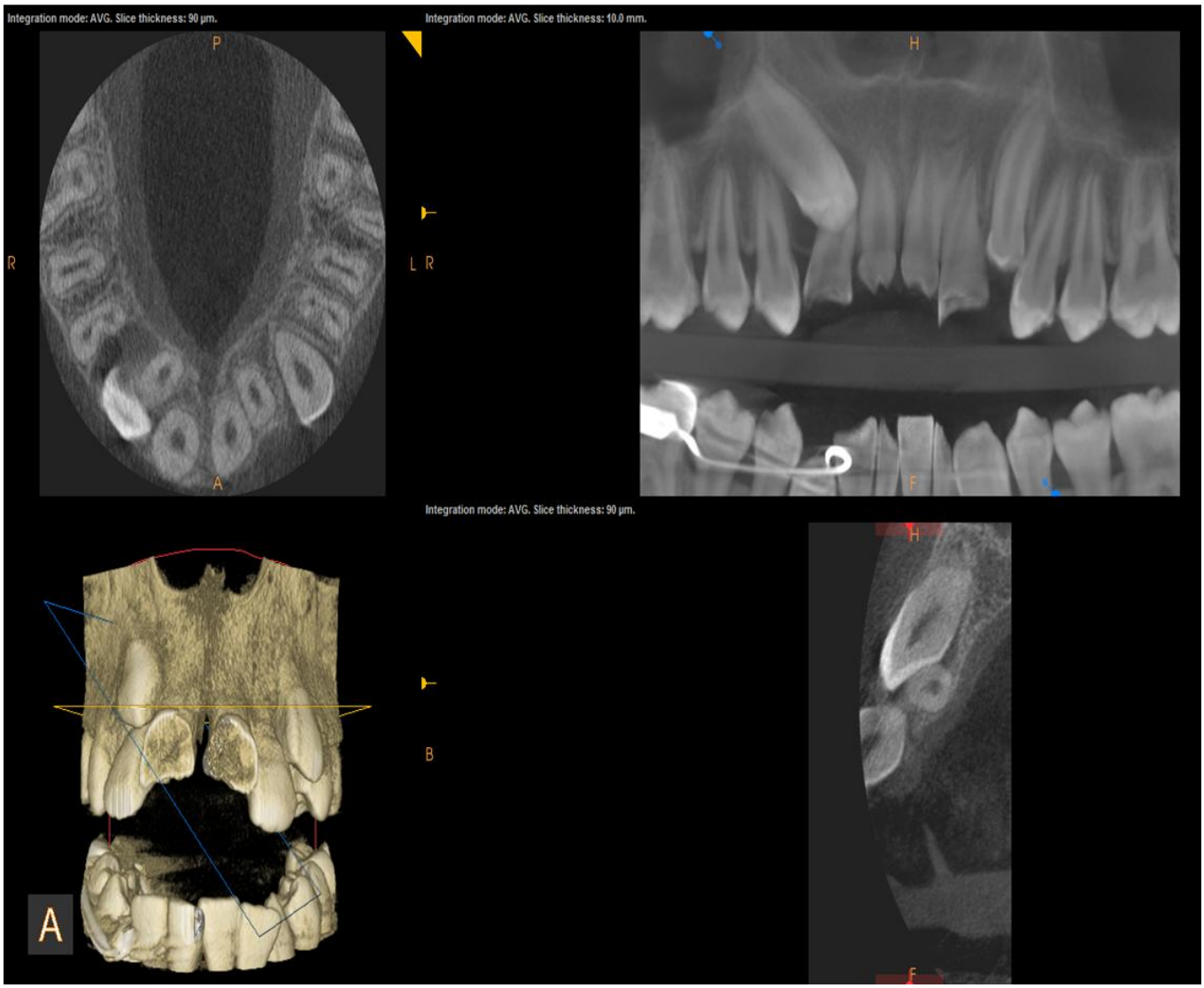

Figure 29: Example of a screenshot of curved reconstruction from case 4**.**

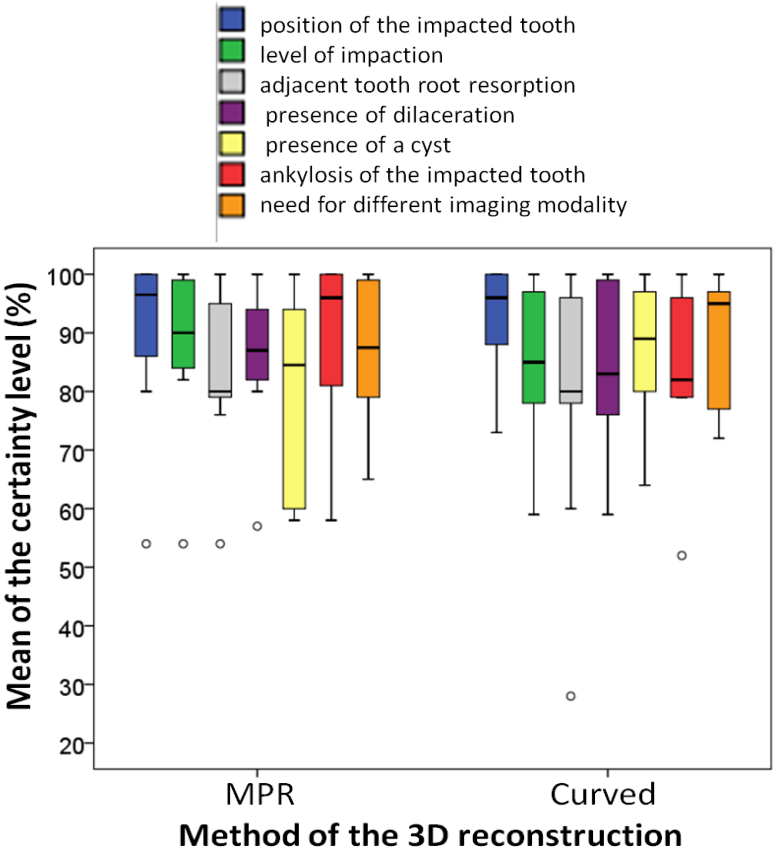

Figure 30: Level of certainty in case 4.

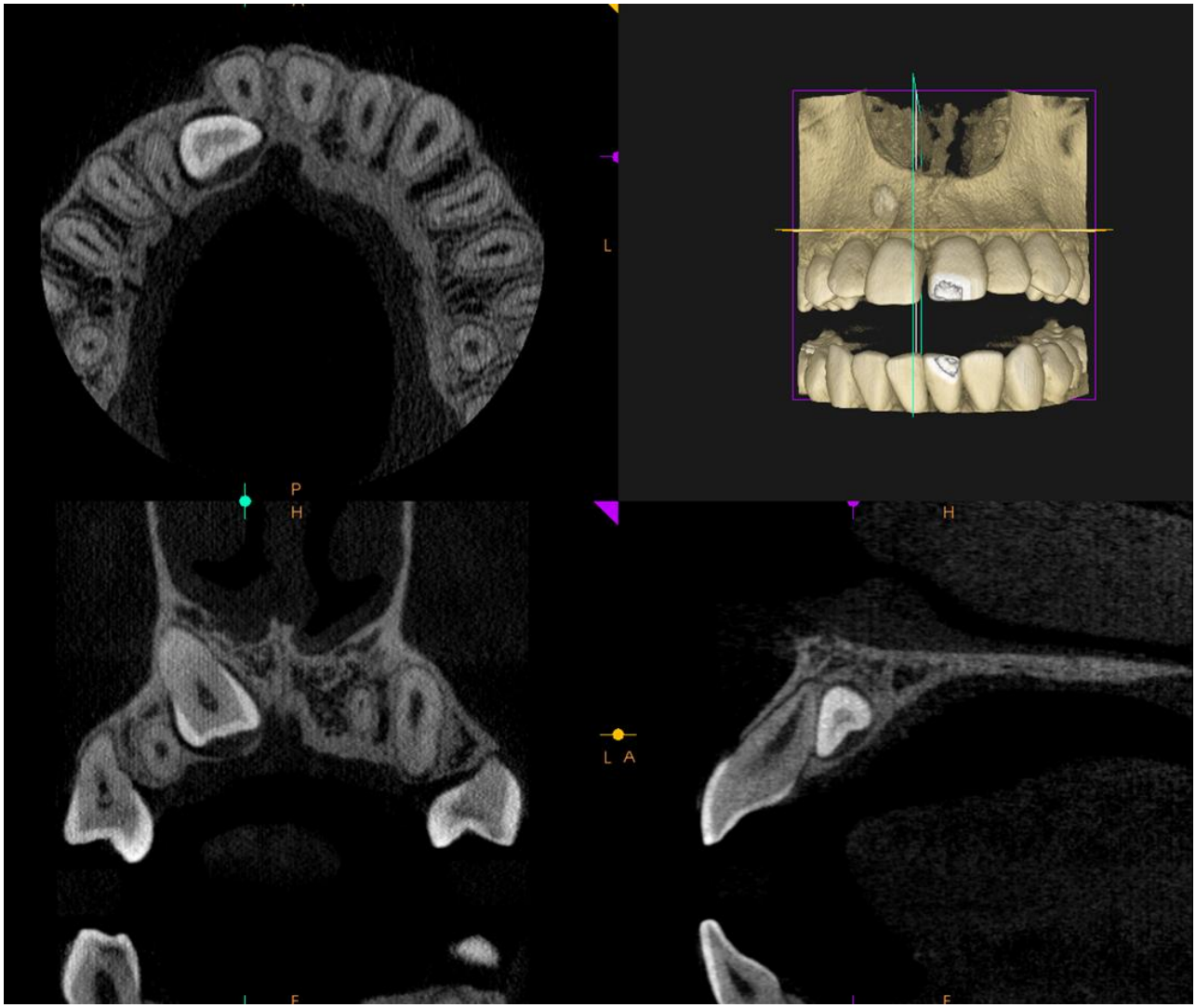

Figure 31: Example of a screenshot of MPR reconstruction from case 5.

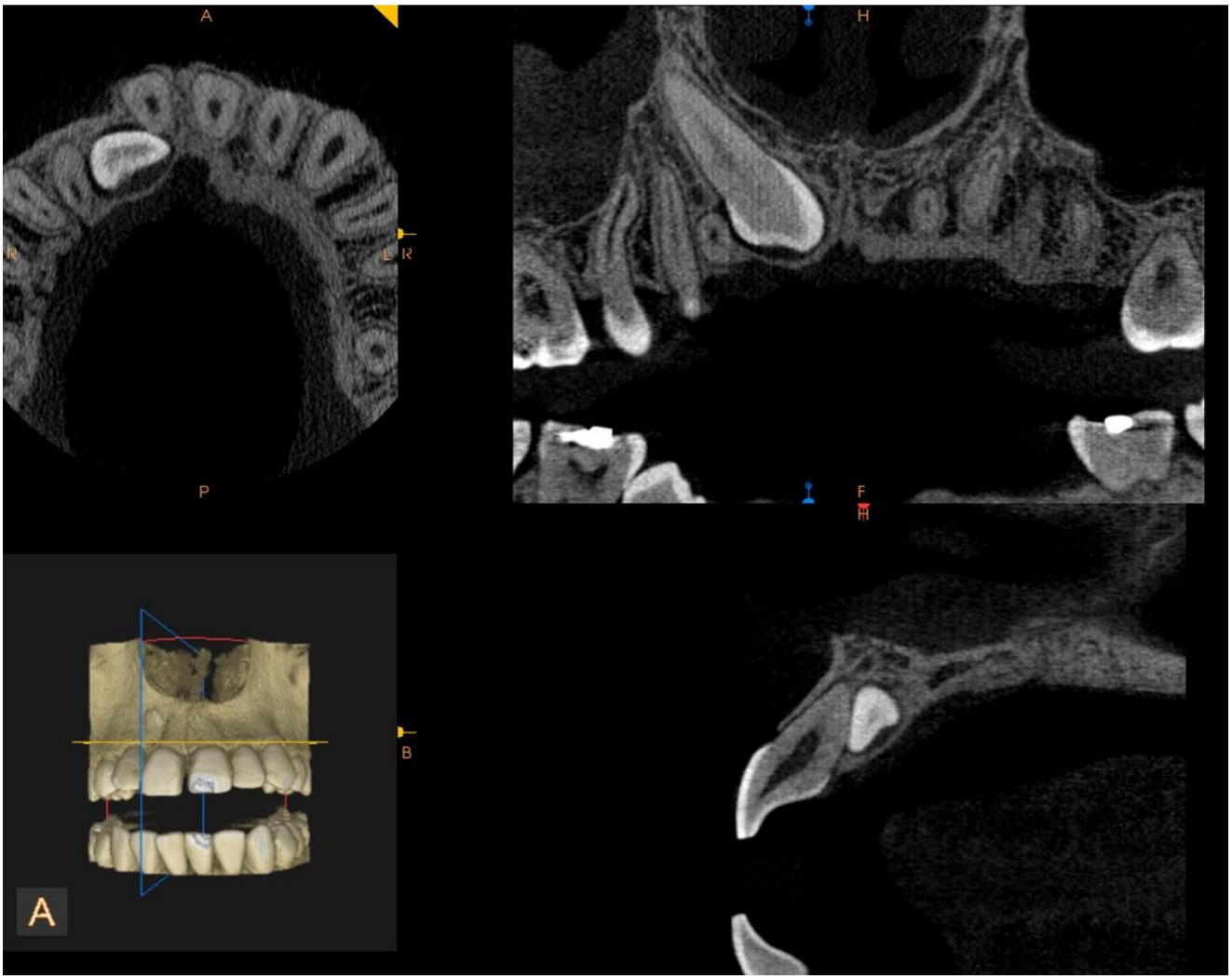

Figure 32: Example of a screenshot of curved reconstruction from case 5.

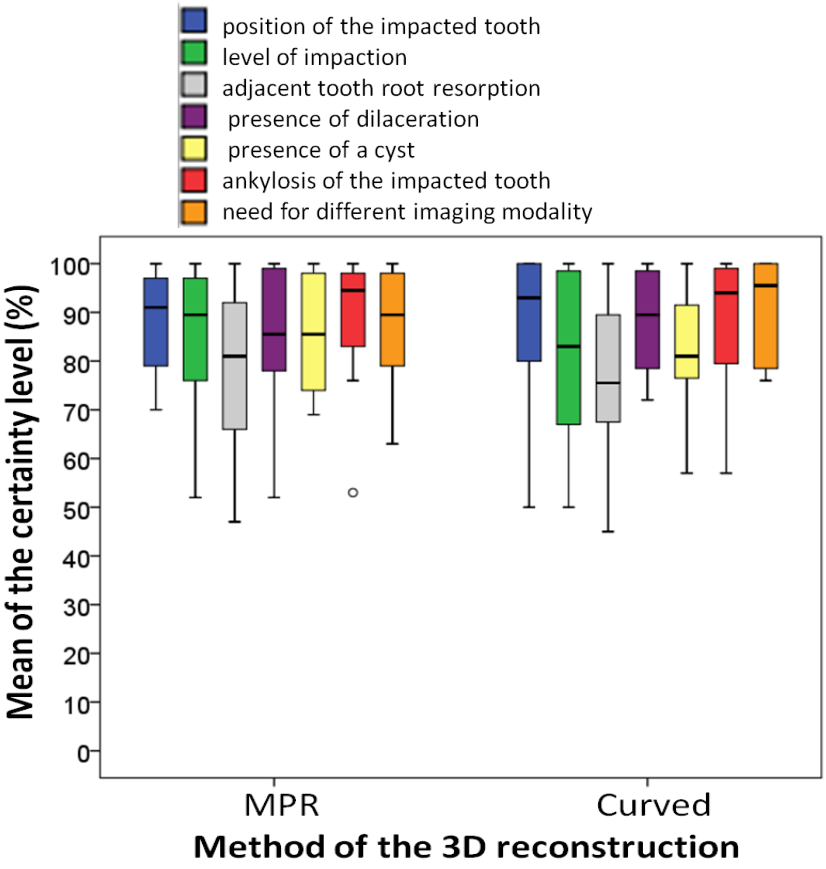

Figure 33: Level of certainty in case 5.

Figure 34: Example of a screenshot of MPR reconstruction from case 6.

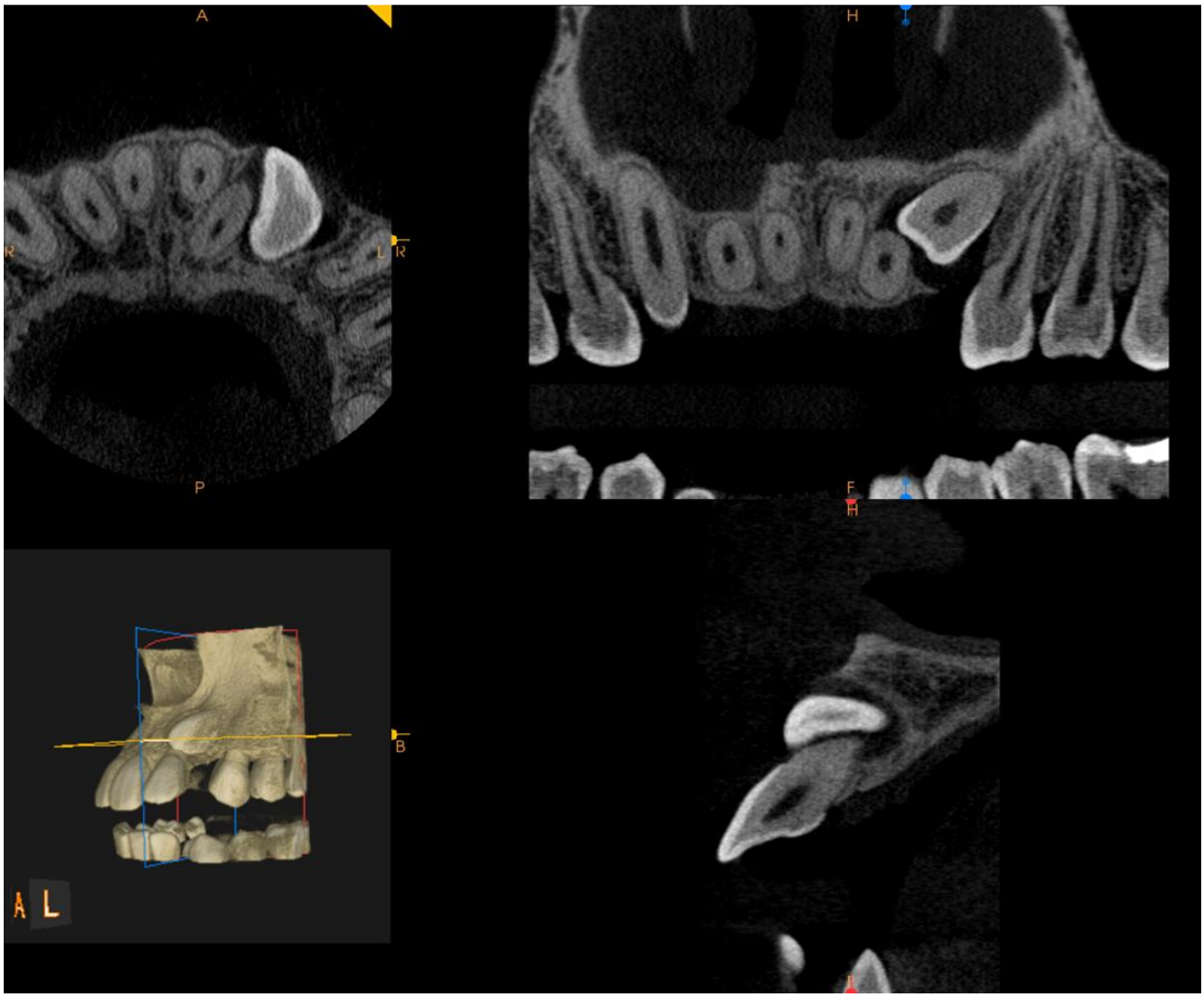

Figure 35: Example of a screenshot of curved reconstruction from case 6.

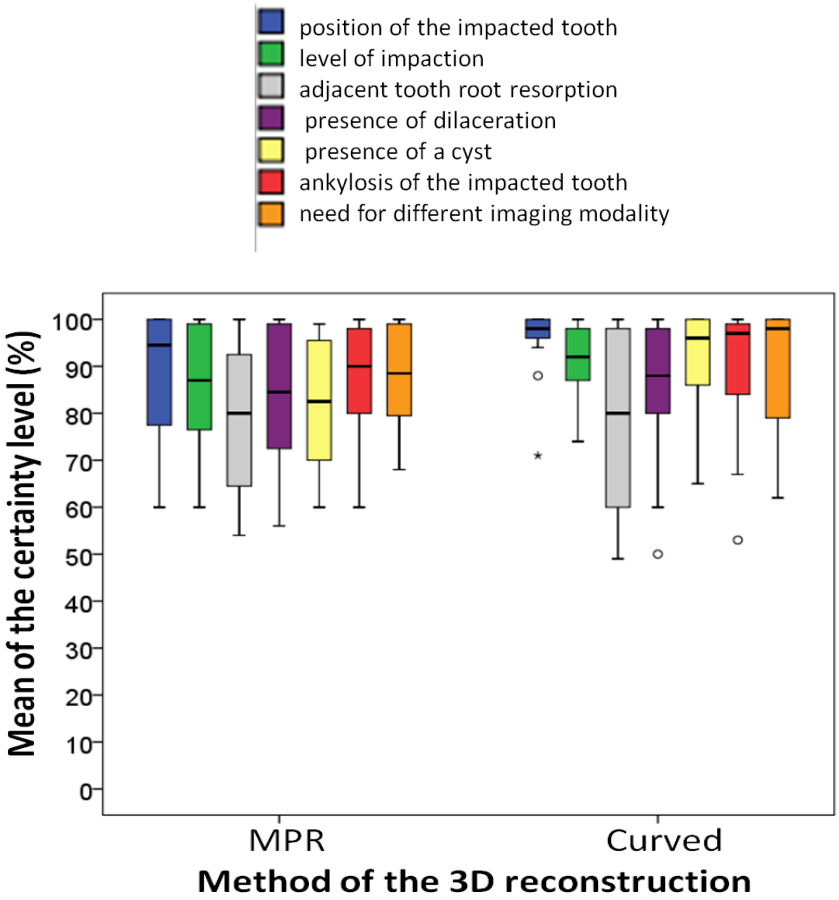

Figure 36: Level of certainty in case 6.

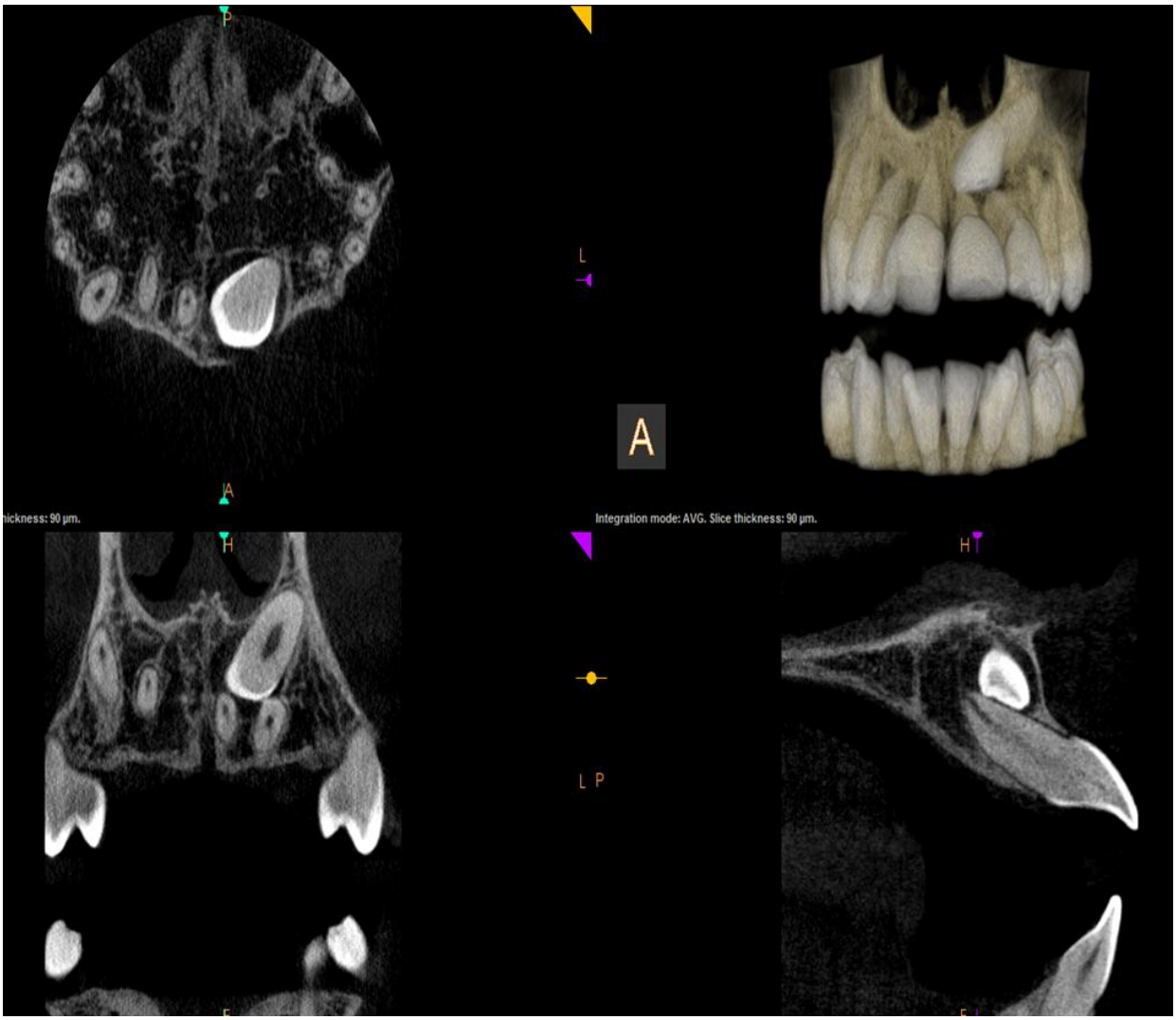

Figure 37: Example of a screenshot of MPR reconstruction from case 7.

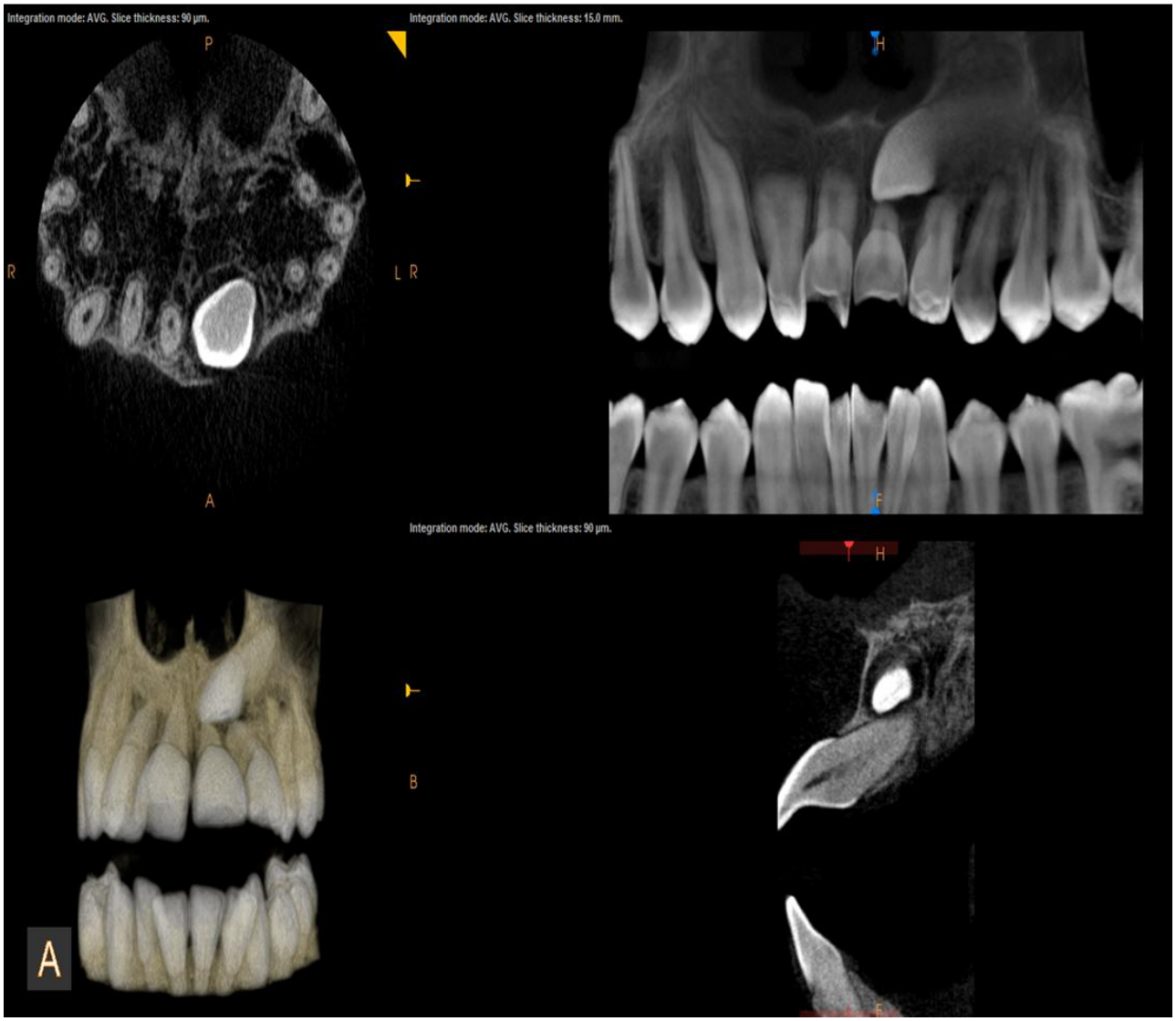

Figure 38: Example of a screenshot of curved reconstruction from case 7.

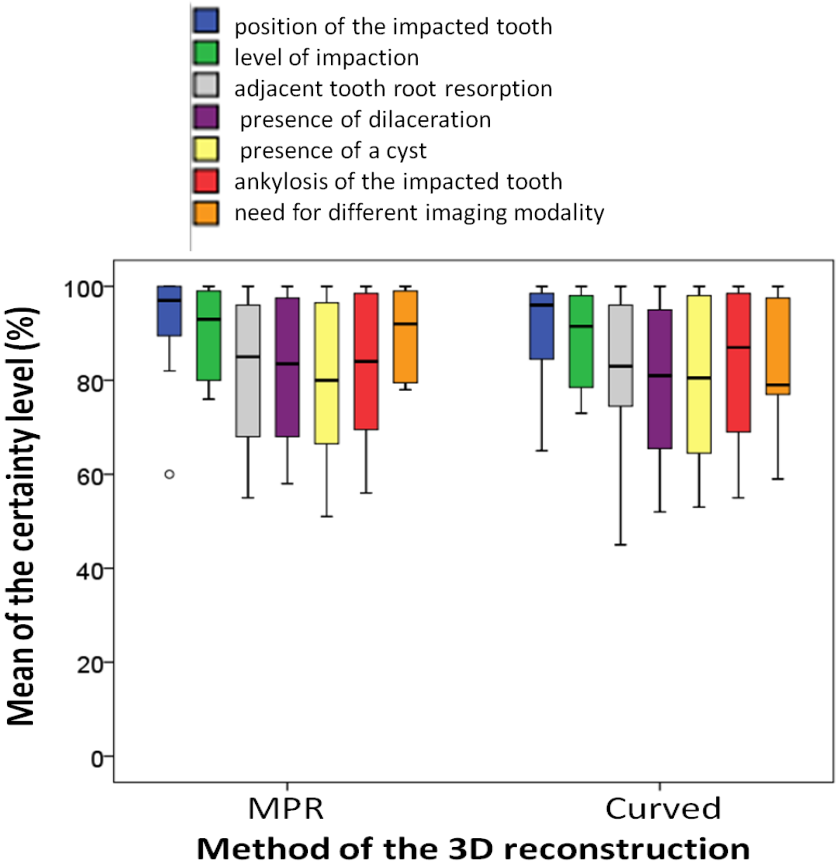

Figure 39: Level of certainty in case 7.

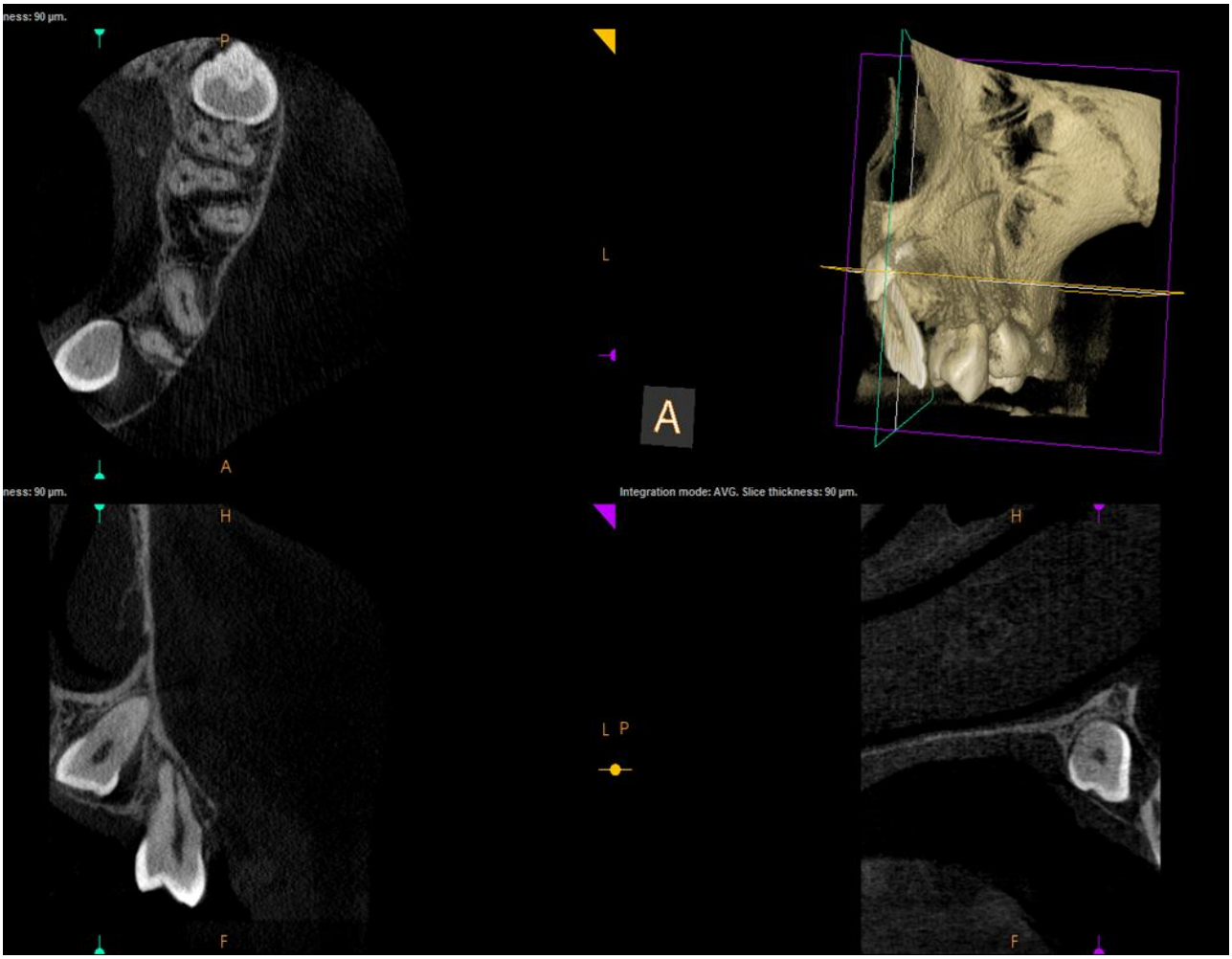

Figure 40: Example of a screenshot of MPR reconstruction from case 8.

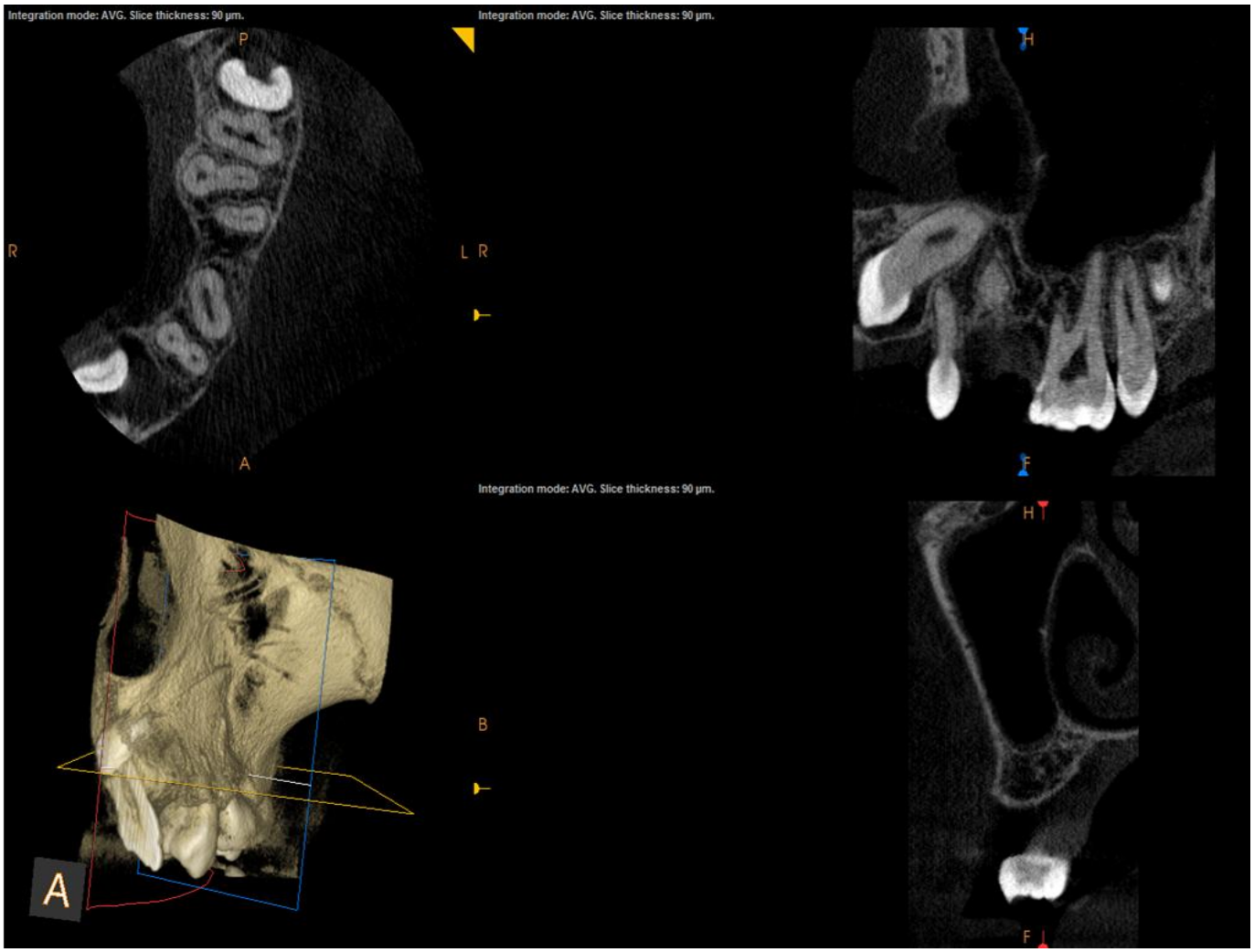

Figure 41: Example of a screenshot of curved reconstruction from case 8.

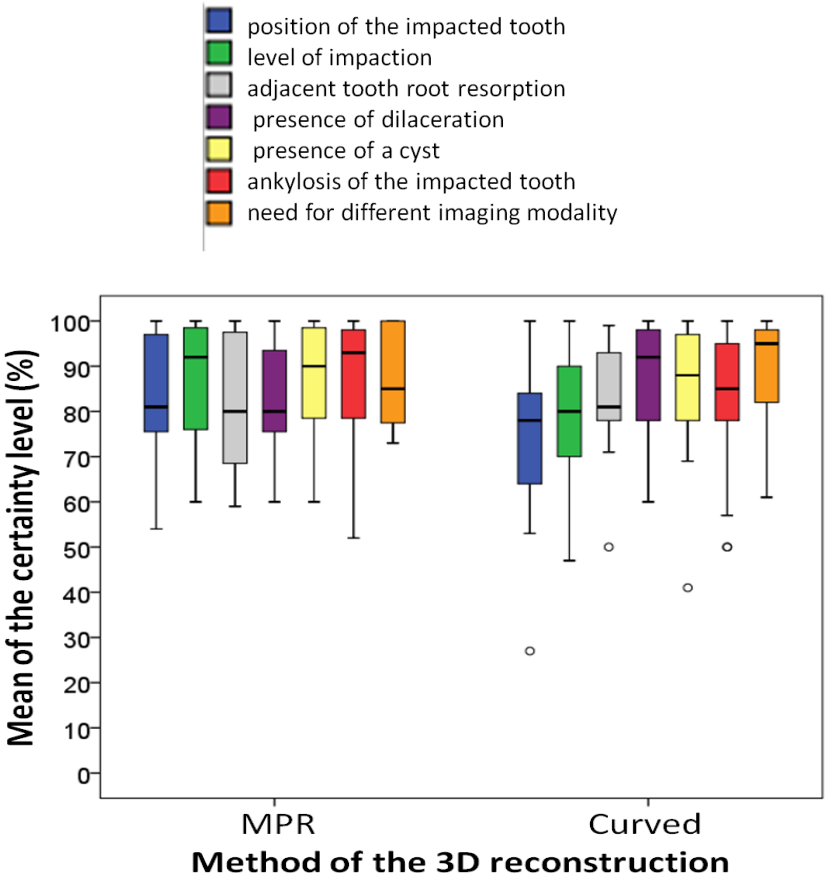

Figure 42: Level of certainty in case 8.

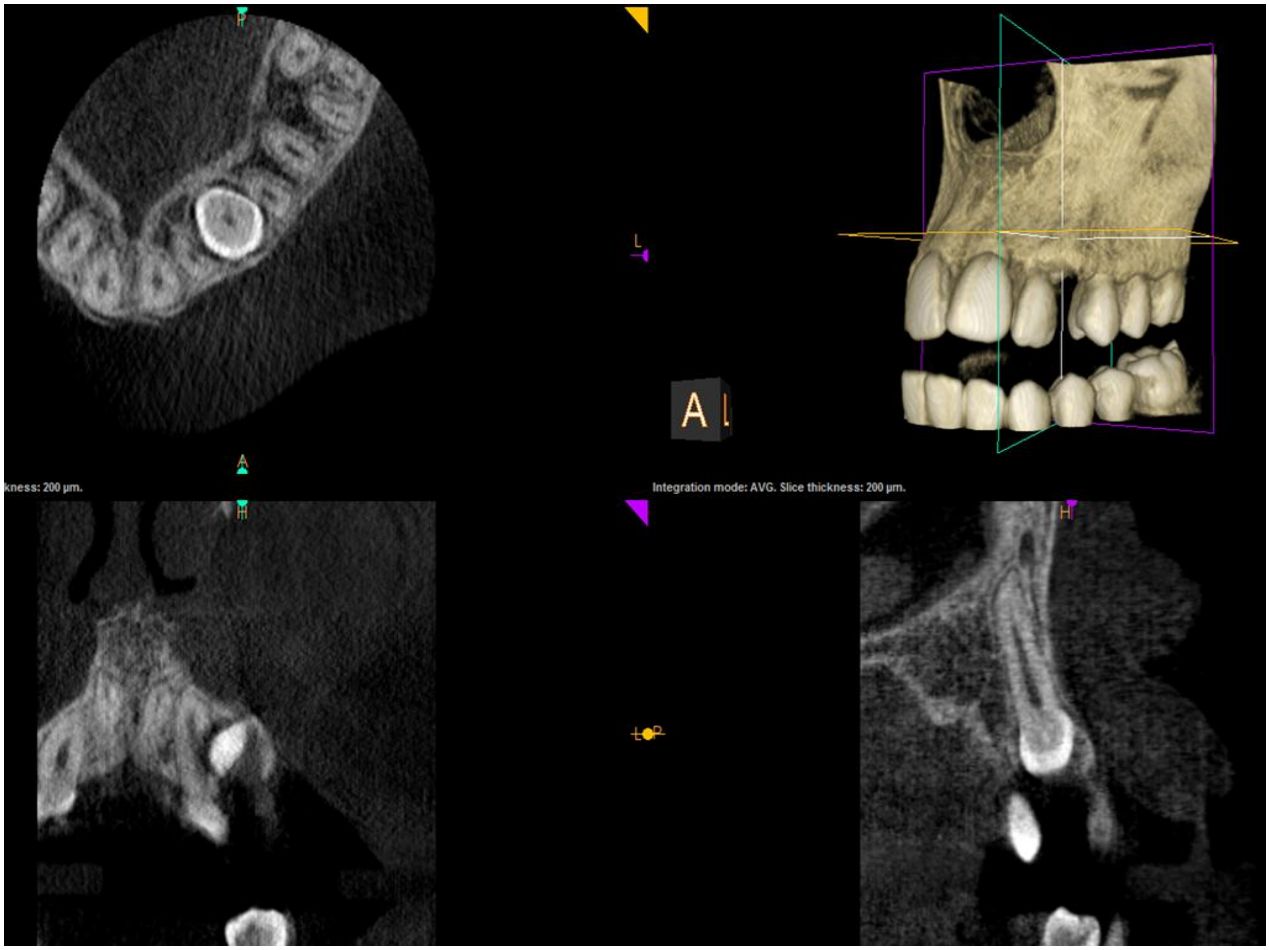

Figure 43: Example of a screenshot of MPR reconstruction from case 9.

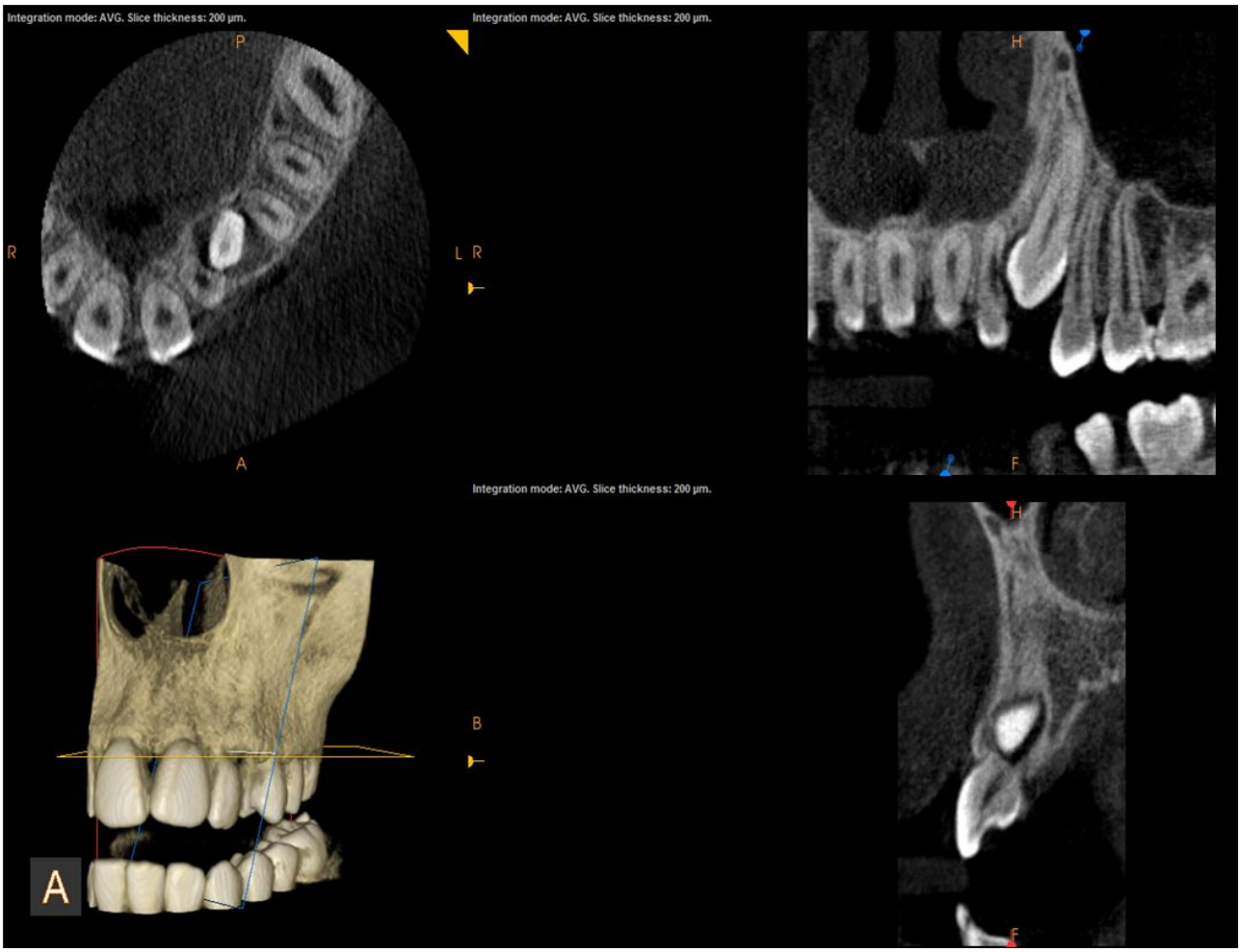

Figure 44: Example of a screenshot of curved reconstruction from case 9.

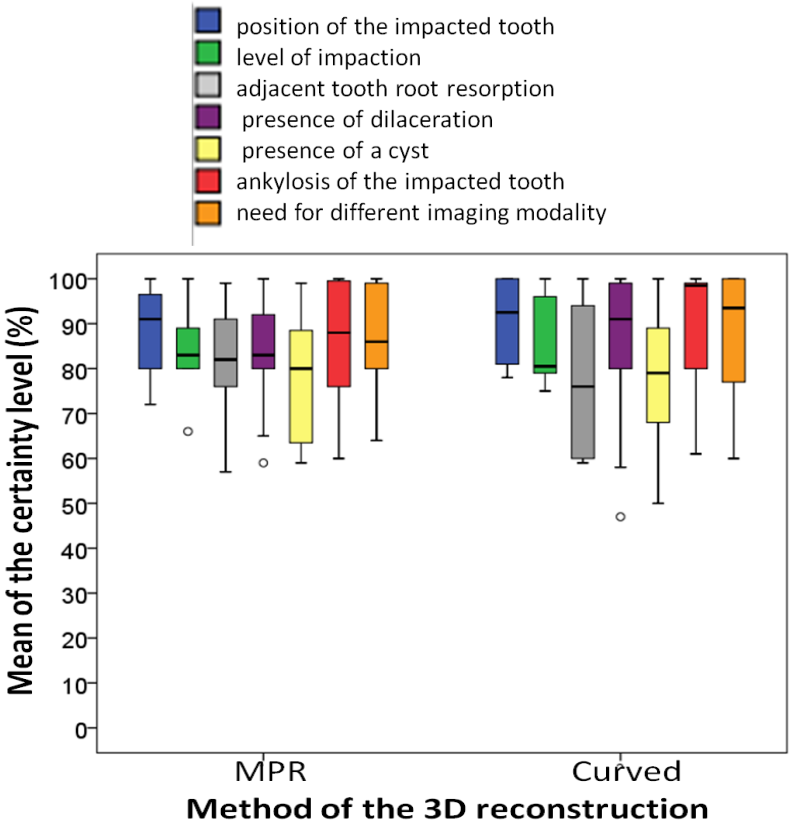

Figure 45: Level of certainty in case 9.

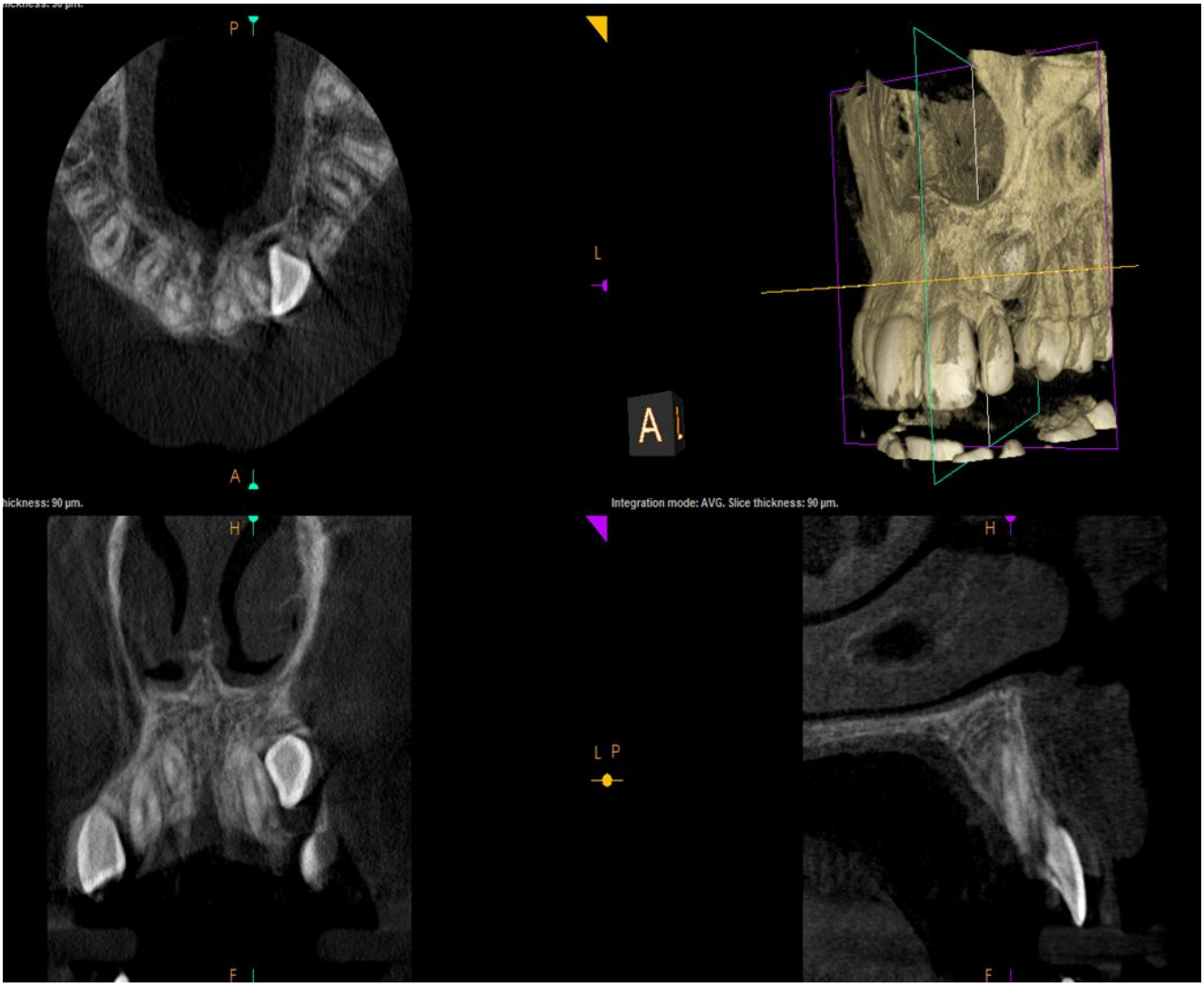

Figure 46: Example of a screenshot of MPR reconstruction from case 10.

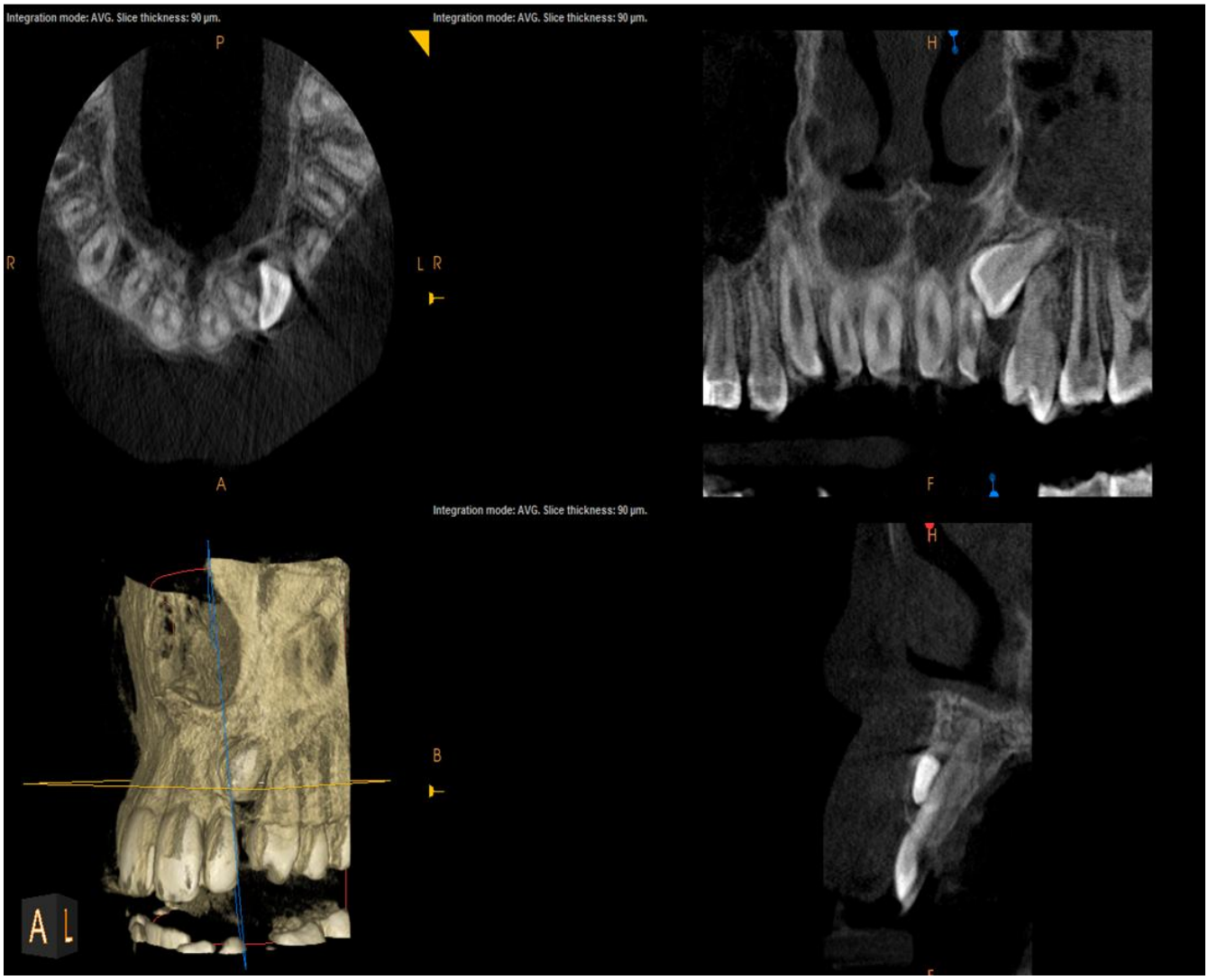

Figure 47: Example of a screenshot of curved reconstruction from case 10.

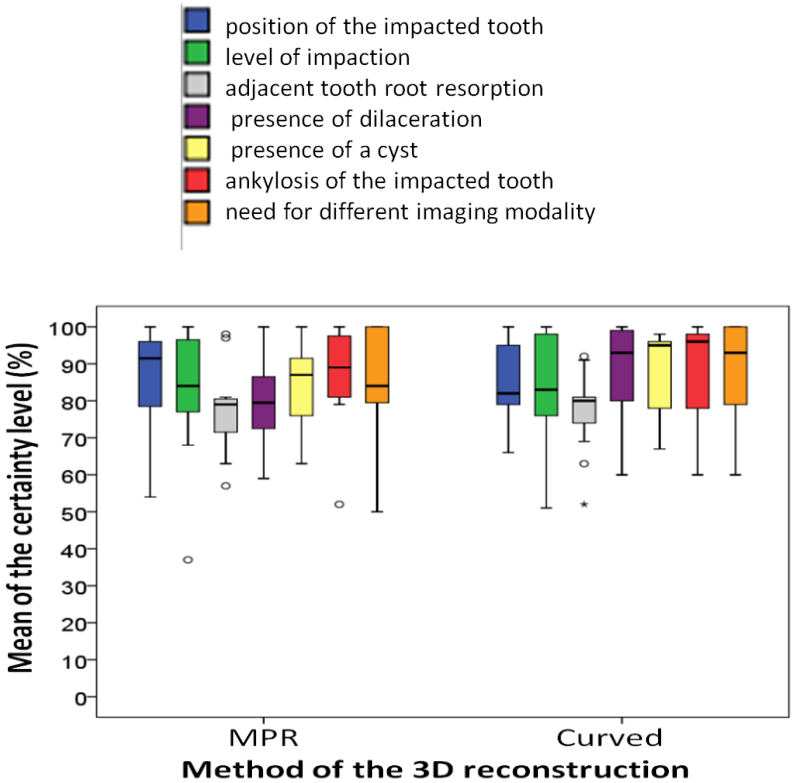

Figure 48: Level of certainty in case 10.

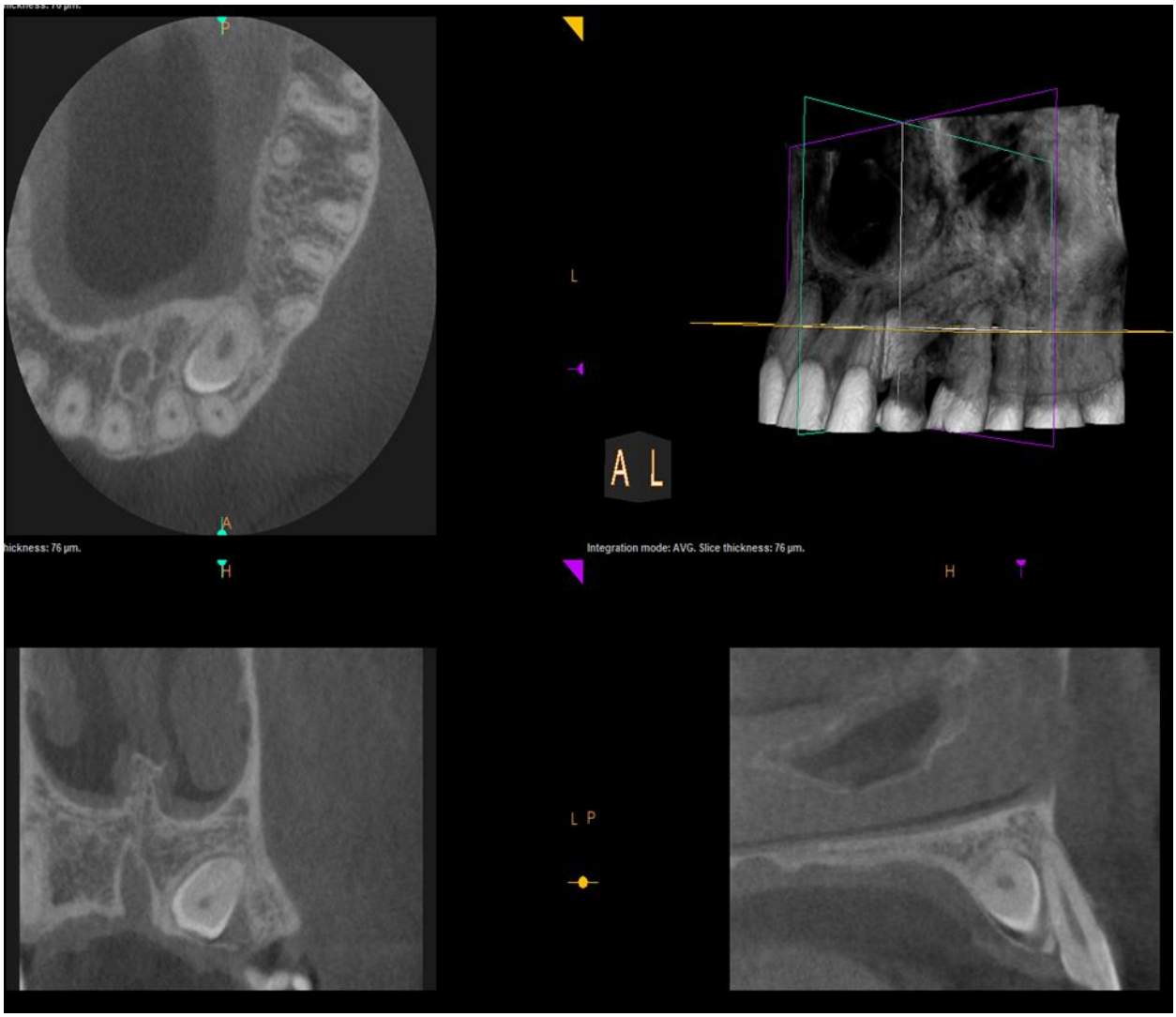

Figure 49: Example of a screenshot of MPR reconstruction from case 11.

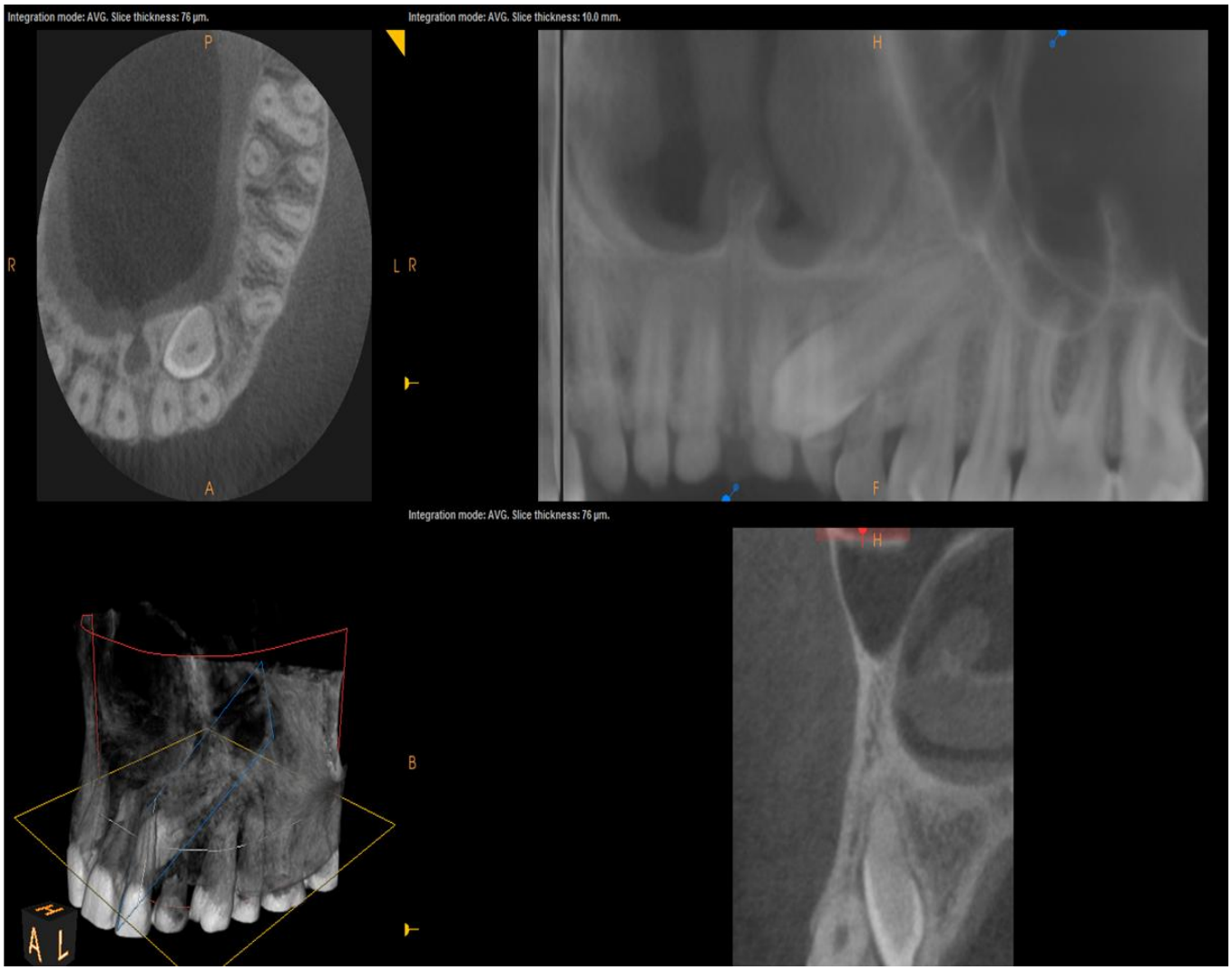

Figure 50: Example of a screenshot of curved reconstruction from case 11.

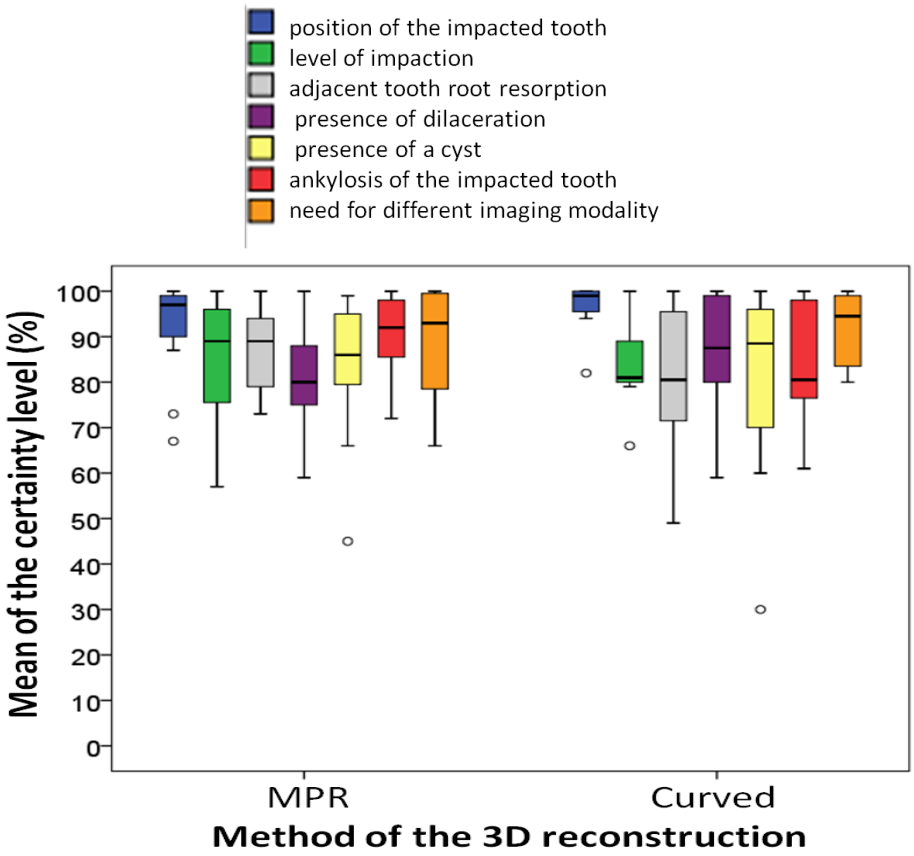

Figure 51: Level of certainty in case 11.

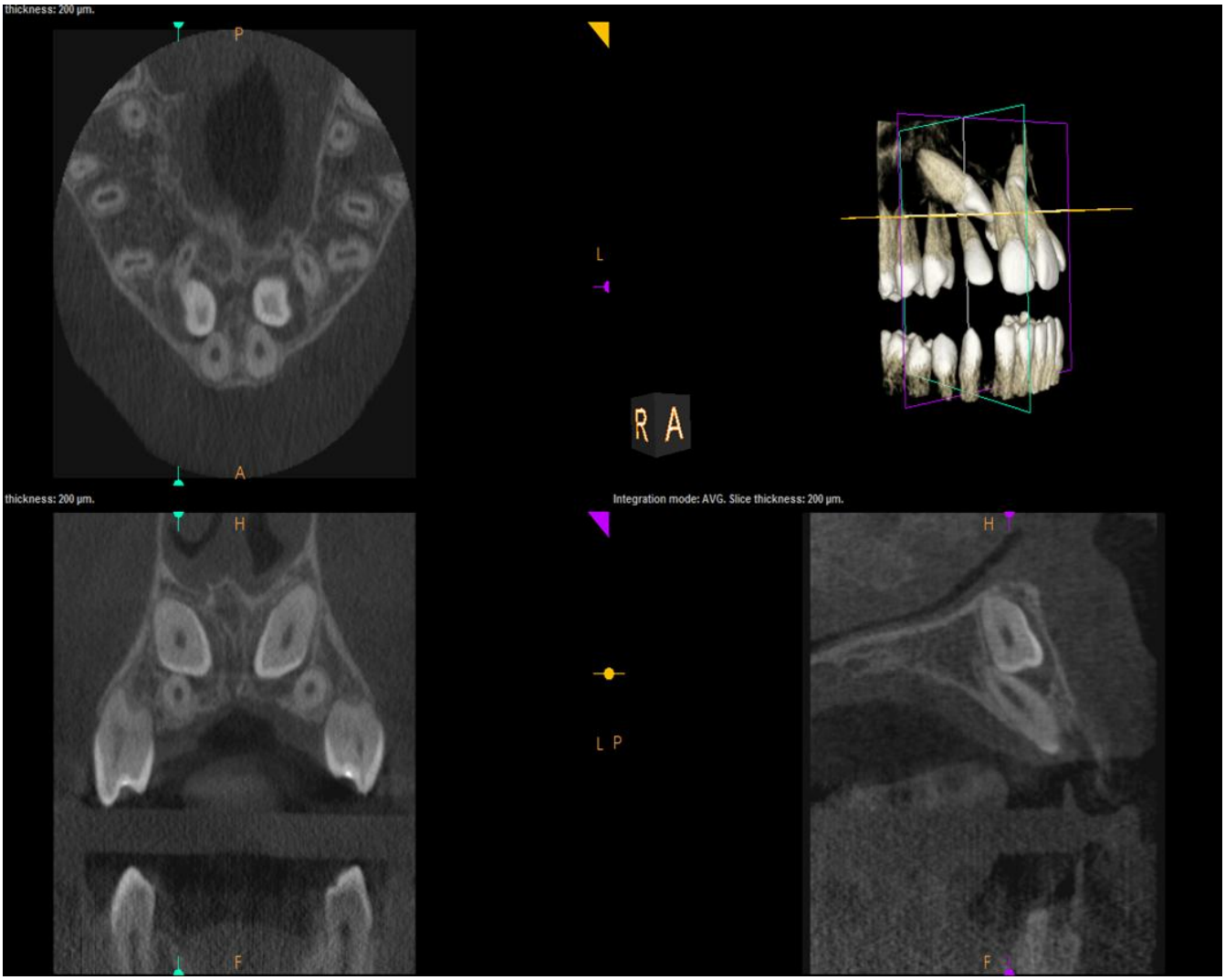

Figure 52: Example of a screenshot of MPR reconstruction from case 12.

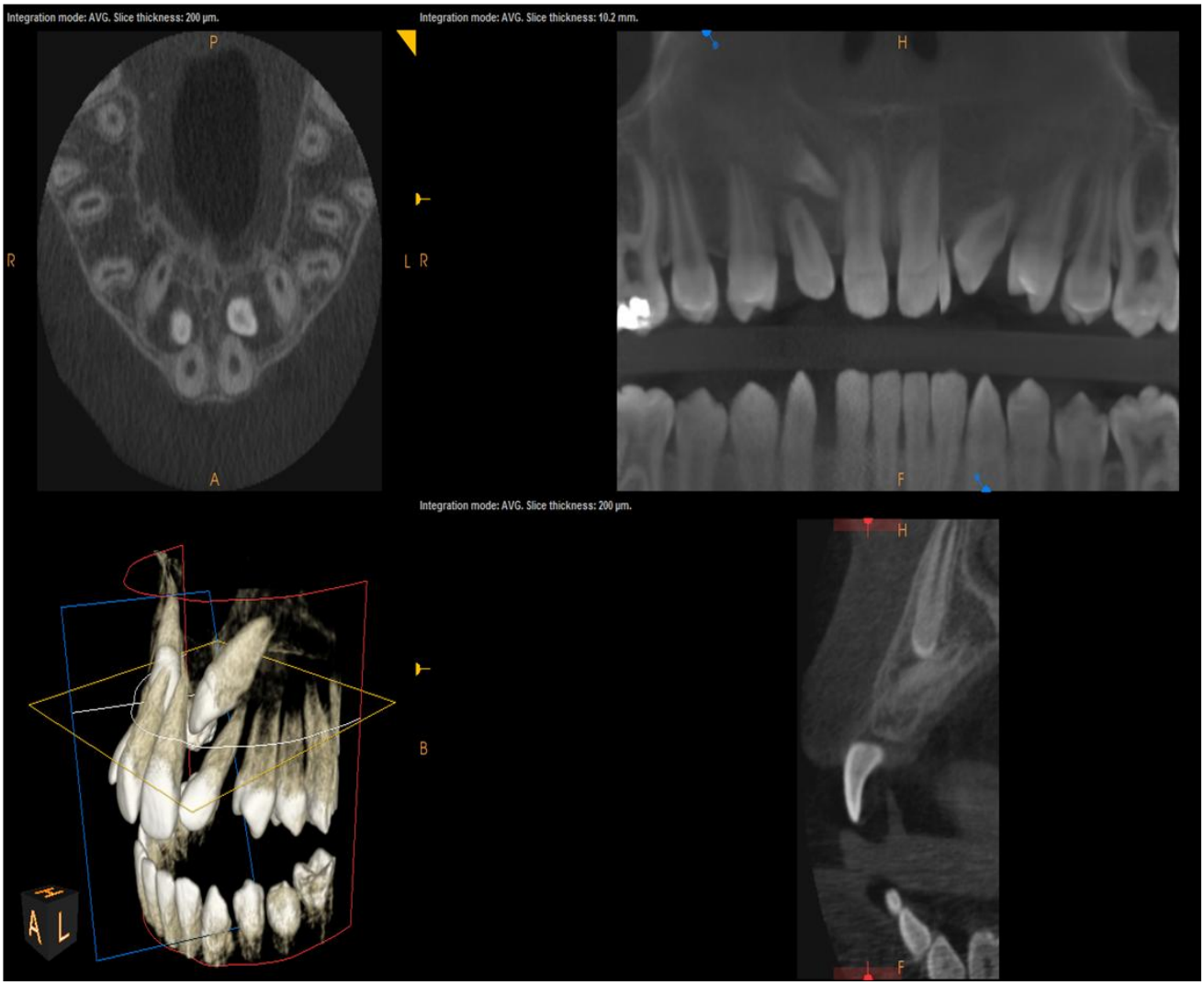

Figure 53: Example of a screenshot of curved reconstruction from case 12.

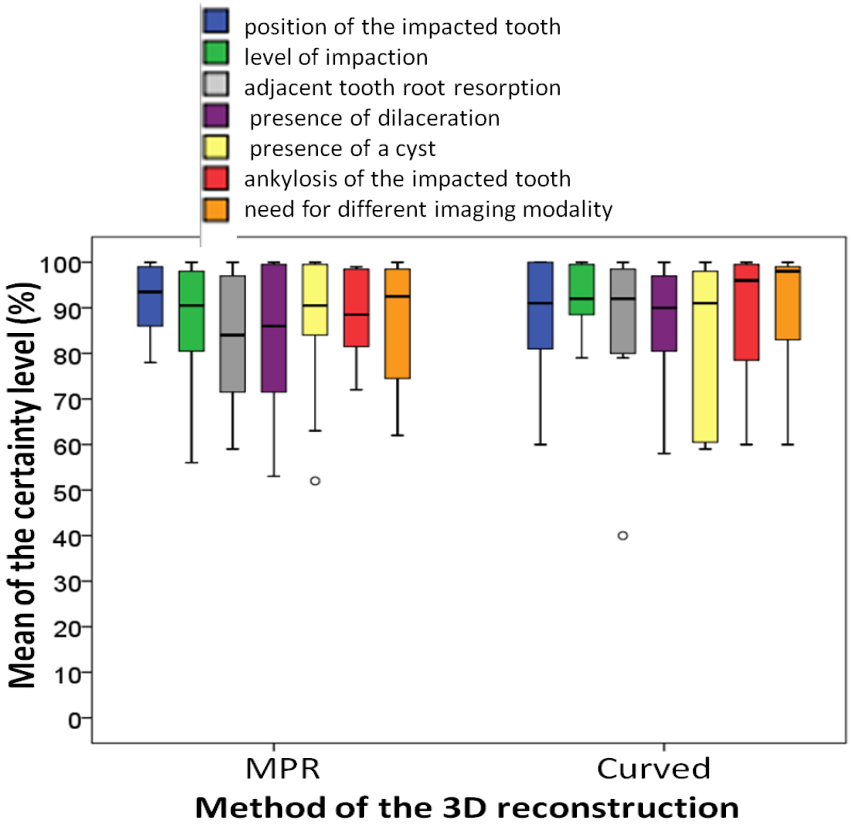

Figure 54: Level of certainty in case 12.

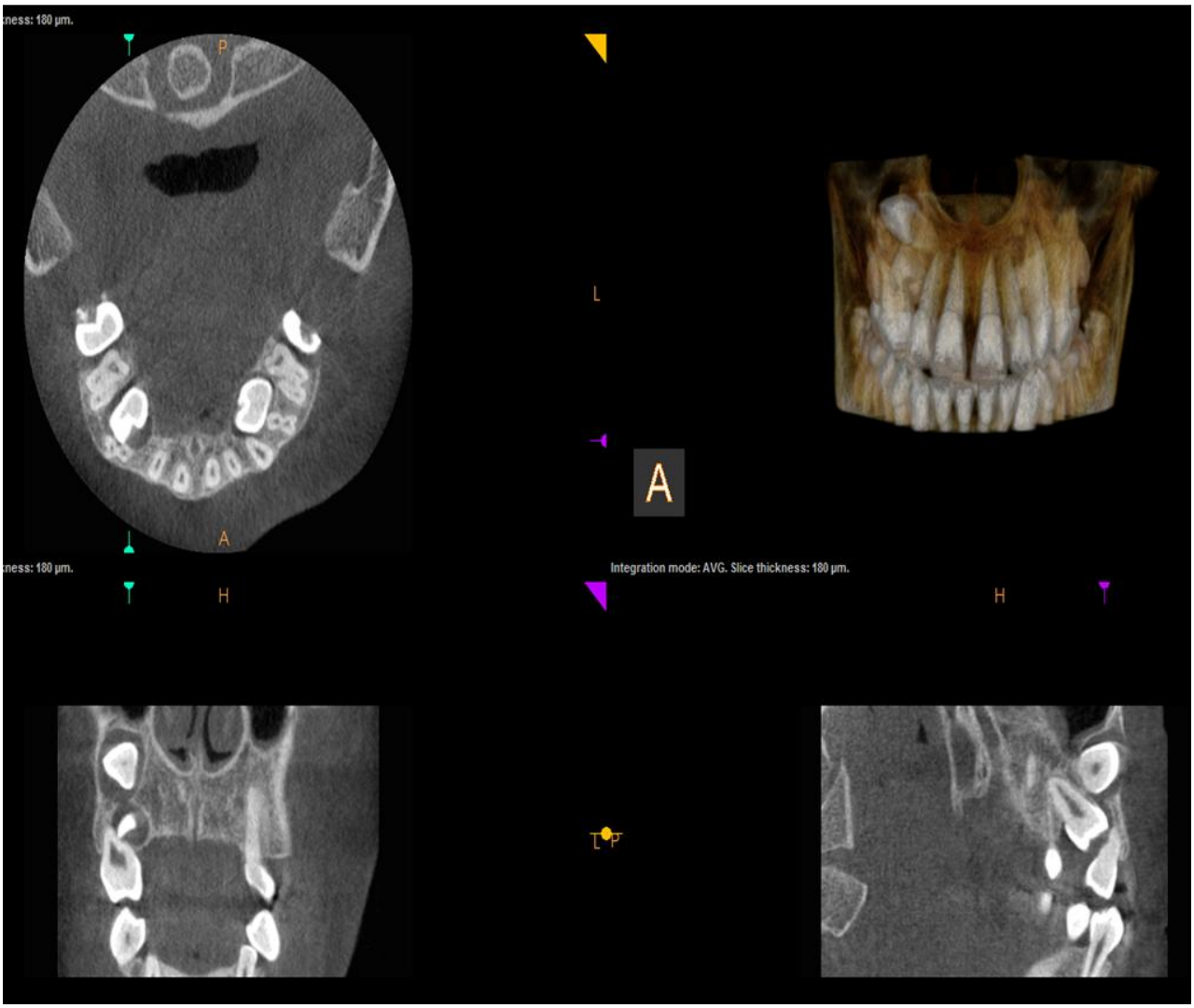

Figure 55: Example of a screenshot of MPR reconstruction from case 13.

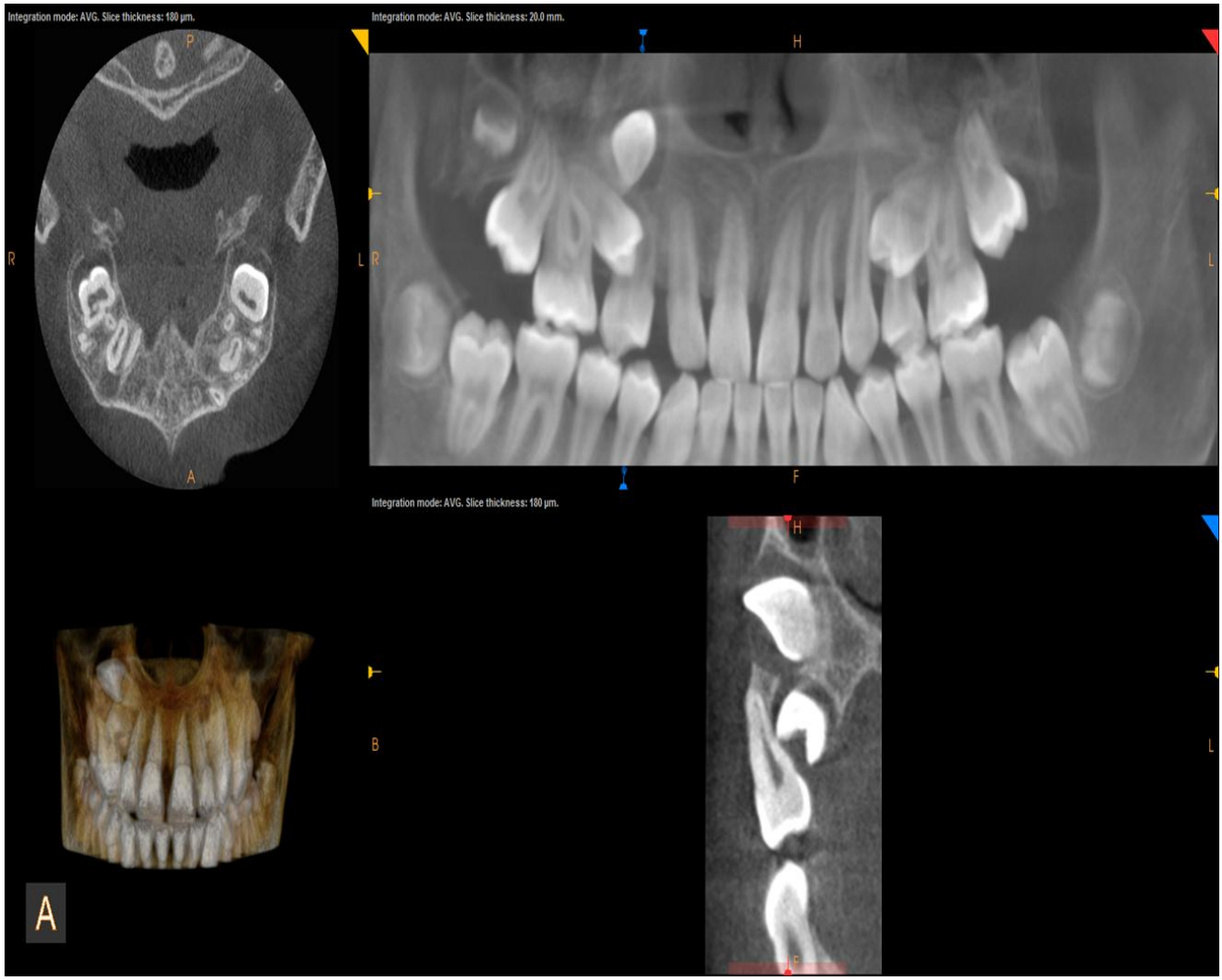

Figure 56: Example of a screenshot of curved reconstruction from case 13.

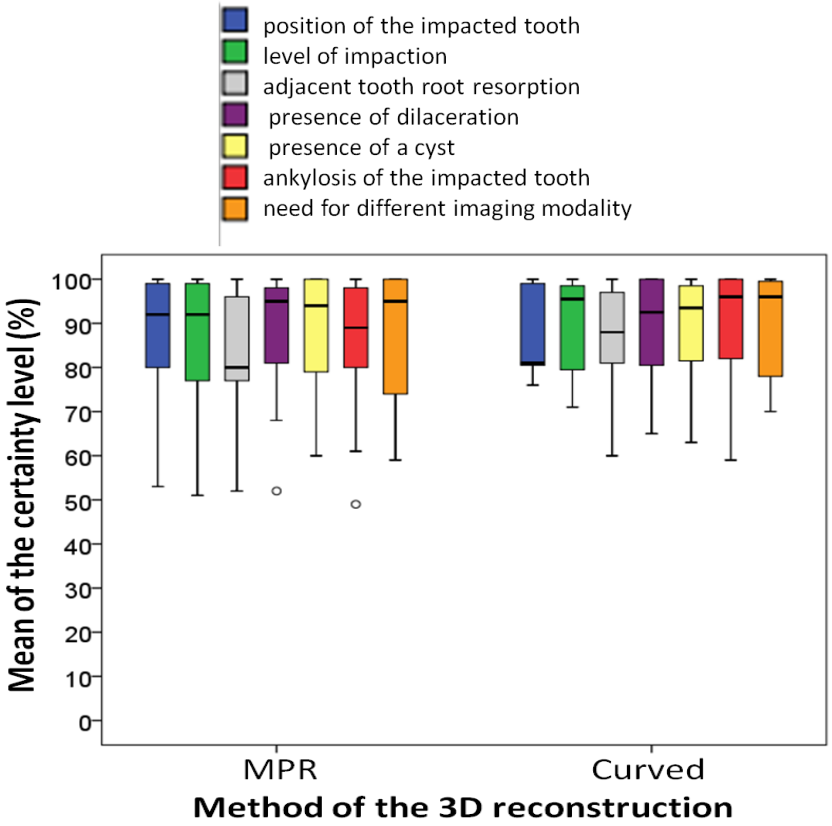

Figure 57: Level of certainty in case 13.

Figure 58: Example of a screenshot of MPR reconstruction from case 14.

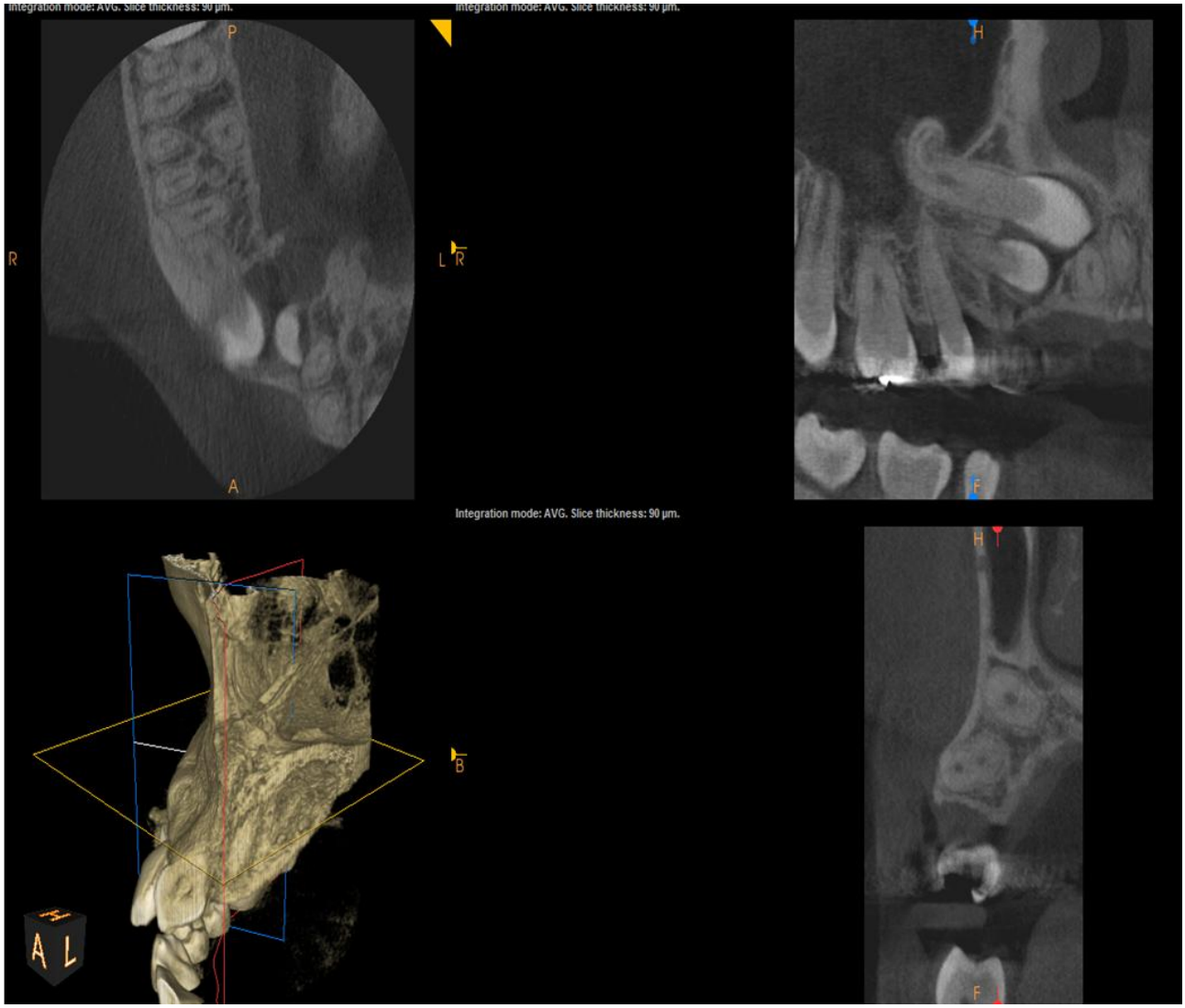

Figure 59: Example of a screenshot of curved reconstruction from case 14.

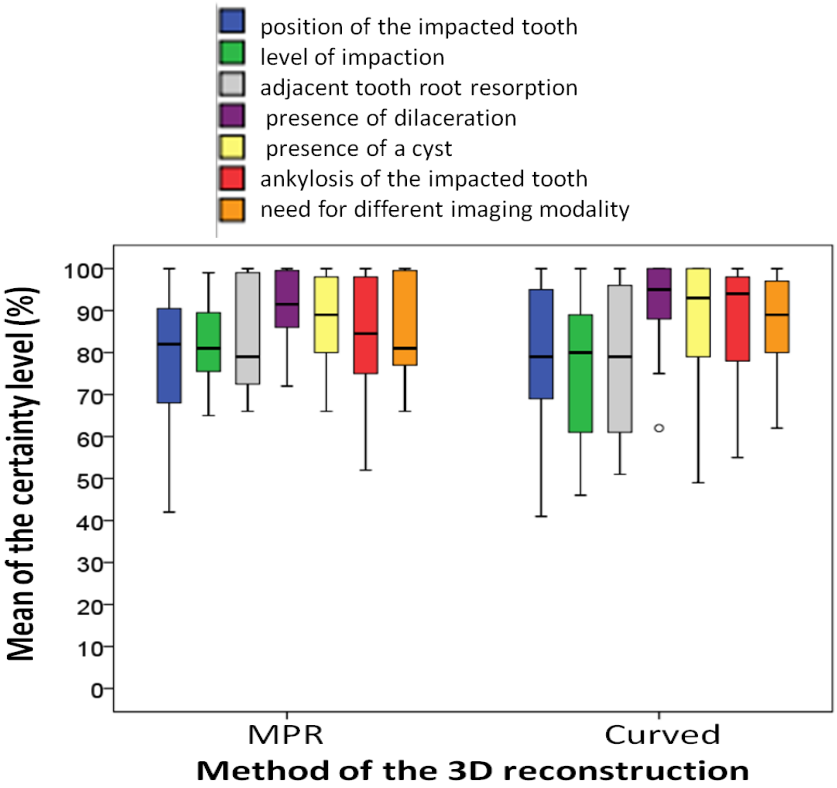

Figure 60: Level of certainty in case 14.

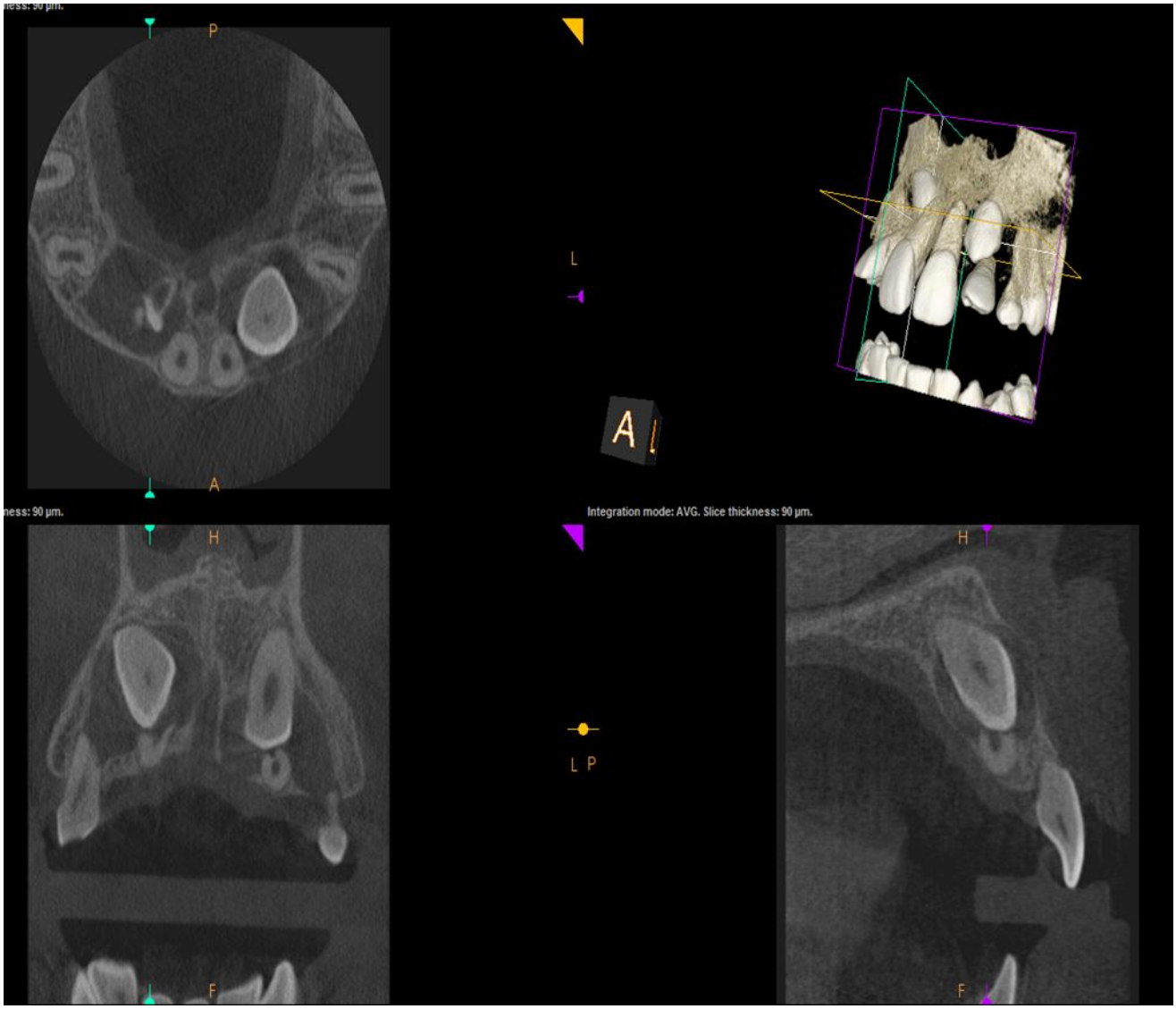

Figure 61: Example of a screenshot of MPR reconstruction from case 15.

Figure 62: Example of a screenshot of curved reconstruction from case 15.

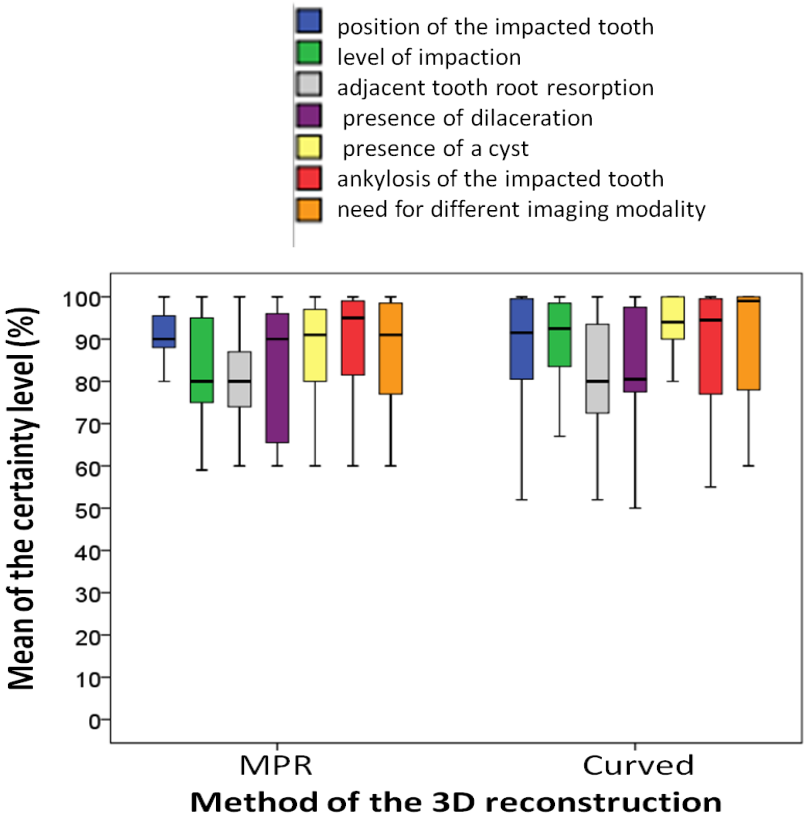

Figure 63: Level of certainty in case 15.

Chapter 8: Discussion

The CBCT technology became available to clinical dentistry 20 years ago mainly for pre-implant planning and has since been applied by general dentists and dental specialists to evaluate other cases and conditions. However, although it is widely available and relatively easy to use, large number of practitioners lacks the appropriate knowledge about the risks and benefits to the patients.

At the start of this project, an attempt was made to compare age, sex and number of impacted teeth cases treated by the UBC orthodontics department regardless the use of CBCT. However, the EPR at UBC's Faculty of Dentistry lacked the option to specify the category of the cases. This limitation hindered our ability to obtain the number of impacted teeth cases seen by the Orthodontics Department. The number of CBCT cases taken by the Orthodontic Department that is reported in this study was obtained from the Radiology Department logbook that revealed the number and the parameters for each CBCT cases taken by all the dental departments in UBC's Faculty of Dentistry. A better categorization software option of the treated cases is needed in the future to facilitate the research for similar studies.

Our study shows that the most frequent reason to prescribe CBCT in UBC's Orthodontics Department was to obtain extra information in order to diagnose difficult cases of impacted teeth. These cases show the presence or suspected presence of resorption on the adjacent teeth roots [34, 40]. In addition to the resorption, suspected root dilacerations or bone defects around the impacted teeth would direct the practitioners toward obtaining a CBCT. This is in agreement with the results found by the Hodges *et al* that the only cases benefited from the use of CBCT are the cases with unerupted teeth, severe root resorption, or severe skeletal discrepancies [19].

Although Christell *et al* concluded that there is no benefit in taking CBCT of most of the impacted canine cases, in their study they found one of the cases - which has a resorption of the lateral incisor seen only on CBCT - indeed benefited from the CBCT [41]. This supports our approach that the CBCT should be prescribed for cases with suspected resorption of the adjacent teeth that could change the treatment plan but not for all the impacted teeth.

In the study by Alqerban *et al*, they used CBCT with a FOV size 10 x 14 routinely for the impacted teeth cases in addition to the conventional orthodontics records (panoramic radiographs, lateral cephalograms, and study models). Their reason to take such a large FOV is that they were obtaining a panoramic and lateral cephalograms again from the 3D volume, plus obtaining a digital study models. They concluded that there is no difference in the treatment planning of the cases when they compared the conventional radiography with the CBCT. However, they stated that CBCT increase the orthodontics confidence levels in localizing the impacted teeth and detecting any resorption on the adjacent teeth [42]. We agree with their study that in most of the impacted canine cases there is no indication to obtain a CBCT image. Using CBCT as a routine record in the impacted cases should be discontinued because it only increases the radiation dose to the patient without significant benefit. However, we disagree with the generalization of their conclusion that the CBCT and the conventional radiography show no difference in the treatment planning. Case selection - based on the clinical recommendation and conventional radiography - is the key element to decide which case will benefit from the use of CBCT radiography.

Schubert *et al* study aimed to predict the treatment time needed to align the palatally impacted canines. They found that the prediction of the time needed for the canine tip to reach full alignment achieved at a certainty level of greater than 70 % compared to 50 % for the

panoramic radiograph [21]. Although this study found a high certainty level to predict the treatment time, it should not be the only reason to obtain a CBCT image for impacted canine case. It is known that the impacted canine cases take a very long time to complete treatment and that the time needed depends on several factors including the patient cooperation and the bone metabolism. The last two factors cannot be predicted by the CBCT.

In our study, we found that most of the CBCT cases prescribed by UBC's Orthodontics Department used a small FOV. The reason behind this is to decrease the radiation dose to the patient since we already obtained the other information needed for the orthodontics diagnosis by the clinical examination and by the conventional radiographs (panoramic radiograph and lateral cephalogram). The UBC policy is to follow the "Image Gently" guidelines and the "ALARA" principles [43, 44].

Patel *et al* described the internal root resorption as a "progressive destruction of intraradicular dentin and dentinal tubules along the middle and apical thirds of the canal walls as a result of clastic activities". They concluded that the CBCT improved the ability of the dentists to diagnose internal root resorption. They also stated that the condition is treated with root canal treatment [45]. In our study, we found one case that has an internal root resorption in the impacted canine and that was not evident in the conventional radiograph. If the tooth is in a difficult position to expose then align and it has a large internal resorption, then extracting the tooth might be the best possible option in this scenario [30].

In a preparation to implement objective 3, we needed to decide if the participants will be shown the whole volume or screenshots. A trial run was conducted with one of the orthodontists to calculate the time needed for training on how to use the CBCT software using the two reconstruction methods and the time needed to go through the whole volume of one case

reconstruction. The trial revealed that in order to allow the each participant to use the whole volume, a relatively long time is needed to train the participant in the CBCT software use. Even after they had mastered the use of the software, they will need up to one hour to study the whole volume of each case using one reconstruction method only. This will mean an impractically long time is needed for each participant. If we decide to conduct the study this way, that will limit the number of cases reviewed and severely limit the number of participants, who would volunteer, if any. In addition to this, we will have variation between participants based in their ability to use the software. These reasons will mean that we will be setting the study up for failure even before we began. For these reasons, a decision was made to take representative screenshots for each reconstruction method. Thus, we will have a standard baseline as the starting point and will eliminate the limitation of the software learning process and the limitation of the time needed to conduct the study.

This study revealed that the number of the female participants is less than their male colleagues and that they have fewer years of experience. This is a reflection of the late entry of females into the specialty of orthodontics. Currently, the number of females in orthodontic specialty programs approximates to parity.

Our results show that the detection of the adjacent teeth resorption was more diverse. This could be explained by the lack of training among the participants to detect minimal degrees of resorption in the CBCT images. However, the lesser the degree of resorption, the less effect it has in the treatment plan and prognosis of the affected tooth. Prior studies showed that once the impacted tooth has been moved away from the adjacent teeth, the resorption of the latter stops [40].

Our results also show a low level of agreement when the quantification of amount of resorption was calculated. This could be due to the lack of agreed-upon category in the literature that categorizes that amount of resorption in the 3D images. In the 2D images, the resorption is categorized based on the amount of vertical loss of the tooth structure or the depth of the resorption in the dental layers [35, 40]. On the other hand, when an impacted tooth causes a resorption in one dimension but not the other dimension, there is difficulty in characterizing it. For example, if the impacted tooth caused a resorption in the buccal side of the apical one third of the root, but we still have the lingual side of the root that will obscure the buccal resorption on the conventional radiograph. If the crown of an impacted tooth engages the middle of the root of an adjacent tooth, it can resorb it to such an extent it looks as if it has 'taken a bite out' from the middle of the root of that adjacent tooth (**Figure 64**). The parts of the root above and below the 'bite' are not affected. Once again this would be obscured if it occurred in transaxial plane (buccolingual plane). These examples are difficult to quantify added to that we used screenshots instead of the whole CBCT volume. This limits the ability of participants to detect the full area of resorption. This is a limitation in our study that needs to be addressed by future studies.

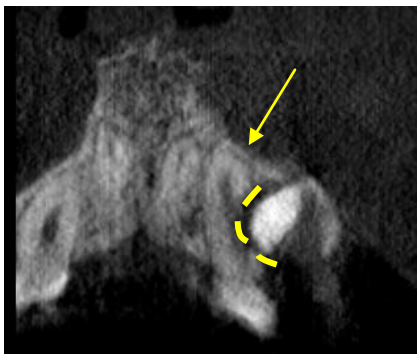

Figure 64: A CBCT image showing resorption in the middle of the root of the lateral due to the pressure from the impacted canine whereas the apex of the root is intact (yellow arrow).

Jawad *et al* in their article recognized this problem and they have a suggested guideline in the way to report the root resorption when using the CBCT [46]. See **Figure 65.**

The presence of dilaceration on the impacted tooth had a low level of agreement which could be attributed to the difficulty in detecting the dilacerations in the MPR since the plane cut could be in an angle that could prevent the viewer from the detecting the dilacerations. The difficulty in detecting the dilacerations in the curved could be explained by lack of training in using the CBCT curved reconstruction method in around half of the participants.

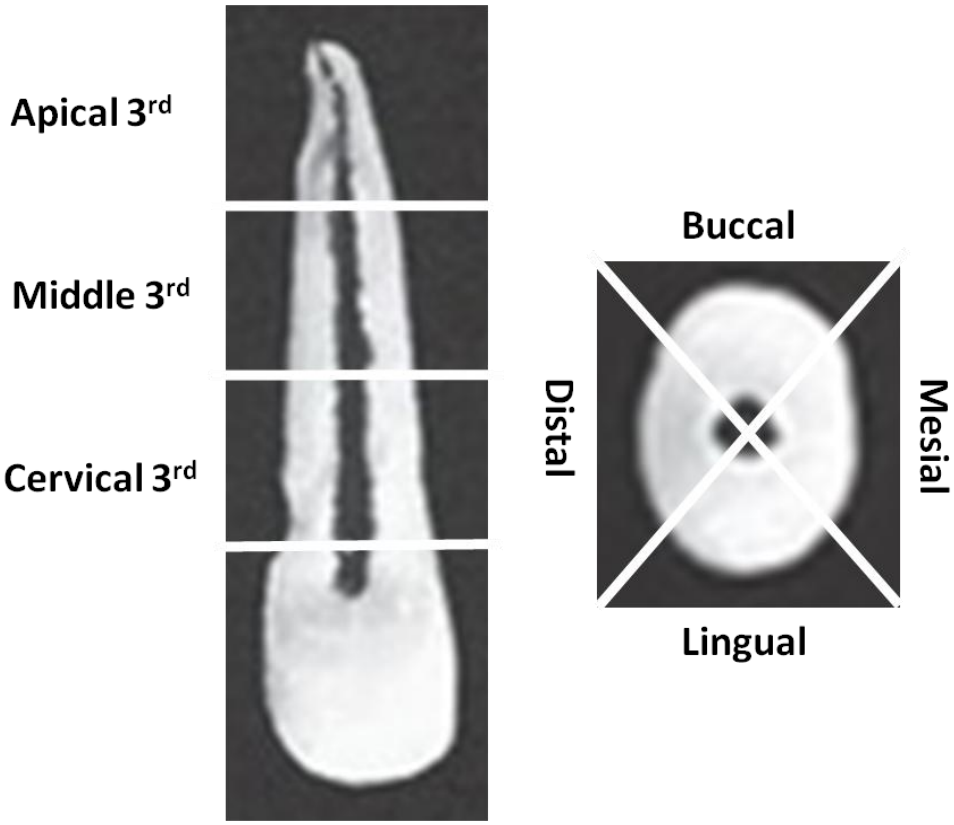

Figure 65: Suggested scale to measure root resorption in the 3D CBCT images.

Although the level of agreement of ankylosis of the impacted tooth is high, further examination of the survey answers shows that most of the answers were “I do not know” and the participants did not want to choose any answer. Verbal discussion with the participants in this regard revealed that - unless clearly visible in the CBCT image or the conventional x-rays - most

of the participants depend of the clinical reaction of the tooth toward orthodontic movement to diagnose the ankylosis. The literature shows that dentists who use the CBCT scans more frequently in practice are more confident with their decisions [19].

Regarding the analysis of the suggested treatment plan for each set, due to the heterogeneity of the results, the answers were categorized into four different categories (extraction of the impacted tooth, orthodontic exposure and alignment, monitoring, and lack of enough data to suggest a treatment plan) and a number was assigned for each category. After that, the level of agreement between the suggested plans was reported for each case.

The level of certainty of the answers for each case was different than those the other cases. In general, we could not derive a conclusion from the level of certainty charts. It seems that the results are specific for each case. Training is recommended for the orthodontists to improve their ability to read the CBCT datasets and boost their level of certainty about their answers.

As a final message to clinicians, before prescribing CBCT, the doctors should ensure that they prescribe an appropriate FOV and image resolution that will give them the information they need with less radiation to the patient. In order to minimize the number of retakes due to inadequate special resolution, perhaps it would be best to use the best special resolution with the smallest FOV [17]. Unfortunately, taking CBCTs with the smallest FOV requires the greatest precision in patient positioning. Although this was not a problem in this study, it can for CBCT numbers in the some dental offices. This is particularly important in orthodontics because the majority of the patients are teenagers and their bodies are still growing, which makes them more sensitive to radiation [9, 47].

Chapter 9: Limitations of The Study

- **Retrospective**: but this is not unexpected particularly with regard to a new technology used in a hitherto manner that would have not been considered because of the prohibitive radiation doses of the pre-existing medical CT and the poorer images of other cross-sectional modalities such as the now-obsolete complex motion tomography.
- **Limited sample**: but for a good reason (appropriate clinical indications).
- **Difficulty in reviewing the full CBCT dataset whole volume**: it was difficult for the reviewers to review the whole dataset in a practicable manner. It is important to note here that this study is not aiming to compare 2D conventional radiography with CBCT but rather it is comparing two different methods of reconstructions of CBCT using representational sets of CBCT radiographs.
- **Lack of standard method to categorize the amount of root resorption in 3D images.**

Chapter 10: Conclusion

- The number of CBCTs prescribed by the Graduate Orthodontic Program at UBC's Faculty of Dentistry is low. The FOVs selected are as small as possible due to the fact that the program policy follows the "Image Gently" guide lines and the ALARA principles.
- The vast majority of the patients' ages are between 11-30 years which is young so the effects of radiation exposure will be more than adults.
- Most of the prescribed CBCT images in Graduate Orthodontic Program at UBC's Faculty of Dentistry are to diagnose impacted teeth, especially impacted maxillary canines.
- The prescription of CBCT could be useful in specific cases only. Such cases include visible or suspected root resorption on the adjacent tooth, possible ankylosis of an impacted tooth, possible presence of a dilaceration, unclear position of the tooth in relation to adjacent structures, and to determine the extent of bone defects.
- The level of agreement between the two methods is above 70% except for the level of impaction and the adjacent tooth resorption and both could be attributed to the lack of proper training among the participants.
- So far, orthodontists are more comfortable with the MPR rather than the more panoramic-like curved reconstruction.

Bibliography

1. Ruprecht, A., *Oral and maxillofacial radiology: then and now.* The Journal of the American Dental Association, 2008. **139**: p. 5s-6s.

2. Paatero, Y.V., *A New Tomographical Method For Radiographing Curved Outer Surfaces.* Acta Radiologica, 1949. **32**(2-3): p. 177-184.

3. Scarfe, W.C. and A. G.Farman, *What is Cone-Beam CT and How Does it Work?* Dental Clinics of North America, 2008. **52**(4): p. 707 - 730.

4. White, S.C. and M.J. Pharoah, *The Evolution and Application of Dental Maxillofacial Imaging Modalities.* Dental Clinics of North America, 2008. **52**(4): p. 689-705.

5. MacDonald, D., *Cone-beam computed tomography and the dentist.* Journal of Investigative and Clinical Dentistry, 2017. **8**(1): p. e12178.

6. Haney, E., et al., *Comparative analysis of traditional radiographs and cone-beam computed tomography volumetric images in the diagnosis and treatment planning of maxillary impacted canines.* American Journal of Orthodontics and Dentofacial Orthopedics, 2010. **137**(5): p. 590-597.

7. Mah, J. and D. Hatcher, *Three-dimensional craniofacial imaging,.* American Journal of Orthodontics and Dentofacial Orthopedics, 2004. **126**(3): p. 308-309.

8. Eslami, E., et al., *Cone-beam computed tomography vs conventional radiography in visualization of maxillary impacted-canine localization: A systematic review of comparative studies.* American Journal of Orthodontics and Dentofacial Orthopedics, 2017. **151**(2): p. 248-258.

9. MacDonald, D., *Oral and Maxillofacial Radiology: A Diagnostic Approach,.* Second ed. 2019: John Wiley and Sons, Inc. (In press).

10. MacDonald, D., *Oral and Maxillofacial Radiology: A Diagnostic Approach*, 2011, Wiley-Blackwell: UK.

11. Proffit, W.R., et al., *Contemporary Orthodontics* Sixth edition. ed. 2018, Philadelphia, PA: Elsevier.

12. Pauwels, R., et al., *Technical aspects of dental CBCT: state of the art.* Dentomaxillofacial Radiology, 2015. **44**(1): p. 20140224.

13. Pauwels, R., et al., *CBCT-based bone quality assessment: are Hounsfield units applicable?* Dentomaxillofacial Radiology, 2015. **44**(1): p. 20140238.

14. Barrett, J.F. and N. Keat, *Artifacts in CT: Recognition and Avoidance.* Radiographics, 2004. **24**(6): p. 1679-1691.

15. Ludlow, J.B., et al., *Effective dose of dental CBCT—a meta analysis of published data and additional data for nine CBCT units.* Dentomaxillofacial Radiology, 2015. **44**(1): p. 40197.

16. Brüllmann, D. and R.K.W. Schulze, *Spatial resolution in CBCT machines for dental/maxillofacial applications—what do we know today?* Dentomaxillofacial Radiology, 2015. **44**(1): p. 20140204.

17. Friedland, B. and D.A. Miles, *Liabilities and Risks of Using Cone Beam Computed Tomography.* Dental Clinics of North America, 2014. **58**(3): p. 671-685.

18. Michele, C., et al., *Two-Dimensional and Three-Dimensional Cephalometry Using Cone Beam Computed Tomography Scans.* Journal of Craniofacial Surgery, 2015. **26**(4): p. e311-e315.

19. J.Hodges, R., K. A.Atchison, and S. C.White, *Impact of cone-beam computed tomography on orthodontic diagnosis and treatment planning.* American Journal of Orthodontics and Dentofacial Orthopedics, 2012. **143**(5): p. 665-674.

20. White, S.C., et al., *The Image Gently in Dentistry campaign: promotion of responsible use of maxillofacial radiology in dentistry for children.* Oral Surgery, Oral Medicine, Oral Pathology and Oral Radiology,, 2014. **118**(3): p. 257 -261.

21. Schubert, M., P. Proff, and C. Kirschneck, *Improved eruption path quantification and treatment time prognosis in alignment of impacted maxillary canines using CBCT imaging.* European Journal of Orthodontics, 2018. **40**(6): p. 597-607.

22. Schulze, R.K.W., D. Berndt, and B. D'Hoedt, *On cone-beam computed tomography artifacts induced by titanium implants.* Clinical Oral Implants Research, 2010. **21**(1): p. 100-107.

23. Korpics, M., et al., *Observer Evaluation of a Metal Artifact Reduction Algorithm Applied to Head and Neck Cone Beam Computed Tomographic Images.* International Journal of Radiation Oncology, Biology and Physics, 2016. **96**(4).

24. Bhatt, M., *Prescriptive pattern and clinical decision making in complicated endodontic cases using cone-beam computed tomography.*, in *Faculty of Dentistry* 2017, University of British Columbia.

25. Held, D., *Analysis of 3D Cone-Beam CT Image Reconstruction Performance on a FPGA*, in *Computer Science*2016, The University of Western Ontario.

26. Bjerklin, K. and L. Bondemark, *Management of Ectopic Maxillary Canines.* The Angle Orthodontist, 2008. **78**(5): p. 852-859.

27. Botticelli, S., et al., *Two- versus three-dimensional imaging in subjects with unerupted maxillary canines.* European Journal of Orthodontics, 2011. **33**(4): p. 344-349.

28. Wriedt, S., et al., *Impacted upper canines: examination and treatment proposal based on 3D versus 2D diagnosis.* Journal of Orofacial Orthopedics / Fortschritte der Kieferorthopädie, 2012. **73**(1): p. 28-40.

29. Lai, C.S., et al., *Localization of impacted maxillary canines and root resorption of neighbouring teeth: a study assessing the diagnostic value of panoramic radiographs in two groups of observers.* European Journal of Orthodontics, 2013. **36**(4): p. 450-456.

30. Bishara, S.E. and D. Ortho, *Impacted maxillary canines: A review.* American Journal of Orthodontics and Dentofacial Orthopedics, 1992. **101**(2): p. 159-171.

31. Bertl, M.H., et al., *Association between maxillary lateral incisors' root volume and palatally displaced canines: An instrumental variables approach to the guidance theory.* The Angle Orthodontist, 2018. **88**(6): p. 719-725.

32. Naoumova, J., G.E. Alfaro, and S. Peck, *Space conditions, palatal vault height, and tooth size in patients with and without palatally displaced canines: A prospective cohort study.* The Angle Orthodontist, 2018. **88**(6): p. 726-732.

33. Ericson, S. and J. Kurol, *Radiographic examination of ectopically erupting maxillary canines.* American Journal of Orthodontics and Dentofacial Orthopedics, 1987. **91**(6): p. 483-492.

34. Ericson, S. and J. Kurol, *Resorption of Incisors After Ectopic Eruption of Maxillary Canines: A CT Study.* The Angle Orthodontist, 2000. **70**(6): p. 415-423.

35. Ericson, S. and J. Kurol, *Incisor Root Resorptions Due to Ectopic Maxillary Canines Imaged by Computerized Tomography: A Comparative Study in Extracted Teeth.* The Angle Orthodontist, 2000. **70**(4): p. 276-283.

36. Preda, L., et al., *The use of spiral computed tomography in the localization of impacted maxillary canines.* Dentomaxillofacial Radiology, 1997. **26**(4): p. 236-241.

37. G.Krennmalr, F.X.Lenglinger, and M.Traxler, *Imaging of unerupted and displaced teeth by cross-sectional CT scans.* International Journal of Oral and Maxillofacial Surgery, 1995. **24**(6): p. 413-416.

38. San Martín, D.E., et al., *The KPG index--a novel 3D classification system for maxillary canine impactions.* Texas Dental Journal, 2012. **129**(3).

39. Ericson, S. and J. Kurol, *Early treatment of palatally erupting maxillary canines by extraction of the primary canines.* European Journal of Orthodontics, 1988. **10**(1): p. 283-295.

40. Becker, A. and S. Chaushu, *Long-term follow-up of severely resorbed maxillary incisors after resolution of an etiologically associated impacted canine.* American Journal of Orthodontics and Dentofacial Orthopedics, 2005. **127**(6): p. 650-654.

41. Christell, H., et al., *The impact of Cone Beam CT on financial costs and orthodontists' treatment decisions in the management of maxillary canines with eruption disturbance.* European Journal of Orthodontics, 2017. **40**(1): p. 65-73.

42. Alqerban, A., et al., *Orthodontic treatment planning for impacted maxillary canines using conventional records versus 3D CBCT.* European Journal of Orthodontics, 2014. **36**(6): p. 698-707.

43. *Image Gently During Dental Procedures*; Available from: https://www.imagegently.org/Procedures/Dental. Last Access: July 23, 2019.

44. Berkhout, W.E., *The ALARA-principle. Backgrounds and enforcement in dental practices.* Nederlands Tijdschrift Tandheelkunde., 2015. **122**(5): p. 263-270.

45. Shanon Patel, et al., *Internal Root Resorption: A Review.* Journal of Endodontics, 2010. **36**(7): p. 1107-1121.

46. Jawad, Z., et al., *A review of cone beam computed tomography for the diagnosis of root resorption associated with impacted canines, introducing an innovative root resorption scale.* Oral Surgery, Oral Medicine, Oral Pathology and Oral Radiology, 2016. **122**(6): p. 765-771.

47. (FDA), U.S.f.a.d.a. *Dose Matters: FDA's Guidance on Children's X-rays*. 2018 January 9, 2018]; Available from: https://www.fda.gov/consumers/consumer-updates/dose-matters-fdas-guidance-childrens-x-rays. Last access: July 21, 2019.

Appendix A

Faculty of Dentistry
The University of British Columbia
www.dentistry.ubc.ca

CONSENT FORM

Title of Study: Assessment of the different reconstructions of cone-beam computed tomographic (CBCT) dataset in the evaluation of impacted teeth in patient s attending a graduate orthodontic program clinic.

Short title: Assessment of CBCT dataset reconstructions in the evaluation of impacted teeth

Principal Investigator: Dr. David MacDonald
(BDS, BSc(Hons.),LLB(Hons.),MSc, DDS(Edin.), DDRRCR, FDSRCPS, FRCD(C).)
UBC, Department of Oral Biological and Medical Sciences

Co-Investigators: Dr. Edwin Yen *(DMD, PhD FRCDC)*
UBC, Department of Oral Health Sciences

Dr. Jolanta Aleksejūnienė *(DDS, MSc, PhD)*
UBC, Department of Oral Health Sciences

Dr. Sharifa Alebrahim *(BDS, MSc).*
UBC, Orthodontic graduate student

When we say "; "we" mean the doctors and other staff.

1. THE INVITATION

You are invited to participate in a study being conducted by the UBC Faculty of Dentistry researchers.

2. YOUR PARTICIPATION IS VOLUNTARY

Your participation is entirely voluntary, so it is up to you to decide whether or not to take part in this study. Before you decide, it is important for you to understand what the research involves.

This consent form will tell you about the study, why the research is being done, what will happen to you during the study and the possible benefits, risks and discomforts.

If you choose not to participate, you do not have to provide any reason for your decision not to participate.

Please take time to read the following information carefully.

3. WHO IS CONDUCTING THE STUDY?

The Faculty of Dentistry, University of British Columbia is conducting the study. There are no conflicts of interests.

4. BACKGROUND

Impacted teeth identified in orthodontic patients have hitherto been only examinable by the clinical examination and by conventional radiography.

5. WHAT IS THE PURPOSE OF THE STUDY?

The purpose of the study is to determine which reconstruction of a cone-beam computed tomographic data set is most effective in the analysis of an impacted tooth.

6. WHO CAN PARTICIPATE IN THE STUDY?

Orthodontists teaching in the UBC graduate orthodontic clinic.

7. WHAT DOES THE STUDY INVOLVE?

This study will take place during the normal orthodontic clinic hours. The information about your evaluations of the CBCT dataset will be used anonymously to evaluate the effectiveness of the reconstructions. The information will also be used to prepare research presentations.

In this study, you will be presented with a reconstruction of a CBCT dataset made on the CBCT unit housed in the faculty of Dentistry at UBC. You will be shown how to navigate the dataset. You will review the dataset to determine your response to a printed survey The total amount of time you will spend is two sessions of approximately 30 minutes per session. The time gap between the two sessions will at least a week.

You **may** be contacted by Dr. Sharifa Alebrahim for follow-up and to answer any questions.

8. WHAT ARE THE POSSIBLE HARMS AND SIDE EFFECTS OF PARTICIPATING?

There are no risks related to this study.

9. WHAT HAPPENS IF I DECIDE TO WITHDRAW MY CONSENT TO PARTICIPATE?

You may withdraw from this study at any time without giving reasons. If you choose to enter the study and then decide to withdraw at a later time, you have the right to request the withdrawal of your information collected during the study. This request will be respected to the extent possible. Please note, however, that there may be exceptions where the data will not be able to be withdrawn for example where the data is no longer identifiable (meaning it cannot be linked in any way back to your identity) or where the data has been merged with other data. If you would like to request the withdrawal of your data, please let Dr. Sharifa Alebrahim know.

10. WHAT HAPPENS IF SOMETHING GOES WRONG?

By signing this form, you do not give up any of your legal rights and you do not release the study doctor, participating institutions, or anyone else from their legal and professional duties.

11. AFTER THE STUDY IS FINISHED

Study results are available upon request.

12. WILL I GET PAID FOR MY PARTICIPATION?

There will be no reimbursement for study related expenses and you will not be paid for your participation.

13. WILL MY TAKING PART IN THIS STUDY BE KEPT CONFIDENTIAL?

Your confidentiality will be respected. However, research records identifying you may be inspected in the presence of the Investigator or by the representative from the Clinical Ethics Board for the purpose of monitoring the research. No information or records that disclose your identity will be published

You will be assigned a unique study number as a participant in this study. This number will not include any personal information that could identify you (e.g., it will not include your Personal Health Number, SIN, or your initials, etc.). Only this number will be used on any research-related information collected about you during the course of this study, so that your identity will be kept confidential. Information that contains your identity will remain only with the Principal Investigator and/or designate. The list that matches your name to the unique study number that is used on your research-related information will not be removed or

released without your consent unless required by law. Your rights to privacy are legally protected by federal and provincial laws that require safeguards to ensure that your privacy is respected.

14. WHO DO I CONTACT IF I HAVE QUESTIONS ABOUT THE STUDY DURING MY PARTICIPATION?

If you have any questions or desire further information about this study before or during participation, you can contact Dr. Sharifa Alebrahim

Your confidentiality will be respected. No information that discloses your identity will be released or published without your specific consent to the disclosure. However, research records identifying you may be inspected in the presence of the Investigator or his or her designate by representatives of the UBC Research Ethics Board for the purpose of monitoring the research.

WHO DO I CONTACT IF I HAVE ANY QUESTIONS OR CONCERNS ABOUT MY RIGHTS AS A PARTICIPANT DURING THE STUDY?

If you have any concerns about your rights as a research participant and/or your experiences while participating in this study, contact the Research Participant Complaint Line in the University of British Columbia Office of Research Ethics by e-mail at

Please reference the study number (H18-01660) when calling so the Complaint Line staff can better assist you.

15. PARTICIPANT CONSENT TO PARTICIPATE

My signature on this consent form means:

- I have read and understood the information in the consent form.
- I have had enough time to think about the information provided.
- I have been able to ask for advice if needed.
- I have been able to ask questions and have had satisfactory responses to my questions.
- I understand that all of the information collected will be kept confidential and that the results will only be used for scientific purposes.
- I understand that my participation in this study is voluntary.
- I understand that I am completely free at any time to refuse to participate or to withdraw from this study at any time.
- I understand that I am not waiving any of my legal rights as a result of signing this consent form.
- I understand that there is no guarantee that this study will provide any benefits to me.

The participant and the investigator are satisfied that the information contained in this consent form was explained to participant to the extent that he/she is able to understand it, that all questions have been answered, and that the participant assents to participating in the research.

I will receive a signed copy of this consent form for my own records.

I consent to participate in this study

_____	_____	_____
Participant's Signature	Printed name	Date

_____	_____	_____	_____
Signature of Person Obtaining Consent	Printed name	Study Role	Date

Appendix B

Dear participant,

Thank you for your help in filling up surveys with questions pertaining to a series of cases with CBCT images.

Please read this page before starting.

1. There will be 34 cases each with a set of 5 CBCT images.
2. This study will be conducted in 2 sessions separated by at least one week.
3. At each session, you will need to answer questions after viewing the images for 18 cases.
4. Please go through each case (5 images) first and then answer the corresponding questions.
5. Please return the answer sheets at the end of each session.

Thank you again for your participation.

Appendix C

Set No.: _____

Thank you for giving us your time to help in filling this survey.

Please answer the following questions based on your best knowledge. Please pick one answer only.

e.g. Position of the tooth:
1. Labial/Buccal.
2. Palatal/lingual.
3. Middle of the alveolar ridge.

Certainty of the answer:

0% 100%

I. Are you orthodontic specialist or orthodontic resident?
1. Specialist. (Years of practice _____).
2. Resident (year _____).

II. Are you familiar with 3D imaging?
1. Worked with Orthogonal CBCT (years of Practice _____).
2. Worked with Curved CBCT (years of practice_____).
3. Worked with both Curved and Orthogonal (years of practice_____).
4. This is my first time.

III. Position of the tooth:
1. Labial/Buccal.
2. Palatal/lingual.
3. Middle of the alveolar ridge
4. I cannot make a judgment.

Certainty of the answer:

0% 100%

IV. Vertical level of impaction in relation to the adjacent lateral incisor:
1. At the level of the CEJ.
2. Between the CEJ and the coronal ½ of the root.
3. Between the middle of the root and the apex.
4. Above the apex.
5. I cannot make a judgment.

Certainty of the answer:

0% 100%

1

Set No.: _____

V. Amount of adjacent tooth root resorption:

1. No resorption
2. 1/5 or less.
3. 1/3 or less.
4. Between 1/3 and ½.
5. More than ½.
6. I cannot make a judgment.

Certainty of the answer:

0% 100%

VI. Presence of dilacerations of the impacted tooth.

1. Yes
2. No.
3. I do not know.

Certainty of the answer:

0% 100%

VII. Presence of a cyst around the impacted tooth.

1. Yes
2. No.
3. I do not know.

Certainty of the answer:

0% 100%

VIII. The impacted tooth is ankylosed:

1. Yes
2. No.
3. I do not know.

Certainty of the answer:

0% 100%

Set No.: _____

IX. Need different imaging modality.

1. Yes. (Please specify _____).
2. No.
3. I cannot make a judgment.

Certainty of the answer:

0% 100%

X. If the tooth is not ankylosed, What would be your first choice of recommended treatment (please provide orthodontic mechanical details if applicable):

1. _____.
2. _____.
3. _____.
4. _____.
5. _____.
6. _____.
7. _____.

Appendix D

Faculty of Dentistry
The University of British Columbia
www.dentistry.ubc.ca

Letter of Initial Contact
To prospective reviewers of cone-beam computed tomographic datasets made for the investigation of impacted maxillary canines

Dear,

We are contacting you to see whether you would be willing to participate in a study during your visit to the UBC Dental Clinic as teaching faculty in the graduate orthodontic program. In order to participate you must sign a consent form. The study involves you reviewing on two separate occasions separated by a time gap of at least a week a series of datasets. You will be instructed on how to scroll through the dataset prior to performance of the review. You will enter your assessment of each feature as it appears on the survey sheet. Your identity will not be linked in any way to the study.

Please be assured that you are under no obligation to give your permission to participate in the study. If you wish, you may decline without giving a reason.

If you would like more information about the study Dr. Sharifa Alebrahim, a graduate student in orthodontics, will be happy to provide with a more detailed explanation.

Yours truly,

Dr. David MacDonald
Dr. Sharifa Alebrahim,
Dr. Edwin Yen
Dr. Jolanta Aleksejūnienė

Assessment of CBCT dataset reconstructions in the evaluation of impacted teeth
Contact form version 1 June, 6, 2018
Study Number: H18-01660: